



LIJEČNIČKI VJESNIK

GLASILO HRVATSKOGA LIJEČNIČKOG ZBORA
THE JOURNAL OF THE CROATIAN MEDICAL ASSOCIATION
Utemeljen 1877. Founded 1877

Sensing the World: Otorhinolaryngology & Ophthalmology



April 27 - 30, 2022

17th International Biomedical
Croatian Student Summit
University of Zagreb **School of Medicine**

LIJEČNIČKI VJESNIK


GLASILO HRVATSKOGA LIJEČNIČKOG ZBORA

Utemeljen 1877.



<https://lijecnicki-vjesnik.hlz.hr/>

<https://hrcak.srce.hr/lijecnicki-vjesnik>



UDK 61(061.231)=862=20

Liječnički vjesnik citiraju: Scopus, EMBASE/Excerpta Medica, EBSCO, Hrcak

Liječnički vjesnik tiskano izdanje ISSN 0024-3477

Liječnički vjesnik online izdanje ISSN 1894-2177

Osnivač i izdavač

HRVATSKI LIJEČNIČKI ZBOR

Za izdavača

ŽELJKO KRZNARIĆ

Glavni i odgovorni urednik

BRANIMIR ANIĆ

Tajnik uredničkog odbora

Željko Ferenčić

Tajnica redakcije

Dražanka Kontek

Naklada

500 primjeraka

SAVJET

Predsjednik

Mladen Belicza

Tajnik

Miroslav Hromadko

Članovi

Nada Čikeš (Zagreb) – Hedvig Hricak (New York) – Miroslav Hromadko (Zagreb) – Mirko Jung (Zürich) – Ivica Kostović (Zagreb) – Ante Padjen (Montreal) – Marko Pećina (Zagreb) – Dinko Podrug (New York) – Miljenko Pukanić (Sydney) – Smiljan Puljić (Upper Saddle River, New Jersey) – Berislav Tomac (Hagen) – Marko Turina (Zürich)

UREDNIČKI ODBOR

Branimir Anić (Zagreb) – Anko Antabak (Zagreb) – Branka Aukst Margetić (Zagreb) – Alen Babacanli (Zagreb) – Ivan Bojanić (Zagreb) – Boris Brkljačić (Zagreb) – Venija Cerovečki (Zagreb) – Mislav Čavka (Zagreb) – Željko Ferenčić (Zagreb) – Božo Krušlin (Zagreb) – Martin Kuhar (Zagreb) – Julije Meštrović (Split) – Mislav Planinc (Zagreb) – Dražen Pulanić (Zagreb) – Duje Rako (Zagreb) – Željko Reiner (Zagreb) – Zdenko Sonicki (Zagreb) – Davor Štimac (Rijeka) – Adriana Vince (Zagreb) – Miroslav Župčić (Rijeka)

MEĐUNARODNI UREDNIČKI ODBOR

Jurgen Deckert (Würzburg, Njemačka) – Patrick Erik Eppenberger (Zürich, Švicarska) – Michael Fuchsjäger (Graz, Austrija) – Primož Gradišek (Ljubljana, Slovenija) – Andrej Grajn (Manchester, UK) – Emir Q. Haxhija (Graz, Austrija) – Tomas Jovaisa (Kaunas, Litva) – Jamin Kashwa (London, Engleska) – Živko Steven Pavletić (Bethesda, SAD) – Semir Vranic (Doha, Katar)

Opis

Liječnički vjesnik je najstariji hrvatski medicinski časopis koji neprekidno izlazi od 1877. te redovito bilježi sva važna stručna i strukovna dostignuća u hrvatskoj i svjetskoj medicini. U Liječničkom vjesniku objavljuju se uvodnici, stručni i znanstveni radovi, pregledni članci, prikazi bolesnika, lijekova i metoda, preliminarna znanstvena i stručna priopćenja, osvrti, pisma uredništvu, prikazi knjiga, referati iz literature i drugi prilozi. Svi rukopisi podvrgnuti su procesu recenzija.

Rukopisi i svi članci šalju se Uredništvu Liječničkog vjesnika, Zagreb, Šubićeva ul. 9, tel. (01) 46-93-300, e-pošta: lijecnicki-vjesnik@hlz.hr.

Članarina, pretplata i sve novčane pošiljke šalju se Hrvatskomu liječničkom zboru, Zagreb, Šubićeva ulica 9, na IBAN HR7423600001101214818, OIB 60192951611. Članarina Hrvatskoga liječničkog zbora iznosi 200 kuna; za liječnike pripravnike i obiteljska članarina iznosi 100 kuna. Pretplata za Liječnički vjesnik je 315 kuna (inozemstvo 84 eura). Radi redovitog primanja časopisa svaku promjenu adrese potrebno je javiti Uredništvu. Svaki član Hrvatskoga liječničkog zbora ima pravo besplatno objaviti članak u Liječničkom vjesniku; autori koji nisu članovi Zbora moraju platiti naknadu u iznosu od 187,50 kuna + PDV.

Tiskano u Hrvatskoj



Autorska prava: Objava: Hrvatski liječnički zbor.

Svi su članci slobodno dostupni pod uvjetima Creative Commons Attribution-NonCommercial-NoDerivates 4.0 međunarodna licenca. Ova licenca dopušta drugima da preuzimaju radove i podijele ih s drugima sve dok vam priznaju, ali ih ne mogu ni na koji način promijeniti ili komercijalno koristiti. <https://creativecommons.org/licenses/by-nc-nd/4.0/legalcode>

BOOK OF ABSTRACTS

SENSING THE WORLD:
OTORHINOLARYNGOLOGY
& OPHTHALMOLOGY

APRIL 27 – 30, 2022
Croatian Student Summit 17
University of Zagreb School of Medicine





**17th International Biomedical
Croatian Student Summit**

**Zagreb,
April 27-30, 2022**

EDITOR-IN-CHIEF

Robert Marčec
Mirta Peček
Emio Halilović

School of Medicine, University of Zagreb

PUBLISHER

University of Zagreb
School of Medicine
Šalata 3, Zagreb, Croatia

FOR PUBLISHER

Slavko Orešković, MD, PhD
School of Medicine, University of Zagreb

SENSING THE WORLD: OTORHINOLARYNGOLOGY & OPHTHALMOLOGY

TABLE OF CONTENTS

4	COMMITTEES	13	ABOUT THIS YEAR'S TOPIC
5	GENERAL INFORMATION	14	SCIENTIFIC PROGRAMME
6	RULES FOR SUBMISSION	32	ABSTRACTS
7	WELCOME TO CROSS 16	104	AUTHOR INDEX

Committees

ORGANISING COMMITTEE

Vinko Michael Dodig, President
Dora Cesarec, Vice President
Dino Žujić, Vice President

Petra Bašić	William Migo
Marin Boban	Vinka Potočki
Lazarela Cuparić	Paulo Rinčić
Marina Dasović	Yasho Singh
Zoya Jelovečki Đokić	Dora Softić
Ema Kazazić	Ines Trkulja
Kristijan Lipovac	Siniša Vlahović
Matija Martinić	

SCIENTIFIC PROGRAMME COMMITTEE

Emio Halilović, President
Ivana Kraljević, Poster Session Chair
Drago Marijanović, Workshop Chair

Matej Dobrošević
 Gracia Grabarić
 Robert Marčec
 Luka Mitar
 Mirta Peček
 Antonia Precali
 Eva Stanec
 Aurora Vareško

Jan Homolak, MD
 Matija Vid Prkačin, MD
 Tomislav Smoljo, MD

TASK FORCE

Morana Belović	Ivan Sedlanić
Marija Doronjga	Luka Sudarević
Nora Knez	Irena Valek
Laura Rudelj	Franka Vrtiprah
Petar Samardžić	Lea Župan
Darko Santovac	

Mirjana Bjeloš, *ex-officio member*
 Nikolina Čunović, *ex-officio member*
 Krsto Dawidowsky, *ex-officio member*
 Iva Dekaris, *ex-officio member*
 Mislav Gjurić, *ex-officio member*
 Jasmina Ivšac Pavliša, *ex-officio member*
 Sonja Jandroković, *ex-officio member*
 Jelena Juri Mandić, *ex-officio member*
 Iva Kelava, *ex-officio member*
 Andro Košec, *ex-officio member*
 Lana Kovač Bilić, *ex-officio member*
 Damir Kovačić, *ex-officio member*
 Marko Lukić, *ex-officio member*
 Ivan Rašić, *ex-officio member*
 Ivana Šimić, *ex-officio member*

PUBLIC RELATIONS TEAM

Klara Bojanović	Stella Sara Worman
Marin Cvitić	Ivica Zec
Dea Maras	Julija Žanetić
Mia Vukosav	Josip Živković

ORGANISED BY



UNIVERSITY OF ZAGREB,
SCHOOL OF MEDICINE



STUDENT COUNCIL OF SCHOOL OF
MEDICINE, UNIVERSITY OF ZAGREB



CROATIAN MEDICAL
ASSOCIATION



Škola narodnog zdravlja
„Andrija Štampar“
"ANDRIJA ŠTAMPAR"
SCHOOL OF PUBLIC HEALTH

General Information

VENUES

University of Zagreb, School of Medicine, Šalata 3
Croatian Institute for Brain Research (CIBR), Šalata 12
“Andrija Štampar” School of Public Health, Rockefeller
Street 4

GUEST ATTENDANCE POLICY

All event activities (including workshops and meal functions) are exclusively reserved for registered attendees. Non-registered guests (including children, family members, colleagues, etc.) are not allowed in any of the event areas. Badges provided at registration are required for entrance into all functions and will be strictly enforced.

REGISTRATION DESK

Registration desk will be open as follows:

Wednesday, April 27: 13:00 - 16:00

Thursday, April 28: 8:00 - 14:00

Friday, April 29: 8:00 - 14:00

Saturday, April 30: 9:00 - 14:00

Our team will gladly assist you even if the registration desk is closed so please do not hesitate to contact us via email, social media, or your contact person.

SOCIAL MEDIA

You are invited to follow CROSS 17 on the social media for updates and news, to share experiences and practices, or to simply ask for opinions.

Don't forget to use the hashtag #CROSS17 to share your experience at CROSS 17!

LIABILITY AND INSURANCE

The Summit Organising Committee and School of Medicine cannot accept liability for personal accidents or loss of or damage to private property of participants. Participants are advised to take out their own personal travel and health insurance for their trip.

CERTIFICATE OF ATTENDANCE

Certificates of attendance will be distributed via email. You will get your Certificate on the email address you entered while purchasing your ticket; it may take up to 15 days after the conclusion of the Summit for you to get your Certificate.

PUBLIC TRANSPORTATION

The main building of the School of Medicine is located very near the city centre and as such is easily accessible by public transportation. Several tram lines make a stop at Draškovićevo (4, 8, 11, 12, 14), which is the closest stop from the main building. The School of Public Health “Andrija Štampar” can also be reached by tram lines that make a stop at Gupčeva Zvijezda (8, 14), even though a more practical way to reach it may be a ten-minute walk from the main building of the School of Medicine. More information on our local public transportation network can be found at: <http://www.zet.hr/en>

POSTER ORAL PRESENTATIONS

Posters specifically chosen by the Scientific Programme Committee will be discussed during the Poster Sessions. These posters do not require printing or production of materials – as your work will be presented electronically. Posters will be available at the Poster stations at the Summit, on the CROSS 17 website during the Summit and in an online archive for one year following the Summit. Viewers will be able to easily find and browse and download the posters in PDF format when permitted by the presenter. Each poster presentation should be about 5 minutes long. During the Summit the Scientific-Programme Committee will ask questions following the evaluation of your presentation.

EVENTS

We will host a number of events you may attend while at CROSS 17. Buffet dinner and networking reception will be held at the School of Medicine in front of Čačković conference hall on Wednesday, April 27, 18:00 - 19:00. Gala dinner will be held on Friday, April 29 starting at 20:00. Before attending a social event, you must apply for the event. Application links will be sent out to participants via email.

Additional events:

NETWORKING EVENT

Wednesday, April 27, 20:00

ZAGREB SIGHTSEEING TOUR

Meeting point on Ban Jelačić square
Thursday, April 28, 9:00 - 10:30

PUB QUIZ

Thursday, April 28, 20:00

INSTITUTE FOR FORENSICS AND CRIMINOLOGY MUSEUM VISIT

Šalata Street 11
Friday, April 29, 10:00 - 11:00

CHOCOLATE MUSEUM ZAGREB VISIT

Varšavska Street 5
Friday, April 29, 11:00 - 12:00

MUSEUM OF ILLUSIONS VISIT

Ilica Street 72
Saturday, April 30, 9:00 - 10:00

ZAGREB ZOO

Maksimir Park
Saturday, April 30, 9:30 - 11:30

CROSS 17 AFTER PARTY powered by BELUPO
Club & Lounge Roko, Jarunska Street
Saturday, April 30, 21:00

Rules for Submission

GENERAL RULES

All abstracts and ePosters must be submitted in English.

The CROSS Scientific-Programme Committee will review all abstracts. Following the information regarding acceptance, scheduling information will be sent to the abstract submitter.

The Congress Book of Abstracts will include plenary lectures, satellite symposium abstracts, workshop abstracts and all accepted poster presentations. All abstracts must be submitted and presented in clear English with accurate grammar and spelling of quality suitable for publication. If you need help, please arrange for the review of your abstract by a colleague who is a native English speaker, by a university specific publications office (or a similar facility) or by a copy editor, prior to submission.

Abstracts must be original and must not be or have been published or presented at any other meeting prior to the Congress. Abstracts containing updated information or modified data to previously published or presented abstracts will not be considered or accepted for presentation.

Please note that each person may submit up to 2 abstracts as a presenting author.

Upon submission, the Abstract Submitter confirms that the abstract has been previewed and that all information is correct, accepts that the content of this abstract cannot be modified or corrected after final submission and is aware that it will be published exactly as submitted. Submission of the abstract constitutes the authors' consent to publication (e.g. Congress Abstract Book, CROSS website, Programmes, other promotion, etc.).

The Abstract Submitter warrants and represents that he/she is the sole owner or has the rights for all the information and content ("Content") provided to CROSS 17 ("Organisers"). The publication of the abstract does not infringe any third party rights including, but not limited to, intellectual property rights.

The Abstract Submitter grants the Organisers a royalty-free, perpetual, irrevocable nonexclusive license to use, reproduce, publish, translate, distribute, and display the Content. The Organisers reserve the right to remove from any publication an abstract which does not comply

with the above.

Upon submission the Abstract Submitter confirms that the contact details saved in the system are those of the corresponding author, who will be notified about the status of the abstract.


The corresponding author is responsible for informing the other authors about the status of the abstract.

ORCID® IDs

ORCID is a nonprofit organization whose mission is to solve the name ambiguity problem in scholarly communication by operating an open-access registry of persistent unique identifiers for individual researchers, and an open and transparent linking mechanism with other ID schemes and research objects such as publications, grants, and patents.



WELCOME TO CROSS 17!



APRIL 27-30, 2022
Croatian Student Summit 17
University of Zagreb School of Medicine



WELCOME TO ZAGREB...

Zagreb, the capital and the largest city of Croatia, ranks among the oldest cities in Central Europe but it is also a modern metropolis situated in the northwestern part of the country along the river Sava and beneath the Medvednica mountain. Due to its developed industries, scientific and research institutions and transport connections, Zagreb is also the cultural, scientific and economic centre of the country.

Although the history of Zagreb goes back to the Roman time, the first written reference to Zagreb dates to 1094 when it was divided into two parts: Kaptol with the Zagreb Cathedral and the larger part Gradec. Two parts were united in 1851 by the count (in Croatian “ban”) Josip Jelačić, whose statue today proudly stands on Zagreb's main square, named after the „ban“ himself.

There are many legends about Zagreb however, the most famous one is how Zagreb got its name. A thirsty knight saw a well as he was passing through this area and a local maiden named Manda was standing next to it. He pleaded: “MANDO, DUŠO, ZAGRABI!” (“Manda, sweetheart, scoop some water!”) Today, a small circular fountain called Manduševac is located at Zagreb’s main square, built above a natural spring that provided Zagreb with drinking water until the end of the 19th century.


Zagreb attracts visitors with the lively atmosphere of its streets, numerous coffee shops, restaurants and shopping. For a modern capital, Zagreb has a kind of small-town charm, with an amazing hilltop district of cobblestone streets and squares lit to this day by gas lamps. Prestigious fountains, beautiful park-woods and parks make it also one of the greenest cities in Europe. One of the most remarkable buildings in the city is Zagreb Cathedral in

Gothic style, St. Mark's Church from the 13th century with admirably colourful tiled roof and Croatian National Theatre, neo-baroque Zagreb masterpiece.

With approximately 20 theatres, 30 museums, 58 galleries and art collections (mostly located in the very centre of the city), a great zoo and almost a million inhabitants, Zagreb offers various possibilities to guests of all profiles. The best ways to explore Zagreb are walking through historical streets and observing its hidden beauties, or by using its blue trams, „the blood vessels“ of the city, which pulsate day and night making Zagreb a truly vibrant city. Whether you need some live music at a bar or a good sit-down meal, Tkalčićeva street (or just „Tkalča“ as Croats call it), should be your first port of call. There is something for everyone - from underground clubs and cafes to creperie, burger bars and high-end restaurants.

Notable Zagreb souvenirs are the tie or cravat, an accessory named after Croats who wore characteristic scarves around their necks in the Thirty Years' War in the 17th century and licitars, honey dough cookies painted with red enamel and decorated with patterns and messages.

Zagreb is also known for its Christmas market which was several times elected as the best in Europe. Streets and squares lit up and offer a unique range of tidbits at their Christmas fair. However, the fun continues through the whole year as festivals of all kinds roll in week after week: coffee and chocolate, street food, art performances, music etc.



...AND OUR SCHOOL OF MEDICINE!

School of Medicine at the University of Zagreb was established in 1917. Just 5 years ago, we celebrated our 100th anniversary, which makes our School of Medicine the oldest one in the western Balkan region of Europe. It was founded around the time the Austro-Hungarian empire began falling apart, giving rise to an autonomous State of Slovenes, Croats and Serbs. This independence enabled Croats to expand the University of Zagreb. That is when Milan Rojc proposed the establishment of a medical school to the Croatian parliament. As a result of his efforts and that of many others who came after, Zagreb School of Medicine gave rise to many great doctors. One of the most well-known among them was Andrija Štampar, an especially notable mention in times of the coronavirus pandemic since he established the Public Health service in former Yugoslavia and later created the foundations of the public health system in Croatia. He subsequently went on to head the first Health Assembly in Geneva and wrote the constitution for WHO in 1948. In this brief text, however, examples of the modern life of a medical student at our School are provided with an overview of various extracurricular activities our students engage in.

Besides the classic overwhelming workload characteristic of any medical school our students are able to take part in numerous student organisations as well as having ample research opportunities. Such extracurricular activities enable students to focus on and further explore their fields of interest early on in their medical career. There are 16 student organisations covering numerous medical fields. There are also 2 student magazines active on our campus, *Medicinar* and *Gyrus*, and both are run and published by students. *Gyrus* mostly covers subjects related to the field of neuroscience while *Medicinar* covers a wide range of topics related to both student life and new interesting research in the Medical field. Both ma-

gazines provide students with an opportunity to exercise their writing and publishing skills while providing a great platform for young researchers to publish their work.

Practical work experience is crucial for any young doctor, which is why our student organisations offer various workshops and volunteer work opportunities in hospitals. For example, the Student organisation for Surgery organises courses where students can learn basic stitching techniques. The Student organisation for Pediatrics offers opportunities for students to join and observe the work of paediatricians who are on call in hospitals. Most student organisations invite lecturers to talk about specific topics of interest that students may not have an opportunity to learn about during regular courses in Medical school. Finally, the Student Organisation for Infectology is currently collaborating with hospitals in an effort to gather volunteers to help deal with the coronavirus pandemic.

Another notable organisation to mention is the Croatian Medical Students' International Committee, usually referred to as CroMSIC. This organisation offers an impressively wide variety of activities for students to participate in. One particularly interesting project is the international exchange program which provides opportunities for work and education abroad, while also hosting foreign students who visit Zagreb. Lastly, one praiseworthy initiative that has been receiving an increased nationwide recognition is the mRAK project. mRAK works on promoting awareness about HPV virus and vaccine by organising educations in high schools along with various events that target the wider public.

All in all, the activities described above serve to depict just some of the exciting opportunities that serve to form new generations of young doctors at the School of Medicine in Zagreb.



Welcome Message

PRESIDENT OF THE CROSS 17 ORGANISING COMMITTEE



Dear Participants,

It is with great pleasure that I welcome you to the seventeenth Croatian Student Summit, held under the theme ‘Sensing the World: Otorhinolaryngology & Ophthalmology’. Croatian Student Summit, popularly called CROSS, is an international biomedical congress of students and young scientists, organised by the Student Council of the University of Zagreb School of Medicine. I would like to point out that CROSS is organised almost exclusively by students, who selflessly devote their time and effort into making this Summit possible. Therefore, CROSS represents a valuable asset to our Faculty, as well as the University of Zagreb.

More than 17 years ago this Summit was founded by our fellow colleagues with one main goal, which was to bring people together. Today, more than ever, we realise the importance of such events, as they enable us to develop new ideas, practice our communication skills and grow professionally, as well as personally. At CROSS we offer two types of participation. Passive participants have a chance to immerse themselves in the interesting lectures we have prepared and can also learn valuable new skills during our workshop sessions. On top of that, active participants have the opportunity to present their own work, thus acquiring valuable presentation skills and experience.

This year’s CROSS will cover two fields of medicine extremely popular with medical students and young doctors, otorhinolaryngology and ophthalmology. These fields have recently seen rapid development in both diagnostic and treatment procedures, therefore providing for an excellent array of innovative lectures. I believe that this year’s Summit will present otorhinolaryngology and ophthalmology in a broad manner, familiarising you with both surgical and non-surgical approaches.

Organising an event such as CROSS is certainly challenging, so I would like to extend my gratitude to everyone that made this Summit possible. A big thank you to our School of Medicine at the University of Zagreb, whose continuous support has been invaluable throughout the years. Furthermore, I would like to extend my thanks to the Croatian Medical Chamber for their official recognition of our Summit, and to Liječnički vjesnik whose cooperation brings this Book of Abstracts to a higher level. The support of this year’s sponsors and donators has been incredible so I thank them heartily. Last, but certainly not least, my greatest appreciation goes to all my fellow members of the Organising and Scientific-Programme Committees, whose dedication and hard work continues to amaze me.

I once again welcome you to our Faculty and wish you a pleasant Summit!

A handwritten signature in black ink that reads 'Vinko M. Dodig'. The signature is written in a cursive, flowing style.

Vinko Michael Dodig
President of the CROSS 17 Organising Committee

Welcome Message

PRESIDENT OF THE CROSS 17 SCIENTIFIC PROGRAMME COMMITTEE

Dear Participants,

On behalf of the Scientific Programme Committee, it's a great honour to wish you a warm welcome to the 17th Croatian Student Summit! After two pandemic years in which only one CROSS took place and which was completely online, this year's CROSS holds great meaning for us. The process of socialization began again after a two-year lockdown and we have the opportunity to sense the world again with all our senses. Sensing the world and returning to normal was our main premise as we chose the topic – Ophthalmology & Otorhinolaryngology. Of course, we don't mean this only metaphorically, by carefully choosing the lecturers, the goal of the Scientific-Programme Committee is that we all look at ENT and Ophthalmology in a different way and that we together discover a new world in these two noble branches of medicine. The development of Ophthalmology and ENT in Croatia has gained momentum, so one of our many ideas was to present the curiosities of these specializations that make Croatia among the best in Southeast Europe, and in some aspects among the best in Europe. Of course, showing novelties is often challenging for medical students so I would like to take this opportunity to thank Associate Professor Miro Kalauz, M.D., PhD, Andro Košec, M.D., PhD and the Student Section for ENT for their help in selecting the best topics and lecturers! Also, I want to thank all of our invited speakers for their good will in passing on their knowledge to us and for becoming part of this beautiful story which continues to unfold for the 17th time in a row.



Another core idea of CROSS is to give students and young colleagues the opportunity to take their first steps in the world of science and to learn from their successes and failures. This year is also a record year in terms of the number of abstracts submitted and I would like to thank everyone who recognized our Congress as an excellent opportunity to start! The Scientific-Programme Committee has raised its criteria and introduced three M.Ds into its team so that both participants and student members of the Committee benefit from their experience and continue to grow. To make the efforts of the participants see the light of day, we have prepared the very Book of Abstracts that you are holding in your hands. I would like to emphasize that the abstracts of all authors were submitted without the intervention and proofreading of the Scientific-Programme Committee. As one of the Editors-in-Chief, I am very glad that we have continued our collaboration with Liječnički vjesnik, the official journal of the Croatian Medical Association. I hereby express my sincere gratitude to The Editorial Board, Editor-in-Chief Prof. Branimir Anić, M.D., PhD, Secretary of the Editorial Office Draženka Kontek, but also to our School of Medicine for making this continuing partnership possible!

After the Plenary Sessions and Poster Sessions, I have to mention the Workshop Sessions and thank all Student Sections that responded to our invitation to enable our participants to learn or further improve in practical skills that they don't have the opportunity to perform on a daily basis. So far I have already listed many things that have been prepared for you, but none of this would have been possible without the valuable members of the Scientific-Programme Committee who have invested their free time to improve the quality of the Congress and to make this CROSS the best so far! They have been investing their energy in this Congress for months and in the spirit of the topic I would call them true enlighteners for their dedicated work.

The main values of this year's CROSS are the pursuit of the greatest possible acquisition of knowledge and excellence in the scientific work in the spirit of self-knowledge and self-enlightenment.

I wish you a very successful congress!

Emio Halilović

President of the CROSS 17 Scientific Programme Committee

Welcome Message

PRESIDENT OF THE STUDENT COUNCIL



Dear Participants,

As the president of the Student Council at the University of Zagreb, School of Medicine, I am delighted to welcome you to this year's Croatian Student Summit – CROSS 17 with the theme „Sensing the World: Otorhinolaryngology & Ophthalmology“.

Croatian Student Summit is a student congress organized annually by the Student Council of our School of Medicine. It has been established as the main student congress event of the year simultaneously making it an ongoing tradition. Throughout the years CROSS has evolved in a great manner: from a small medical students' meeting to an internationally recognized congress. We are proud that students from all over Europe, and even beyond, have been a part of this incredible journey. It is always amazing seeing these extraordinarily talented and hardworking students, as well as young physicians, all in one place. My favorite part of CROSS is the fact it gives all medical students a chance to see what the world of medicine in science looks like. All scientists have to start somewhere, and we are very proud that many have found that this is the place to do so.

I would like to take this opportunity and thank the Dean of the School of Medicine, University of Zagreb, Slavko Orešković, PhD, and the Student Council, the University of Zagreb for their nonstop support. The truth is, without them all of this wouldn't be possible and I am very grateful to be a part of this unique story.

And lastly, even though we have put the emphasis of CROSS on the educational experience, please don't forget to have fun! Our social program is loaded with opportunities to meet like-minded people and build new friendships, as well as explore the beautiful city of Zagreb.

I wish you all a successful Croatian Student Summit!



Vinka Potočki
*President of the Student council,
School of Medicine, University of Zagreb*

About This Year's Topic

SENSING THE WORLD: OTORHINOLARYNGOLOGY & OPHTHALMOLOGY

The area of the head and neck is one of the most complex and exposed parts of the beautiful machine that we call the human body. Not only do they protect the essence of our being - the brain, which was the topic of last year's CROSS, they contain extremely important structures for us to function.

From the first time we open our eyes, at 28 weeks of gestation, to the moment we close them forever, the eyes are our window to the world, although until the 12th month of life it's not the most crystal-clear picture. It can be said that the eyes are the mirror of the soul, but we have to ruin that saying and say that they are also the mirror of diseases that are not just in the domain of ophthalmologists. Often, they are in the domain of a sister specialty - otorhinolaryngology. Because of the overlapping of anatomical regions and close proximity of structures, it is clear why otorhinolaryngology and ophthalmology used to be one. Otorhinolaryngology didn't just come from the separation, but also from fusion of otology and laryngology.

An important figure for both fields, just like for the whole field of medicine, is Hippocrates. Hippocrates, even without COVID, found the importance of olfaction, in other words, smell, which made a crucial part of his physical examinations. Hippocrates was one of the firsts who described the eye bulb anatomically, and in Egypt, his definitions of strabismus were found on Ebers papyrus.

To write Hamlet and kill the character of the king, Shakespeare needed to know some medicine, otorhinolaryngology to be precise. Shakespeare was

born the same year when Eustachio described the pharyngotympanic tube or more popularly named Eustachian tube. That was the period when chronic ear inflammations with otorrhea were frequent. Due to the inflammation, tympanic membranes were often perforated and the Eustachian tube that led to the pharynx was a good path for poison which was able to reach systemic circulation in this way. Still, one canal is a great connection between otorhinolaryngology and ophthalmology - ductus nasolacrimalis, which connects the fossa lacrimalis with the nasal cavity. Alongside tears, atropine drops can also reach the greatly vascularized nasal mucosa, potentially causing systemic symptoms.

Otorhinolaryngology and ophthalmology differ from other fields in that they use special instruments and equipment during physical examination that help in visualisation of usually inaccessible places. Development of endoscopy, robotic surgery and new diagnostic methods made otorhinolaryngology and ophthalmology an even more exciting field. Both offer a rich surgical, and non-surgical aspect, following patients from their first screening of hearing or sight examination to presbycusis or cataract, acute or chronic conditions, fast and long-lasting procedures, and frequent and rare pathologies. After many attempts and learning from mistakes, in the year of 2021, the first successful transplantation of the trachea was achieved. This is the beauty of the diversity that not many fields offer, and in this year's CROSS you can hear more about them and the problems they are faced with as well as the solutions they offer.

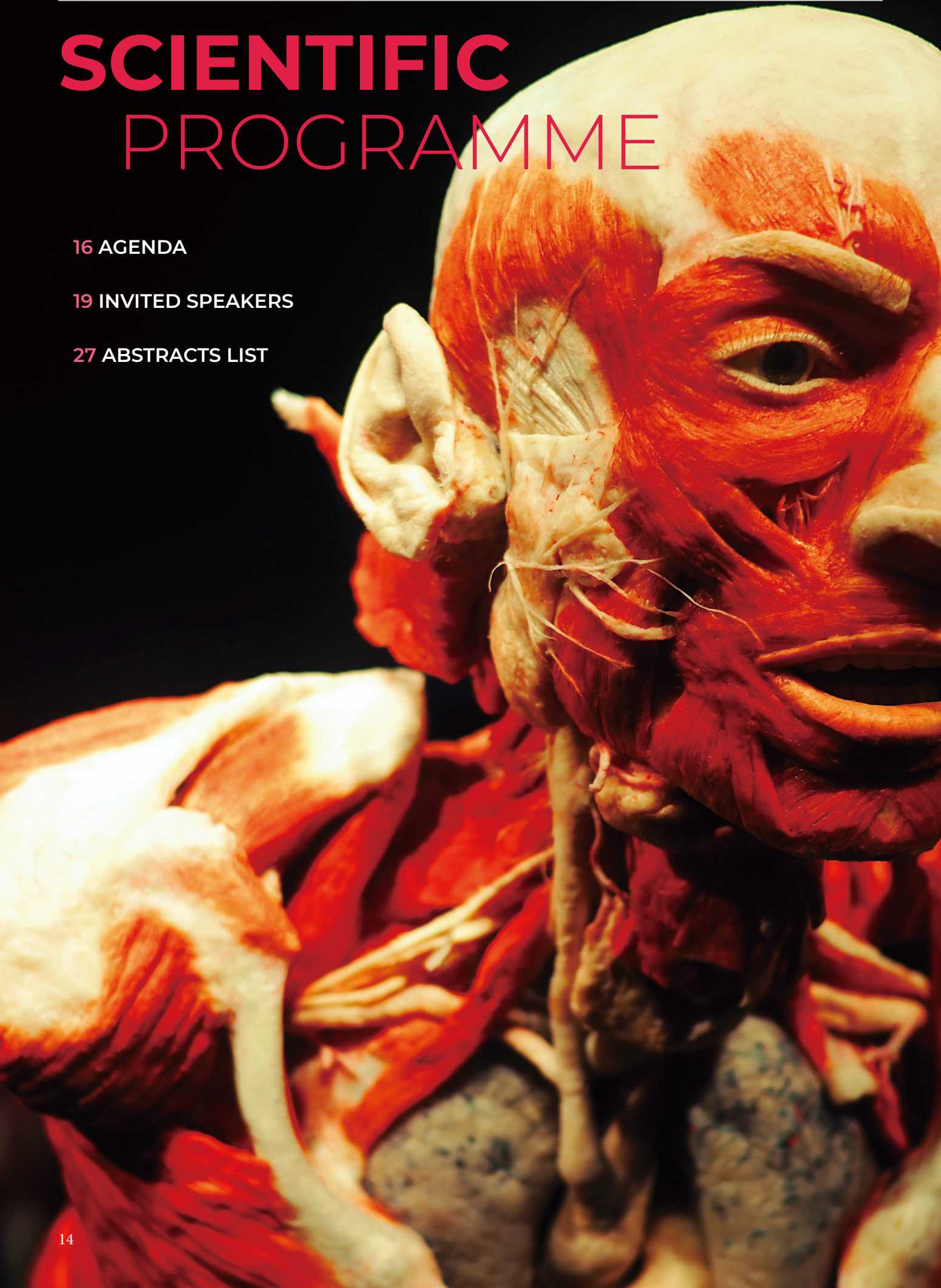
Stela Marković

SCIENTIFIC PROGRAMME

16 AGENDA

19 INVITED SPEAKERS

27 ABSTRACTS LIST



Golden Sponsor

M+GRUPA

PEOPLE INSPIRED BY PEOPLE



M+ Group is the largest independent contact center and business process technology outsourcing (BPTO) company in Southeast Europe, active also in Employment and IT services, and employing over 7000 professionals. They are genuinely in the business of customer interaction for over a decade. Their approach has always been based on continuous learning and understanding the needs of global customers.

Wednesday

APRIL 27th

School of Medicine, Šalata 3

13:00 - 16:00

Arrival and Registration

Registration Desk in front of Čačković Hall

16:00 - 18:00

Opening Ceremony & Introductory Plenary Session

Čačković Conference Hall

Welcome Messages

Vice-rector for Science, Inter-Institutional Cooperation and International Relations

Dean of School of Medicine

President of the Student Council

President of the Scientific Programme Committee

President of the Organising Committee

History of ENT in Croatia

Andro Košec, MD, PhD

Bilateral cochlear Implantation

Andro Košec, MD, PhD

Gene therapy - new horizons in ophthalmology

Assoc. Prof. Mirjana Bjeloš, MD, PhD

18:00 - 19:00

Buffet Dinner

20:00

Networking Event

Thursday

APRIL 28th

9:00 - 10:30

Zagreb Sightseeing Tour

Meeting point on Ban Jelačić Square

8:00 - 14:00

Arrival and Registration

Registration Desk in front of Čačković Hall

8:30 - 10:30

Poster Session 1

Audiology Center room 3

11:00 - 13:00

Poster Session 2

Audiology Center room 3

13:00 - 14:00 Meal break

14:00 - 16:30

Plenary Session 1 - Ophthalmology

Čačković Conference Hall

Artificial intelligence in recognition of retinal conditions; Pros and Cons

Marko Lukić, MD, PhD

Glaucoma – approaches and challenges in its treatment in the future

Primarius Sonja Jandroković, MD, PhD

15:10 - 15:30 Coffee break

Corneal diseases and transplant surgery procedures

Prof. Iva Dekaris, MD, PhD

Orbital surgery: a conceptual approach

Asst. Prof. Jelena Juri Mandić, MD, PhD

17:00 – 18:30

Workshop Session 1

Audiology Center & Croatian Institute for Brain Research

20:00

Pub Quiz

Friday

APRIL 29th

10:00 - 11:00

Institute for Forensics and Criminology Museum visit

Šalata Street 11

11:00 - 12:00

Chocolate Museum Zagreb visit

Varšavska Street 5

8:00 - 14:00

Arrival and Registration

Registration Desk in front of Čačković Hall

8:30-10:30

Poster Session 3

Audiology Center room 3

11:00 - 13:00

Poster Session 4

Audiology Center room 3

13:00 - 14:00 Meal break

14:00 - 16:30

Plenary Session 2 - Otology

Čačković Conference Hall

Auditory neuroelectronic interfaces

Asst. Prof. Damir Kovačić, PhD

Auricular reconstruction - concepts and techniques in microtia, revisional and other complex cases

Asst. Prof. Ivan Rašić, MD, PhD

15:10 - 15:30 Coffee break

Differential diagnosis of vertigo

Iva Kelava, MD, PhD

Treatment of Otosclerosis with LASER

Assoc. Prof. Krsto Dawidowsky, MD, PhD

17:00 - 18:30

Workshop Session 2

Audiology Center & Croatian Institute for Brain Research

20:00

Gala Dinner

Saturday

APRIL 30th

9:00 - 10:00

Museum of Illusions visit

Ilica Street 72

9:30 - 11:30

Zagreb ZOO

Park Maksimir main entrance

9:00 - 14:00

Arrival and Registration

Registration Desk in front of Čačković Hall

10:00 - 12:00

Poster Session 5

Audiology Center room 3

12:30 - 14:00

Lunch break

14:00 - 16:45

Plenary Session 3 - Rhinology & Laryngology

Čačković Conference Hall

From septoplasty to rhinoplasty

Assoc. Prof. Mislav Gjurić, MD, PhD

Voice disorders in children

Asst. Prof. Prim. Lana Kovač Bilić, MD, PhD & Ivana Šimić, MA, speech therapist

15:20 - 15:40 Coffee break

Gender affirmation surgery - ENT role

Nikolina Čunović, MD

Communication for every child - the role of ICT in promotion of communication and education of young children with developmental disabilities

Assoc. Prof. Jasmina Ivšac Pavliša

17:00 - 17:30

Closing ceremony

22:00

CROSS 17 After Party powered by BELUPO

Club & Lounge Roko, Jarunska Street

Silver Sponsor



CROSS17 After Party Sponsor



Invited Speakers

Associate Professor Mirjana Bjeloš, M.D., PhD

Reference Centre of the Ministry of Health of the Republic of Croatia for Pediatric Ophthalmology and Strabismus, University Eye Department, Luxturna Treatment Centre, University Hospital Sveti Duh School of Medicine, University of Osijek

Mirjana Bjeloš, specialist in ophthalmology, subspecialist in pediatric ophthalmology and strabology, was born in Zagreb, where she completed Classical Gymnasium and School of Medicine. As a resident in ophthalmology, she was awarded multiple times by the Croatian Ophthalmological Society, as well as the European Ophthalmological Society. She received her PhD in Biomedicine and Health at the Zagreb School of Medicine. She specializes in ophthalmology at various clinics in Europe. She was the executive leader of the Project "Amblyopia in four-year-old children of the City of Zagreb", that set the ground for National Preventive Program for Early Detection of Visual Impairment (2016). Assoc. Prof. Bjeloš is the author and co-author of numerous scientific papers and communications, including 13 university textbooks in ophthalmology. Her field of interest is pediatric ophthalmology, strabismus, inherited retinal dystrophies and electrophysiology of the eye, which she introduced in 2013 for the first time in Croatian ophthalmology as the modern method of objective examination of visual function in children. She is the first head of the Reference Center of the Ministry of Health of the Republic of Croatia for Pediatric Ophthalmology and Strabismus, at the Department of Ophthalmology, Clinical Hospital "Sveti Duh" in Zagreb (2015 – ongoing), and in 2019 she became the director of the Collaborative Center of the World Health Organization for Pediatric Ophthalmology and Strabismus. She is the leader of a multidisciplinary team for the application of gene therapy at the Certified Center of the Department of Ophthalmology at the University Hospital "Sveti Duh", which in July 2020 became the sixth center for gene therapy in ophthalmology in the world. For her work Assoc. Prof. Mirjana Bjeloš was given the prize the City of Zagreb Award in 2016, and in 2019 the Charter of the Republic of Croatia and the Diploma of the Croatian Medical Association.



Nikolina Čunović, M.D.

*General hospital Ogulin
Special hospital Medico, Rijeka*

Nikolina Čunović graduated from the Faculty of Medicine, Rijeka in 2013. During her studies, she was an active member of CroMSIC and participated in student exchange programs at Charles University, Prague, and Ufuk University, Ankara. After graduating and finishing an internship at CHC Rijeka in 2014, she started working as a general practitioner at Primary health Center Duga Resa. In April 2015, she started ENT residency at Sestre milosrdnice University hospital Center, Department of Otorhinolaryngology and Head and Neck Surgery. During her residency in 2019, she spent a month at Karolinska Institutet, Stockholm, Sweden. After finishing her residency in September 2020, she returned to General hospital Ogulin. Currently, she is working as an ENT specialist in General hospital Ogulin and Special hospital Medico, Rijeka.





Associate Professor Krsto Dawidowsky, M.D. PhD

*ENT University Clinic, Clinical Hospital Center Zagreb,
School of Medicine, University of Zagreb*

Krsto Dawidowsky graduated and achieved his Msc. and PhD degree in Medical School, University of Zagreb. He completed the specialization of otorhinolaryngology and subspecialization of audiology at ENT University Clinic, Clinical Hospital Center Zagreb, where he presently works as Head of Polyclinics department. At Zagreb Medical School he was appointed Assistant Professor of Otorhinolaryngology. His fields of work and interest are audiology, as well as otology and skull base surgery. He is author of 5 chapters in ENT books and published about 60 scientific articles and congress presentations.



Professor Iva Dekaris, M.D., PhD

University Eye Hospital "Svjetlost"

Iva Dekaris is a Medical Director of University Eye Hospital "Svjetlost", President-elect of the European Eye Bank Association and associate-member of the Croatian Academy of Sciences and Arts. She obtained her medical degree, Masters and PhD degree at the University of Zagreb. She trained in ophthalmology at the Universities of Zagreb and Harvard Medical School in Boston and finished Postdoctoral Cornea Research Fellowship at Harvard Medical School. Currently she teaches as ophthalmology professor at universities of Zagreb, Rijeka and Lugano (Swiss). She also acts as surgical instructor for the European Society of Cataract and Refractive Surgeons and European School for Advanced Studies in Ophthalmology. She had held dozens of invited lectures all over Europe, published more than 100 professional and scientific papers (50 in CC journals), and co-authored five international books. For her work dr. Dekaris received several rewards: Croatian State Annual Award for scientific work, Croatian Ministry of Health Award for the achievements in Ophthalmology and South-eastern European Society Award for development of ophthalmology. She is an Editorial board member of three and a reviewer of another seven international scientific journals. She currently acts as an expert for three EU projects. The area of her surgical expertise is corneal transplantation and cataract surgery, with the overall experience of over 20 000 surgeries. She was the first surgeon in south-eastern Europe to start with modern transplantation techniques - lamellar corneal grafts and transplantation of corneal limbal stem cell transplantation. She speaks english (very good), french (good), italian (average) and german (poor).

Associate Professor Mislav Gjurić, M.D. PhD

*Friedrich-Alexander-University of Erlangen, Germany
University of Zagreb School of Medicine*


Mislav Gjurić, MD, PhD (Course Director) is Professor of Otorhinolaryngology at the Friedrich-Alexander-University of Erlangen, Germany and the University of Zagreb School of Medicine. He is member of the Department of Otorhinolaryngology, University Hospital Center Zagreb, and head of the ENT practice at the Sinteza Clinic in Zagreb. Dr. Gjurić is former Professor and Vice-Chairman of the Department of Otorhinolaryngology at the J.W. Goethe University of Frankfurt am Main, Germany. Professor Gjurić is a German and Croatian board certified otorhinolaryngologist specializing in otoneurology and skull base surgery. He is one of the leading experts for the treatment of vestibular schwannomas and head and neck paragangliomas, and as such has lectured across many countries in Europe and the USA. A pioneer in lateral skull base surgery in Croatia, Dr. Gjurić organized and was invited to numerous training courses dedicated to the field of temporal bone surgery. An additional field of interest for Dr. Gjurić is endoscopic sinus surgery, which he helped to introduce in Croatia by organizing and co-chairing the first endoscopic sinus surgery course held in Split in 1994. Dr. Gjurić is also very active in cosmetic surgery with an emphasis on facial as well as head and neck plastic and reconstructive surgery.



Associate Professor Jasmina Ivšac Pavliša, speech therapist

Speech and Language Pathology Department, Faculty of Education and Rehabilitation Sciences, University of Zagreb

Jasmina Ivšac Pavliša is an associate professor at the School of Education and Rehabilitation Sciences, University of Zagreb, where she works at the Department of Speech Therapy. She completed her speech therapy studies at the above mentioned faculty in 2001. That same year, she started working as a research novice at the Department of Speech Therapy at the School of Education and Rehabilitation Sciences. Her interests are related to the early recognition of deviations in communication and language development, methods of encouragement and the development and implementation of assisted communication. She teaches undergraduate and graduate studies in speech therapy in subjects focused on social communication disorders and assisted communication. She is currently the head of the postgraduate specialist program: Early Intervention in Educational Rehabilitation. She actively participates in clinical work at the Teaching and Clinical Center, which she was in charge of on two occasions. She also works in the Cabinet for Early Communication at the same center. She has been both a leader and associate in projects that actively contributed to the implementation of several multidisciplinary projects aimed at developing low and high-tech forms of assisted communication. (for example, ICT-AAC projects, Reconciling parenting and business life through multidisciplinary social services - MULTI-SKLAD, Communication for every child - Application 21st Century to promote communication, education and social inclusion of young children with delays and developmental difficulties).






Primarius Sonja Jandroković, M.D., PhD

Day hospital and day case surgery Eye Clinic at the University Hospital Centre in Zagreb

Sonja Jandroković was born on January 31, 1969 in Beijing, China. She is married and her maiden name is Matasić. She studied at the University of Zagreb, School of Medicine and graduated on April 27, 1993. In 1991-1994, she worked at the Ministry of Health of the Republic of Croatia in the Information and Research Department (related to the issues of displaced and missing persons). From 1993-1994 she completed her internship and from 1997-2002 she had residency training in Ophthalmology at the General Hospital of Bjelovar where she worked as an ophthalmology specialist until 2009.

Since 2009 she works at the University Hospital Centre Zagreb. In 2011 she was an International classifier for visually impaired and blind persons at the International Paralympic Committee (IPC). From 2012-2014 she had glaucoma subspecialty training. From 2012-2017, she engaged in Doctoral studies of Biomedicine and Health Sciences at the School of Medicine, University of Zagreb and her doctoral thesis was "Prognostic value of the analysis of visual nerve and retina structural changes measured by optical coherence tomography in the detection of glaucoma in patients with exfoliation syndrome". In 2018 she was an associate of the School of Medicine, University of Zagreb for the field of biomedicine and health science in the area of clinical medicine, branch of ophthalmology. She has actively participated in a number of scientific and expert conferences in Croatia and abroad as well as in 1st category courses and evaluated scientific lectures. In 2016, based on her experience and expertise she was awarded the title of Primarius by the Ministry of Health. She has authored and co-authored 18 scientific papers, 60 abstracts and communications from expert or scientific conferences. She is currently working as chief of the Day hospital and day case surgery Eye Clinic at the University Hospital Centre in Zagreb and she is a member of the Steering committee of the Croatian Ophthalmological Society.



Assistant professor Jelena Juri Mandić, M.D., PhD

Department of Glaucoma, Orbital Diseases and Reconstructive Eye Surgery, Clinic for Eye Diseases, University Hospital Center Zagreb Faculty of Medicine, University of Zagreb.

Jelena Juri Mandić is an ophthalmology specialist and a subspecialist in orbital and eyelid surgery. She is the head of the Department of Glaucoma, Orbital Diseases and Reconstructive Eye Surgery, Clinic for Eye Diseases, University Hospital Center Zagreb, and Assistant Professor at the Faculty of Medicine, University of Zagreb. She is the leader of the Croatian multidisciplinary team KBC Zagreb at the European Society for Graves' Orbitopathy (EUGOGO), the head of the Reference Center of the Croatian Ministry of Health for diseases of the orbit and adnexa and the president of the Orbital and Plastic Section at the Croatian Ophthalmological and Optometric Society. She is a member of various international and domestic professional societies, and as a lecturer she has participated in more than 50 domestic and foreign congresses. In addition to professional and teaching work, she is also engaged in scientific publishing. She is the author of the university manual "Atlas of Periocular Surgery", she is the co-author of several university textbooks in Croatian and English in the field of ophthalmology and emergency medicine. She is a contributor to the 2021 International Guidelines for the Treatment of Graves' Orbitopathy published in the European Journal of Endocrinology, author or co-author of 30 scientific papers published in the international peer reviewed journals. Fields of activity: orbital surgery, lacrimal surgery, oculoplastic surgery, focal dystonia- botulinum toxins.

Iva Kelava, M.D., PhD

Department of Otorhinolaryngology and Head and Neck Surgery, University Hospital Center Sestre Milosrdnice


Iva Kwlava was born in Zagreb on July 29th, 1986. I started attending the University of Zagreb, Medical school in 2004 and I graduated in 2010. After my trainee internship at the Clinic of Infectious Diseases 'Fran Mihaljević' (from September in 2010 to September in 2011), I had worked at the Croatian Institute for Emergency Medicine (from March to December in 2012). As of December, 2012, I have been employed at the Department of Otorhinolaryngology, Head and Neck Surgery in the Sisters of Charity Hospital in Zagreb. I passed my specialist exam on August 28th, 2018 and my subspecialist exam in October, 2021. I defended my PhD thesis 'The diagnostic value of wideband tympanometry in patients who suffered from otosclerosis' on September 11th, 2019.



Andro Košec, M.D., PhD

Department of Otorhinolaryngology and Head and Neck Surgery, University Hospital Center Sestre Milosrdnice School of Medicine, University of Zagreb

Andro Košec was born in Zagreb, Croatia on September 3rd, 1985. He is an alumnus of both the Private Classical Lyceum in Zagreb and the Albuquerque Academy, USA as a recipient of a full academic scholarship from the American independent secondary schools initiative (ASSIST). He received his medical degree at the School of Medicine, University of Zagreb in 2010, with a GPA 4,93/5.00 and egregia cum laude. He was awarded scholarships for academic excellence by the President of the Republic of Croatia, the University of Zagreb and the City of Zagreb. After completing residency training at the Department of Otorhinolaryngology and Head and Neck Surgery, University Hospital Center Sestre milosrdnice in Zagreb, Croatia in 2018, he also completed postgraduate training in Otorhinolaryngology and a PhD program at the School of Medicine, University of Zagreb in 2017, with a thesis titled: „Prognostic significance of tissue proteomic profiling in cutaneous malignant melanoma of the head and neck stage I and II“. In 2018, he became board certified, passing the European Otorhinolaryngology and Head and Neck Surgery Board Exam, and is currently a Fellow in audiology, otology and neurotology at the University Hospital Center Sestre milosrdnice in Zagreb. In 2018, he was elected a scientific associate of the School of Medicine, University of Zagreb, with an assistant professor position at the Chair of Otorhinolaryngology appointment the following year. In 2021, he completed a two-year Audiology and Otology fellowship program. He is a member of the European Academy of Otology and Neurotology, the International Politzer Society for Otology and Scientific Research from 2017 and elected as an Associate Fellow to the American College of Surgeons in 2019. To date, his publication record includes 58 scientific papers, 14 book chapters and an active reviewer status in 22 scientific journals, with a reviewer mentorship appointment in the International Journal of Pediatric Otorhinolaryngology and an Editor appointment in Frontiers Allergy and Acta Clinica Croatica. He edited and authored one university textbook on temporal bone surgery. His areas of professional and scientific interest are otology, plastic and reconstructive surgery, translational research in medicine and academic medicine.





Assistant Professor Primarius **Lana Kovač Bilić, M.D., PhD**

Day hospital and day case surgery Eye Clinic at the University Hospital Centre in Zagreb

Lana Kovač Bilić graduated from the Classical Gymnasium in Zagreb and the University of Zagreb, Medical school and specialized in otorhinolaryngology, subspecializing in audiology and phoniatrics in the Department of Otolaryngology, Head and Neck Surgery, University Hospital Centre in Zagreb where she currently works. She teaches as an assistant professor at the University of Zagreb, Medical school and the Faculty of Education and Rehabilitation of the University of Zagreb and numerous postgraduate programs. She is the author of many chapters on the topic of otorhinolaryngology in various textbooks and books. She's an invited speaker in a number of domestic and international congress and the author of 34 IM and CC articles. Her specific fields of interest are the diseases and disorders of the ear, voice disorders, pediatric otorhinolaryngology and the diseases of the nose and sinuses related to breathing difficulties. She's fluent in English, French and Italian.



Assistant Professor **Damir Kovačić, PhD**

*Laboratory for Biophysics and Medical Neuroelectronics,
Department of Physics, Faculty of Science, University of Split*

Damir Kovačić, B.Sc., PhD was born on 5th September, 1973. From 1992 to 1999 he was an undergraduate in engineering physics in the Department of Physics, Faculty of Science, University of Zagreb. Between 1996 and 1998 he received multiple awards: Second Century Award of the Alexander Graham Bell Association for the Deaf, Volta Scholarship Award of the Alexander Graham Bell Association for the Deaf, Rector's Award and Oticon Focus on People Awards. In 2007 he became a PhD in Cognitive Neuroscience at the International School of Advanced Studies (SISSA) in Trieste, Italy. From 2003 to 2010 he was a young investigator at the Polyclinic SUVAG, from 2004 to 2006 he was a research fellow of the Central European Initiative. From 2012 to 2016 he was head of the Speech and Hearing research Laboratory at the School of Medicine, University of Split. In 2015 he received the Annual Award for Researcher "Kruno Prijatelj". Nowadays Damir Kovačić is an assistant professor on undergraduate and graduate courses at the Department of Physics, Faculty of Science and School of Medicine, University of Split and head of the Biophysics Laboratory at Department of Physics, University of Split and former Marie-Curie Intra-European Fellow at KU Leuven (Belgium). He is the author of 20 peer-reviewed papers, including papers in PNAS, Scientific Reports, Journal of Neuroscience, Journal of Neural Engineering, JARO, Ear and Hearing and the Journal of Acoustical Society of America. He has h-index of 9 and has been cited 650 times in Web of Science and 1120 times in Google Scholar. He works in auditory neurosciences, including cochlear implants (signal processing, clinical fittings), neuroimaging (optical topography, near-infrared spectroscopy, EEG & evoked potentials) and auditory neurophysiology (high dense single cell extracellular electrophysiology). Recently, he developed a high-density neuroelectronic interface for neurophysiological studies of in vitro neuronal cultures and is developing graphene-based neuroelectronic interfaces. His research mobility experience includes long research stays at SISSA, Trieste (5 years), KU Leuven (2 years) and IMEC, Leuven (1 year), Polyclinic SUVAG, Zagreb (6 years) and Rijksuniversiteit Groningen (6 months) as well as short stays (<2 months) at CNRS-EHESS Paris (France), Ulaan Bataar (Mongolia), Dartmouth College (USA) and the Bionic Institute, Cochlear Ltd & University of Melbourne (Australia). He leads a collaborative research project supported by Cochlear Ltd, a leading manufacturer of cochlear implants. He is experienced with research fundraising and project management and led which so far yielded > 1.8 MEuros (FP7 & H2020 grants, EU Structural grants, National grants, etc.). He is a grant reviewer and journal reviewer in multiple journals and research foundations and agencies such as European commission – REA, Graphene flagship, French National Research Agency, Croatian Science Foundation, Journal of speech, language and hearing research, The journal of the Acoustical society of America etc.

Marko Lukić, M.D., PhD

Moorfields Eye Hospital NHS Foundation Trust London, United Kingdom

Marko Lukić is a specialist in Ophthalmology and a retina subspecialist since 2020. He has been a fellow of the European Board of Ophthalmology since 2015, and since 2018 an affiliated member of the Royal College of Ophthalmologists. In 2021, he defended his PhD dissertation entitled "Short and Long Term Real-life Outcomes in Patients with Diabetic Macular Oedema Treated with Intravitreal Aflibercept Injections" at the Medical School, University of Split. He is an author and co-author of numerous publications, as well as a reviewer in the Retina Journal and European Journal of Ophthalmology. Since 2017 he has been a lecturer in clinical ophthalmology to post-graduate students at the Medical School of the University of Zagreb, Zagreb, Croatia, and in 2020 he became a lecturer at the Medical Retina High-Level Course for Optometrists organised by Moorfields Eye Hospital and University College of London, London, United Kingdom. He is a founder and director of European Medical Consultants J.D.O.O., a telemedicine-oriented business entity that, apart from offering second opinions to healthcare providers, offers advisory services to ophthalmology start-ups and investment funds. He is currently working as a Medical Bank Consultant ophthalmologist for Moorfields Eye Hospital NHS Trust as a first-ever virtual consultant. He has received multiple honours and awards, including a nomination for the Moorfields Stars Award as part of the Potters Bar Injection team in 2019.



Assistant Professor Ivan Rašić, M.D., PhD

*Department of Otorhinolaryngology and Head and Neck Surgery,
University Hospital Center Sestre Milosrdnice
School of Medicine, University of Zagreb*

Ivan Rasic MD, PhD graduated at the University of Zagreb School of Medicine in 2007. with summa cum laude. He completed his residency in Otorhinolaryngology and Head and Neck Surgery at the Department of Otorhinolaryngology and Head and Neck Surgery at the Sestre milosrdnice University Hospital Center and became a consultant in 2013. He attended observational and clinical fellowships in various prestigious departments in the USA, Canada, Germany, the Netherlands and Turkey. In March 2017, he completed his Fellowship training in Facial Plastic and Reconstructive Surgery of the Head and Neck. He completed his PhD in 2017. at the Postgraduate Department of Biomedicine and Health at the University of Zagreb School of Medicine, titled „Clinical significance of BORIS and MYC gene expression in hypopharyngeal squamous cell carcinoma“. He was elected as an associate professor at the Department of Otorhinolaryngology and Head and Neck Surgery, University of Zagreb School of Medicine in 2019. He is a full member of the European Academy of Facial Plastic Surgery (EAFPS), Fellow of the American College of Surgeons (FACS), member of Croatian Society of Otorhinolaryngology and Head and Neck Surgery. His fields of particular interest are primary and revision rhinoplasty, thyroid and parathyroid surgery, and is one of the leading experts in ear reconstruction with autologous rib cartilage in the broader region.





Ivana Šimić, MA, speech therapist

ENT University Clinic, University Hospital Center Zagreb

Ivana Šimić was born on December 24th, 1985. After graduating from Nursing School, she attended the University of Applied Health Sciences and completed her program. In 2012, she graduated from the Faculty of Education and Rehabilitation in Zagreb, majoring in speech therapy. In 2020, she enrolled in a postgraduate doctoral program 'Disorders of the tongue, speech and hearing' at the Faculty of Education and Rehabilitation in the University of Zagreb. In 2020, she was elected as a title associate assistant lecturer of the subject of phoniatrics. She is a mentor to students majoring in speech therapy in the course 'Disorders of the voice II' at the Faculty of Education and Rehabilitation in the University of Zagreb and takes part in conducting classes and practical exercises at several different courses. As of 2016, she has been employed at the Department of ENT diseases, Head and Neck Surgery at the University Hospital of Zagreb, where her field of interest is the voice. She has been published as a co-author in a number of scientific and professional articles in journals with international reviews. She is both an active and passive participant at international scientific and professional conferences. She is a member of the Croatian Speech Therapy Association, the Croatian Association of the Tumors of the Head and Neck and the Croatian Audiology and Phoniatrics Association.



Abstracts List

Basic Science

BS01 Natural flavonols of plant origin as novel carbon monoxide releasing molecules

Sriram Balasubramani, Panshul Mehta, Dafni Vlachopoulou, Lucie Muchová

BS02 DIPEPTIDYL-PEPTIDASE IV (DPP IV/CD26) AFFECTS THE WOUND HEALING PROCESS IN A STREPTOZOTOCIN-INDUCED DIABETES MODEL IN MICE

Lara Batičić, Dijana Detel, Edvard Bedoić, Jadranka Varljen

BS03 Effects of Pentadecapeptide BPC 157 on Ulcer, Intracranial, Portal and Caval Hypertension and Aortal Hypotension after Stomach Perforation

Luka Kalogjera, Lea Klepač, Hrvoje Vraneš, Vilim Dretar, Ivan Maria Smoday, Luka Ćorić, Katarina Oroz

BS04 Histological Aspect of Pentadecapeptide BPC 157 Therapeutic Effects on Early and Definitive Spinal Cord Injury

Katarina Oroz, Ivan Maria Smoday, Luka Kalogjera, Luka Ćorić, Hrvoje Vraneš, Leon Palac, Mislav Pečnik

BS05 Ketamine, relation to the NO-system and BPC157

Ivan Maria Smoday, Hrvoje Vraneš, Katarina Oroz, Luka Ćorić, Luka Kalogjera, Mislav Pečnik, Vilim Dretar

BS06 Synthesis and evaluation of biased agonists of immunometabolic receptor GPR84: a new class of immune cell modulators

Vanessa Rogga, Pinqi Wang, Vincent Luscombe, Angela Russell

BS07 The effect of chronic oral d-galactose administration on colon redox homeostasis in a rat model of sporadic Alzheimer's disease

Mihovil Joja, Jan Homolak, Melita Šalković-Petrišić

BS08 Stable Gastric Pentadecapeptide BPC 157 Countering Effects on Postsplenectomy Complications in Rats

Luka Ćorić, Katarina Oroz, Hrvoje Vraneš, Mislav Pečnik, Tajana Đurašin, Ivan Maria Smoday, Vilim Dretar

Case reports

CR01 A 14-year old girl with abdominal pain and inability to urinate – case report of imperforate hymen

Ante Blažević, Marija Vukojević, Ante Vuković, Egon Kruezi

CR02 A case of an unilateral sensorineural hearing-loss after SARS CoV-2 infection in a 8-year-old boy

Andrija Nekić, Lucija Lučev, Lana Kovač Bilić

CR03 A rare case of a hemorrhagic renal angiomyolipoma during pregnancy: a case report

Marko Belošević, Natalia Pappo, Maja Banović

CR04 Acute kidney injury as a result of hypovolaemia and excessive potassium intake

Kristijan Harak, Marin Glavčić, Marinko Grgić

CR05 An atypical case of pleural empyema

Sandra Knežević, Ana-Marija Petani, Lucija Kučina, Maša Kopusar, Ivana Žitinić

CR06 An unusual case of hand, foot, and mouth disease in a 35-year old immunocompetent male

Marin Glavčić, Kristijan Harak, Marinko Grgić, Ivona Ćudina

CR07 Application of alteplase (in a life saving situation) despite absolute contraindication.

Grga Roglić, Ivica Premužić Meštović

CR08 Astragalectomy as “last resort” in treatment of avascular necrosis of the talus

Dinko Ezgeta, Afan Ališić, Damjan Dimnjaković

CR09 Bilateral blindness due to endophthalmitis and corneal ulcer caused by *E. faecalis* as a result of chronic intentional self-injury

Rea Deghenghi, Dora Cvrtila, Sanja Masnec, Ivan Škegro, Miro Kalauz, Marija Barišić Kutija, Tomislav Kuzman

CR10 Clinical presentation of vision loss after emulsification of silicone oil due to pars plana vitrectomy

Karla Bodakoš, Antonio Kokot, Slaven Balog

CR11 A patient with thrombophilia and constrictive pericarditis – case report

Matea Severin, Maja Sirovica, Martina Lovrić Benčić

CR12 Congenital hypotonia of an unclear origin

Andrija Matijević, Danijel Mikulić, Grgur Matolić, Valentina Matijević

CR13 Case of allergic reaction to polyethylene-glycol from rectal suppositories and its relation to COVID-19 vaccination

Stjepan Brnić, Robert Likić

CR14 ECTOPIC PREGNANCY IN CESAREAN SECTION SCAR

Laura Vidović, Marina Šprem Goldštajn

CR15 Multiple pulmonary metastases from a pleomorphic adenoma of the parotid gland

Robert Gečević, David Glavaš Weinberger, Marko Gangur, Ivan Đureković, Ivica Lukšić, Marko Tarle

CR16 Large aortocoronary saphenous vein graft aneurysm – a case report

Natalia Pappo, Lana Palčić, Goran Međimurec, Kristina Krželj, Dražen Belina

CR17 A Case Report of a Mysterious Rapidly Enlarging Neck Mass That Is neither a Tumour nor an Inflammation

Antonela Geber, Vesna Galjuf, Andro Košec, Siniša Stevanović

CR18 Difficulties encountered by a deaf-mute patient and paresis of the vocal cords after COVID-19 infection

Mirella Graffel, Katarina Skopljak, Lucia Bekić, Luka Lažeta

CR19 A rare presentation of Langerhans cell sarcoma in the parotid gland

Stela Marković, Josipa Živko, Vesna Bišof

CR20 ACUTE LIVER FAILURE IN SECONDARY HEMOPHAGOCYTIC LYMPHOHISTIOCYTOSIS AFTER COVID – 19 VACCINATION

Matea Živko, Nikola Sobočan

CR21 Aplastic anemia in a patient with autoimmune Hepatitis

Anđela Deak, Slobodanka Ostojić Kolonić

CR22 Atypical Raynaud syndrome and skin changes caused by late stage of Lyme disease with cryoglobulinemia

Paola Negovetić, Ena Parać, Tin Šklebar, Ljiljana Smiljanić Tomičević

CR23 Balloon aortic valvuloplasty as a bridge to liver transplantation in patients with severe aortic stenosis

Martina Petrinović, Dora Meštović, Lucija Mihaljević, David Preložiček, Vlado Vlaho Čubela

CR24 Breast reconstruction and capsular contracture as its complication

Andrea Kostić, Matea Kostić, Manuela Bajan, Lucija Gatin, Anto Dujmović

CR25 Catamenial Pneumothorax due to Thoracic Endometriosis: A Case Report

Lea Jerkić, Nikolina Jupek, Tomislav Bečejac, Marko Vrančić, Ivan Bunjevac, Dubravko Jalšovec

CR26 Cervical cystic lymphangioma in a pediatric patient: a case report

Nokolina Jupek, Lea Jerkić, Mario Bilić

CR27 DELAY IN DIAGNOSIS OF BEHCET'S SYNDROME – A CASE REPORT

Olesia Strelchenia, Andrej Samoilenko, Vadym Oryshchenko, Tetiana Strelchenia

CR28 Dysmorphophobia

Dora Herceg, Ena Parać, Petrana Brečić

CR29 HEART TRANSPLANTATION AS THERAPY FOR DOXORUBICIN INDUCED CARDIOMYOPATHY

Mihovil Santini, Nika Barbara Pravica, Mario Udovičić

CR30 Hyperthyroidism as a secondary cause of worsening hypertension - a case report

Mia Edl, Lucija Čolaković, Lada Zibar

CR31 Intraductal papillary neoplasm of the bile duct (IPNB) as an uncommon cause of abdominal pain and cholangitis

Stjepan Herceg, Lucija Virović Jukić

CR32 Invasive Fungal Sinusitis Presenting as Unilateral Vision Loss: A Case Report

Lea Jerkić, Kristina Lončarić

CR33 Is it Crohn's or coeliac, or both?

Matilda Sabljak, Ana Barišić

CR34 LARYNX – PRIMARY MANIFESTATION OF T-CELL ACUTE LYMPHOBLASTIC LEUKEMIA

Jelena Benčić, Drago Baković, Lana Kovač Bilić

CR35 Lingua villosa nigra – a case report

Matea Smajić, Petra Smajić, Nika Pušeljić, Ivanka Muršić, Lada Zibar

CR36 Long lasting tinnitus and vertigo as a result of a facial nerve anomaly – A CASE REPORT

Marinko Grgić, Marin Glavčić, Kristijan Harak

CR37 Low back pain - an unusual presentation of acute lymphoblastic leukemia in a child – a case report

Kiarash Pourmodjib, Zrinko Šalek, Ernest Bilić

CR38 Meningoencephalic herniation of the temporal bone

Stela Marković, Josipa Živko, Mislav Malić

CR39 Multifragmental orbital floor blowout fracture followed by car accident and treatment with prolene mesh

Lovro Kovač, Nikolina Bajlo

CR40 Multiple primary tumours: papillary thyroid carcinoma, chronic lymphocytic leukemia (CLL) and Non-Hodgkin mantle cell lymphoma in a male patient

David Glavaš Weinberger, Mihael Grzelja, Inga Mandac Smoljanović

CR41 New Variant of Unknown Significance found in ERCC6 gene - Cerebro-oculo-facio-skeletal Syndrome

Nika Pušeljić, Ivana Jurić, Matea Smajić, Silvija Pušeljić

CR42 NUSINERSEN TREATMENT IN SMA TYPE III: TREATING AN ADULT PATIENT

David Preložiček, Dora Meštović, Lucija Mihaljević, Martina Petrinović, Ervina Bilić

CR43 Open surgical treatment of malperfusion syndrome in Stanford B aortic dissection

Stjepan Pinotić, Zlata Pinotić, Krešimir Pinotić

CR44 The importance of long-term treatment of Cholesteatoma

Vana Stojić, Tea Štrbac, Stjepan Frkanec, Andro Košec

CR45 Tubulointerstitial Nephritis in a Patient with Ulcerative Colitis

Adriana Adamović, Ivica Horvatić

CR46 Upper GI bleeding in a patient with rare inherited bleeding Disorder – a case report

Nora Knez, Tin Rosan, Nikolina Novak, Anna Mrzljak, Dražen Pulanić

CR47 DIAGNOSIS AND MANAGEMENT OF TUMOR LYSIS SYNDROME IN A 10-YEAR-OLD PATIENT

Marin Boban, Matej Jelić

CR48 Endogenous Endophthalmitis with Panophthalmitis – case report

Petra Kovačević, Matej Lovrić, Nika Samardžić, Martina Lukšić, Jelena Juri Mandić

CR49 External fixation with a locking plate for a tibial fracture complicated by osteomyelitis: a case report

Lea Kalajžić, Tin Karakaš, Maša Kopušar, Srećko Sabalić

CR50 Facial nerve paralysis caused by a parotid haemangioma: a case report

Antonia Bukovac, Marko Velimir Grgić, Luka Bukovac, Branimir Bradarić-Šlujo, Gabrijela Buljan, Anton Malbašić

CR51 Follow up of uveal melanoma - case report

Matej Lovrić, Petra Kovačević, Dario Vučić, Franciska Lovrić, Suzana Konjevoda

CR52 CASE REPORT: GLOMUS JUGULOTYMPANICUM

Andro Košec, Josip Prnjak

CR53 Immunotherapy and Gamma knife "stop and go" therapy in a mRCC patient

Nikolina Novak, Marija Gamulin, Tin Rosan, Nora Knez

CR54 Intraocular non-Hodgkin lymphoma mimicking Uveitis

Marija Vukojević, Ante Blažević, Mislav Blažević, Nenad Vukojević

CR55 Case report: Invasive fungal rhinosinusitis in the immunocompetent host

Matilda Pudić, Katarina Đurić Vuković

CR56 HACEK endocarditis complicated by pancreatitis after antibiotic therapy

Iva Bušić, Ivana Jurin

CR57 Lymphocytic interstitial pneumonitis (LIP) as an extraglandular manifestation of primary Sjögren's syndrome: a case report

Nikolina Kuštra, Robert Ledenko, Ivan Padjen

CR58 Manifestations of tuberculosis that we rarely think about

Maša Kopušar, Tin Karakaš, Lea Kalajžić, Sandra Knežević, Klara Poldan Skorup

CR59 NOT EVERY RESPIRATORY FAILURE NOWDAYS IS COVID. POMPE DISEASE

Dina Gržan, Ivan Pećin, Vesna Galjuf

CR60 Pemetrexed treatment for adenocarcinoma of unknown primary origin with BAP-1 mutation –implementing NGS analysis into clinical practice

Andrea Racetin, Borislav Belev

CR61 Pituitary apoplexy in a patient with atrial fibrillation as a side effect of dabigatran treatment

Dora Cvrtila, Tina Dušek

CR62 Pregnancy outcomes in women with Fontan Circulation

Ozana Miličević, Vesna Elvedi Gašparović, Iva Barišić, Mia Alerić, Leo Matijašević

CR63 RECOGNIZING SPONDYLOARTHRITIS IN PRIMARY CARE

Marin Boban, Dragan Soldo

CR64 Formation of pseudoaneurysm and arteriovenous fistula following percutaneous left atrial appendage occluder implantation

Jakov Emanuel Bogdanić, Jurica Putrić Posavec, Vedran Velačić, Ivan Prepolec

CR65 Recurrent retroperitoneal dedifferentiated Liposarcoma

Ines Trkulja, Lucija Brkić, Klara Kuzman, Emil Kinda, Petar Matošević

CR66 Renal denervation as a therapeutic modality in a patient with resistant hypertension

Tin Rosan, Nikolina Novak, Ingrid Prkačin

CR67 Somatic cough syndrome in a 13-year-old girl: a case report

Jelena Bošnjak, Ana Đanić Hadžibegović, Martina Fojtik Budek

CR68 Temporal bone meningocele presenting as a secretory otitis media

Gabrijela Buljan, Jelena Bošnjak, Antonia Bukovac, Anton Malbašić, Jakov Ajduk

CR69 Testicular cancer masquerading as an incarcerated inguinal hernia – A case report

Karla Lužaić, Lucija Brkić, Tomislav Bruketa

CR70 The role of fortified eyedrop antibiotic therapy in *Pseudomonas aeruginosa* corneal infection – a case report

Mia Edl, Suzana Matić, Tomas Edl, Lucija Čolaković

CR71 Therapeutic penetrating keratoplasty in a patient with acute perforated corneal ulcer caused by *Pseudomonas aeruginosa* keratitis

Božana Mrvelj, Tomislav Kuzman

CR72 Case report: Transcervical approach for removal of the tumor of the primary parapharyngeal space (PPS)

Dora Rebeka Divković, Ana Kvolik

CR73 Where did the lungs go? Vanishing Lung Syndrome in an HIV positive patient

Hana Škornjak, Đivo Ljubičić

CR74 Hepatitis E virus infection after kidney transplantation

Adrijan Tiku, Petra Terzić, Karlo Tkalec, Željka Jureković, Anna Mrzljak

CR75 External and a four-act internal pelvic fixation in a patient with polytrauma

Leo Matijašević, Ozana Miličević, Lucija Brkić, Tin Ehrenfreund

CR76 Overlap Syndrome at Rheumatology Department - Case Report

Mia Šelović, Marija Bakula

CR77 Juvenile dermatomyositis with vasculopathy

Mia Kovačević, Magdalena Kujundžić, Marijan Frković

CR78 Diabetic ketoacidosis and electrolyte disorders in patient with short bowel syndrome following acute mesenteric ischemia

Martina Pastorčić, Daniela Bandić Pavlović

CR79 LAPAROSCOPIC TREATMENT OF POST-TRAUMATIC SPLENIC CYST

Nora Rako, Tea Cindrić, Hanna Pašić, Jasenka Kraljević

Clinical medicine

CM01 Survival analysis of COVID-19 in the population of Mexico

Polanco Armenta Christian Alexis

CM02 Botulin toxin A in lower lid entropion correction

Ana Ninčević, Miro Kalauz, Josip Knežević, Sanja Masnec

CM03 EFFECTS OF COVID-19 PANDEMIC ON ONCOLOGICAL PATIENTS' DEMOGRAPHICS AND PET-CT UTILIZATION

Berkin Ersoy, Elif Cengiz, Eylül Şaenödeyici, Gizem Yildirim, Dengiz Koray Şahintürk, Mustafa Alperen Koşucu, Fatma Selin Soyloğlu

CM04 The impact of surgery type and prosthesis material on hearing results in stapes surgery

Josipa Živko, Stela Marković, Andro Košec

CM05 TOCILIZUMAB treatment in COVID-19

Lucija Vusić, Marija Gomerčić Palčić

CM06 Aortic root valve-sparing surgery: influence on the left ventricle

Lorka Tarnovski, Igor Rudež

CM07 Evaluation of Quantiferon (QFN) SARS-CoV-2 in vaccinated and recovered individuals

Ana Horvat, Marija Gomerčić Palčić

CM08 The role of anterolateral ligament in anterior cruciate ligament reconstruction – plantaris tendon graft technique

Mario Josipović, Josip Vlajić, Jure Serdar, Marko Šimunović, Dinko Nizić, Mislav Jelić

CM09 A COMPARISON OF PROSTATE BIOPSIES AND PROSTATE CANCER DIAGNOSIS MADE BEFORE AND DURING COVID-19 PANDEMIC

Stjepan Frkanec, Toni Zekulić, Hrvoje Saić, Ilija Jurić, Tomislav Kuliš, Željko Kaštelan

CM10 Plantaris tendon autograft successfully restores patellar stability in adolescent isolated medial patellofemoral ligament reconstruction – preliminary results

Josip Vlajić, Mario Josipović, Mislav Jelić

CM11 Predictors of adrenal crisis in patients with Addison's disease

Tea Cindrić, Gaja Tolić, Tea Stipetić, Hanna Pašić, Matea Matković Trivunčević, Nora Rako, Tina Dušek

Literature review

LR01 "Have a safe flight" without barotraumas

Miruna Ioana Chirilă, Andra Diana Tanasa, Ioana Lipan, Răzvan Constantin Ursachi

LR02 ALZHEIMER – FEELING YOUNG, MIGHT FORGET LATER

Adrian Iulian Ababei, Andra Diana Tanasa

LR03 Myocarditis following COVID – 19 mRNA vaccine administration*Mladen Pospisil, Eva Pleško, Lucija Pešorda***LR04** Rethinking the basics: the usefulness of Lasegue's sign in diagnosing intervertebral disc herniation; a literature review*Dora Dragaš, Đidi Delalić, Josip Kajan, Dean Mileta***LR05** SLP and the Pandemic: Speech-Language Pathologists' Role in Management and Rehabilitation of Patients with COVID-19*Paola Danjek***LR06** SPREADING THE WORD ABOUT ALPHA1-ANTI-TRYPsin DEFICIENCY*Andra Diana Tanasa, Adrian Iulian Ababei***LR07** The smell of Parkinson*Miruna Ioana Chirilă, Adrian Iulian Ababei, Răzvan Constantin Ursachi***LR08** TRANSDERMAL FENTANYL PATCH: A SMOOTH CRIMINAL*Andra Diana Tanasa, Miruna Ioana Chirila, Ioana Lipan***LR09** Demodex- a silent "friend"*Adrian Iulian Ababei, Miruna Ioana Chirilă*

Other

O01 Comparison of clinical guidelines for the treatment of acute uncomplicated cystitis*Matej Lovrić, Petra Kovačević, Franciska Lovrić, Kamelija Horvatović***O02** Comparison of Drug Consumption in Croatia in Pre-pandemic 2019 and Pandemic 2020*Anton Malbašić, Antonia Bukovac, Gabrijela Buljan, Sandra Gašpar***O03** Establishment of an ovarian tissue bank in Croatia*Katarina Bilić, Marija Vilaj, Davor Ježek*

ABSTRACTS

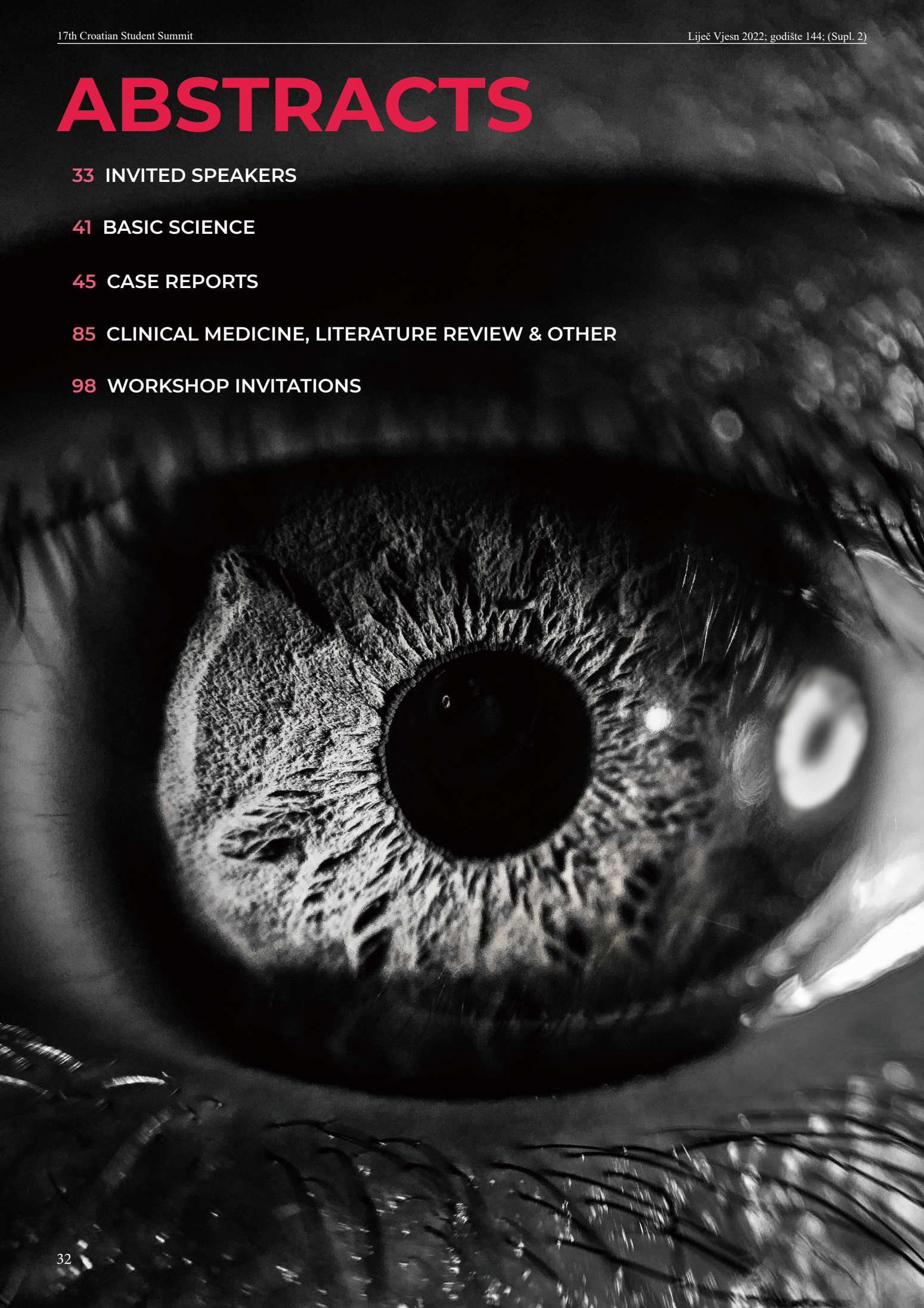33 INVITED SPEAKERS

41 BASIC SCIENCE

45 CASE REPORTS

85 CLINICAL MEDICINE, LITERATURE REVIEW & OTHER

98 WORKSHOP INVITATIONS



ABSTRACTS

Invited Speakers

IS01

Gene therapy - new horizons in ophthalmology

Associate Professor Mirjana Bjeloš, M.D., PhD

DOI: <https://doi.org/10.26800/LV-144-supl2-IS01>

Reference Centre of the Ministry of Health of the Republic of Croatia for Pediatric Ophthalmology and Strabismus, University Eye Department, Luxturna Treatment Centre, University Hospital Sveti Duh School of Medicine, University of Osijek

Over a decade of research and development culminated in December 2017 with United States Food and Drug Administration (FDA) approval of voretigene neparvovec-rzyl (VN) treatment for RPE65 mutation-associated inherited retinal dystrophy (IRD). This is the first approved gene therapy for a hereditary genetic disease and the first and only pharmacologic treatment for an IRD. By the end of 2018 VN has been authorized for use in the EU. Thus, the aim of gene therapy using voretigene neparvovec is to improve visual function and prevent blindness by halting the progressive natural course of disease. The term itself, inherited retinal dystrophy, encompasses a wide range of blinding retinopathies, with marked phenotypic and genotypic diversity, characterized by anatomical and functional damage of retinal cells. Worldwide, 1:2000 individuals worldwide suffer from IRDs. RPE 65 dystrophy, affecting 1:200000, causes Leber congenital amaurosis type 2 (LCA2) and pigmentary retinopathy type 20 (RP20). RPE65 is expressed in RPE cells, encoding a protein RPE65, retinoid isomerohydrolase, crucial in the visual cycle. Both RP and LCA are devastating diseases not just because these children have terrible vision at birth, but because their vision is getting progressively worse ending in complete blindness. Age of onset of biallelic RPE65 mutation-associated retinal dystrophy is variable and can range from infancy into young adulthood. Symptoms include nystagmus, tendency to fixate on light, nyctalopia, constricted visual fields and flat scotopic signals on electroretinogram (ERG). During childhood, in most cases, the retina appears pale but without characteristic pigment accumulation.

Because of the complexity and variability of signs and symptoms, genetic testing is a must to enable classifica-

tion of disease.

VN utilizes AAV2 as a vector to deliver a single-strand DNA molecule with the coding sequence (cDNA) of the RPE65 transgene to the RPE. This therapeutic strategy, called gene augmentation, ameliorates the lost function through delivery and expression of a normal gene. For this delivery, vitrectomy and iatrogenic retinal detachment should be induced. Normal RPE65 protein now can be manufactured, restoring the visual cycle.

Treatment is administered to each eye on separate days, no fewer than 6 days and no more than 18 days apart. Patients undergo treatment only once because this treatment has a long lasting effect.

To be treated with VN two major criteria must be fulfilled. First, the patient must have biallelic RPE65 mutation and there must be a sufficient number of viable cells. VN safety profile is consistent with vitrectomy and subretinal injection procedure.

Measurable improvement from as early as day 30 is achieved in 93% of patients who all benefited from improved functional vision and majority (72%) achieved maximum improvement.

In case of biallelic RPE65 mutation refer the patient to Luxturna treatment centers. The University Eye Department University Hospital Sveti Duh in Zagreb, Croatia was designated as the 6th world's gene therapy center in July 2020., after successful full reimbursement of the drug by the Croatian National Health Insurance Fund in January 2020.

The multidisciplinary team consists of a pediatric ophthalmologist, an IRD specialist, three retinal surgeons with experience in subretinal application, pharmacist and a geneticist. In the 1.5 year of the designation the Centre has successfully treated 8 Croatian patients and 7 non-Croatian EU citizens.

IS02**Gender affirmation surgery - ENT role**

Nikolina Čunović, M.D.

DOI: <https://doi.org/10.26800/LV-144-supl2-IS02>*General hospital Ogulin*

Transgender people experience incongruence between their biological sex and their gender identity. Gender dysphoria is a psychological distress that results from that incongruence. Gender-affirming treatments have proven effective in relieving gender dysphoria. One in four transgender people will undergo gender affirmation surgery which includes facial (rhinoplasty, chondrolaryngoplasty, voice surgery), chest, and genital surgery. Voice is an important aspect of gender affirmation. The primary goal of voice-related gender-affirming treatment options is to reduce gender dysphoria by creating congruency between a patient's voice and their gender identity. Transgender women experience issues with hormone replacement therapy (HRT) as estrogen does not impact vocal cords in the way testosterone does. When voice therapy fails, ENT procedures can make a difference.

Phonosurgery techniques for vocal feminization include cricothyroid approximation, vocal fold webbing, laser vocal fold reduction (LAVA), and thyroid elevation (FemLar).

We present a 28-year-old patient who underwent laser-assisted voice adjustment (LAVA) as part of her transition from man to woman (MTF) using CO2 lasers. Before LAVA, rhinoplasty and thyroplasty were performed to reduce the size of the larynx and the protrusion of Adam's apple. The goal of LAVA was the "feminization" of the patient's voice. Phonetic analysis of the voice was performed pre and postoperatively. Prior to the operation, the voice is (reading non-fricative text for 70 s (T1)) high for male voice $F_0 = 156$ Hz. After the operation, the voice is slightly higher $F_0 = 170$ Hz. In spontaneous speech, the voice is medium-high for a male voice before the surgery ($F_0 = 105$ Hz), and after surgery, F_0 is 164 Hz in spontaneous speech, which is also slightly lower than the average pitch of a female voice, but nonetheless, more similar to it. The patient is satisfied with her physical appearance and new voice.

IS03**Treatment of Otosclerosis with LASER**

Assistant Professor Krsto Dawidowsky, M.D., PhD

DOI: <https://doi.org/10.26800/LV-144-supl2-IS03>*ENT University Clinic, University Hospital Center Zagreb**School of Medicine, University of Zagreb*

Otosclerosis is a hereditary disease presenting with progressive hearing loss, tinnitus, and normal otoscopic findings. It is caused by the changes in bone metabolism of otic capsule and is considered as a multifactorial disease, caused by both genetic and environmental factors. Present studies have found so far nine genes as the candidates of the disease, and in some patients otosclerosis has an autosomal dominant mode of inheritance with incomplete penetrance. Investigations of environmental factors (e.g. measles virus infection) as well as hormonal and immune factors in some connective tissue diseases have suggested having a role in the etiopathogenesis of the otosclerosis. Despite the unclear etiology, formation of a hard bone on the annular ligament leads to the stapes fixation with the consecutive conductive hearing loss.

Controversial etiopathogenesis, however, doesn't influence the successful surgical treatment of otosclerosis. Most often used surgery procedure today, the stapedotomy, has a success rate of more than 90% in restoring the hearing loss, while the rate of tinnitus treatment is much lower, about 50%. The procedure is well known for several decades and is considered as a minimal invasive surgery. Critical part of the procedure with highest risk of possible postoperative deafness is drilling the hole in a stapes footplate for the insertion of a prosthesis. Standard and widely used drilling method with diamond burr can be replaced for more security with CO2 LASER.

This presentation gives contemporary data of etiopathogenesis, clinical diagnostics and treatment of otosclerosis, with accent on the LASER surgery procedure.

IS04**Corneal diseases and transplant surgery procedures**

Professor Iva Dekaris, M.D., PhD

DOI: <https://doi.org/10.26800/LV-144-supl2-IS04>*Eye Clinic Svjetlost**School of Medicine, University of Rijeka*

Depending on corneal disease and whether the pathological process affected the full thickness of the cornea or only its surface, it is possible to adjust the surgical technique and apply the perforating keratoplasty (full thickness corneal transplantation) or lamellar corneal transplantation (partial thickness transplantation depending on which part is affected by the disease).

Penetrating transplantation is an operation in which a full thickness of the sick cornea is replaced with a healthy donor cornea. Recovery of eyesight is much slower compared to the lamellar transplantation, but today it is still used for diseases that affect all layers of the cornea.

This method of transplantation has been the gold standard in the treatment of corneal diseases for more than a century and is still indispensable in cases of scars (leucoma) affecting the full thickness of the cornea, corneal hydrops, pre-perforations of the cornea and perforating corneal injuries. After the perforating keratoplasty, several months are needed for the recovery of visual acuity. Lamellar transplantation (DSAEK, UT-DSAEK, DMEK) is an advanced technique in which only the diseased portion of the cornea is transplanted. The eyesight recovers quickly, already within a few weeks; the possibility of complications is small and rejection of the transplanted cornea is extremely rare. This method of lamellar transplantation is applied for diseases such as: pseudo-phakic bullous keratopathy, Fuchs' dystrophy, decompensated previous corneal graft etc. DSAEK is the most commonly performed corneal transplantation method in Europe, while DMEK accounts for over 60% of all corneal grafts in the USA. The advantage is that the biggest hole on the surface of the eye is only 3 mm and such a small incision preserves the normal curvature of the cornea which is important for better eyesight and integrity of the globe. Postoperative recovery is fast and good vision is achieved in just a few weeks.

Corneal transplant surgeries are performed under general anesthesia or under local anesthesia potentiated by intravenous sedation. The procedure of corneal transplantation lasts on average 30 min.

IS05**From septoplasty to rhinoplasty**

Associate Professor Mislav Gjurčić, M.D., PhD

DOI: <https://doi.org/10.26800/LV-144-supl2-IS05>*ENT University Clinic, University Hospital Center Zagreb**School of Medicine, University of Zagreb School of Medicine, Friedrich-Alexander-University of Erlangen, Germany*

Correction of the nasal septum is the most frequently performed surgery in the nose for the incidence of congenital septal deformities is high. However, septal deviation may not only impair nasal breathing but may also have an impact on the form of the whole nasal pyramid. The correction necessitates the expertise in both septal and rhinoplasty procedures. The septorhinoplasty is meanwhile probably the most popular procedure in aesthetic surgery.



IS06**Communication for every child - the role of ICT in promotion of communication and education of young children with developmental disabilities**

Associate Professor Jasmina Ivšac Pavliša, PhD

DOI: <https://doi.org/10.26800/LV-144-supl2-IS06>*Department of Speech and Language Pathology,
Faculty of Education and Rehabilitation Sciences,
University of Zagreb*

Early childhood intervention is a well known concept that promotes integrated and coordinated services for children in the preschool period and their families. In Croatia the services of early intervention are divided into several systems (health, social welfare, education, non-governmental system) and the procedures of early assessment and services are not equally distributed within the country. The parents of young children in Croatia still struggle for services and information. As it is important to provide support for all children at risk and disseminate knowledge about evidence-based practice, the professionals from two faculties from University of Zagreb (Faculty of Education and Rehabilitation Sciences, Faculty of Electrical Engineering and Computing) joined their forces and started a year long interdisciplinary collaboration (<http://www.ict-aac.hr/index.php/hr/>). This team conducted several projects together focused on ICT solutions for children with complex communication needs. Some of the projects were supported by UNICEF Croatia and Communication for every child is one of them. The goals of the mentioned project were to (1) strengthen the capacities of professionals and institutions in providing Alternative and Augmentative Communication with children 0-8 years, (2) making the assistive technology and software solutions available for children 0-8 years and their families. The presentation will cover the concept of early intervention and a necessity of interdisciplinary collaboration between the systems, the type of children that require support as well as an overview of the project Communication for every child.

IS07**Glaucoma - approaches and challenges in its treatment in the future**

Primarius Sonja Jandroković, M.D., PhD

DOI: <https://doi.org/10.26800/LV-144-supl2-IS07>*Clinic for Eye Diseases, University Hospital Center
Zagreb
School of Medicine, University of Zagreb*

Glaucoma is a multifactorial optic neuropathy in which there is a characteristic acquired loss and damage of retinal ganglion cells, resulting in optic nerve damage and visual field defect. The disease is progressive and asymptomatic, and many (large number) of patients are not even aware of the disease. It is the second most common cause of blindness worldwide and a significant public health problem.

Glaucoma treatment is a big challenge because it should be focused on neuroprotection. Direct neuroprotection is supposed to specifically affect the ganglion cell death rate and/or the neuroregeneration of damaged cells. Gene and cell therapy drugs offer new opportunities to address unmet medical needs and improve many diseases and injuries. Although investigations of neuroprotection and neuroregeneration in glaucoma are advancing, unfortunately, it is still impossible to apply them in clinical practice.

As glaucoma is a multifactorial optic neuropathy, it is challenging to determine the target risk factor in gene therapy. The question arises whether a new field of modern science, which is already widely applied, can solve this challenge. The role of Big Data, Deep Learning, and Artificial Intelligence (AI) in medicine is still being sought. Can we build better health profiles and better predictive models around individual patients to diagnose better and treat the disease if we use that information? AI technology has evolved rapidly in recent decades. There is more and more talk about the role of AI in medicine. Ultimately, it still seems that AI cannot replace us as doctors. The doctor still manages the processes, and the AI serves us as a virtual assistant. I believe in humanity and the inability to replace the human factor, but I accept that new insights and information processing can help us significantly to improve the treatment of challenging multifactorial diseases such as glaucoma.

Until then, glaucoma is still treated using indirect neuroprotection through protecting the optic nerve by reducing risk factors. One of the most critical risk factors for the development of glaucoma is elevated intraocular pressure (IOP) (pressure above 22 mmHg). Glaucoma treatment should be individualized in selecting therapy tailored to the patient's individual needs (following the IOP targets). Elevated IOP can be decreased with drug therapy, laser procedures, or surgical techniques. It remains us to improve the medical treatment of glaucoma with improved drugs prescription, new ways of drugs application, and new antiglaucoma drugs. In laser treatment, new generations of more tissue-sparing and focused lasers are used, while in surgical treatment, new techniques are introduced that are less invasive and new microdevices that regulate intraocular pressure.

In the field of glaucoma, science is advancing significantly, and the disease is detected more accurately and earlier, and it is treated significantly more individually. Hopefully, it will no longer be called a disease that is the second leading cause of blindness in the future.

IS08**Orbital surgery: a conceptual approach**

Assistant Professor Jelena Juri Mandić, M.D., PhD

DOI: <https://doi.org/10.26800/LV-144-supl2-IS08>

*Department of Glaucoma, Orbital Diseases and Reconstructive Eye Surgery, Clinic for Eye Diseases, University Hospital Center Zagreb
School of Medicine, University of Zagreb*

Orbital surgery and even oculoplastic surgery are almost unknown concepts in the minds of medical students before the start of the Ophthalmology rounds. And yet, this is an unusually important segment of ophthalmology. Without eyelids, lacrimal system, extraocular muscles, and orbital neurovascular structures commonly named protective apparatus, there can be no normal visual and eye motility function. In other words, the protective apparatus of the eye is necessary to fulfill two fundamental functions of the ophthalmic apparatus: the function of sight and articular function; both of which allows us to see one perfect image with two eyes. Apart from its protective role, orbital cavity is a „home“ to many different pathological conditions related to systemic diseases e.g. thyroid associated orbitopathy, lymphoma, IgG 4 related disease, granulomatous polyangiitis, neurofibromatosis, sarcoidosis, rheumatoid arthritis, Sjogren syndrome etc. Some conditions require surgical along with conservative treatment. From the perspective of other branches of ophthalmology, orbital surgery is a hard core, bloody surgery which carries a burden not so often seen in ophthalmology. Visual loss and serious systemic complications are not unusual and must be properly managed. Orbital bony decompression is one, such procedure. There are several different surgical approaches combining one, two, three or four wall orbital fracturing. The basic principle is to relieve orbital compression and decrease orbital pressure to avoid ischemic damage of the optic nerve and other orbital structures. By fracturing orbital walls the surgeon allows “overflow” of excessive orbital tissues to adjacent intracranial spaces like paranasal sinuses and temporal fossa. The result is decreased orbital and intraocular pressure, remodeling of the orbital content and thus optic nerve and other orbital structures ischemic injury relief. Orbital bony decompression is most performed as an urgent procedure and can be a solution for any kind of orbital compressive and compartment syndrome regardless of etiology. In skillful hands it is a safe, quick, and effective procedure.


IS09**Differential diagnosis of vertigo**

Iva Kelava, M.D., PhD

DOI: <https://doi.org/10.26800/LV-144-supl2-IS09>

University Hospital Center Sestre Milosrdnice

Vertigo is an illusion of movement of the body or the environment. It is a symptom that can be caused by central (cerebrovascular insult (CVI), tumors, multiple sclerosis) or peripheral (Meniere disease, labyrinthitis, benign paroxysmal positional vertigo (BPPV)) origin. Vertigo is a common nonspecific complaint in patients attending the emergency department. Careful history taking and examination are required to distinguish vertigo from other nonrotational types of dizziness such as presyncope, disequilibrium and lightheadedness. Once we have determined that our patient suffers from vertigo it is important to differentiate if it is of central or peripheral origin. Central causes are suspected in patients with associated neurological symptoms such as one-sided muscle weakness, headache, dysarthria or confusion. Risk factors for vascular disease must also be taken into consideration. Peripheral vertigo is often associated with nausea and vomiting and in some cases with hearing loss (Meniere disease, labyrinthitis). Vertigo triggered by a change in the position of the head is often caused by BPPV or of cervicogenic origin. In conclusion, vertigo is a common symptom that is often caused by harmless conditions. However, serious diseases such as CVI must be excluded. Clinical history taking and physical examination is crucial in differential diagnosis of vertigo.



IS10**Bilateral Cochlear Implantation**

Andro Košec, M.D., PhD

DOI: <https://doi.org/10.26800/LV-144-supl2-IS10>

Department of Otorhinolaryngology and Head and Neck Surgery, University Hospital Center Sestre milosrdnice School of Medicine, University of Zagreb

As an introductory lecture of the Congress, the first few minutes will be dedicated to the history of Otorhinolaryngology in the Republic of Croatia and the people without whom this branch of medicine would look completely different. Cochlear implantation (CI) is the golden standard in the treatment of pediatric and adult patients suffering from bilateral severe-to-profound sensorineural hearing loss. The ultimate aim of any hearing restorative surgical intervention is to improve patient outcomes. The benefits of bilateral CI include binaural summation, squelch, equivalent head shadow for each ear, improved hearing in noise and sound localization ability. The downsides are prolonged surgical procedure time, additional cost, and the limited possibility to use future technologies in the implanted ear.

IS11**Voice disorders in children**

Assistant Professor Lana Kovač Bilić, M.D., PhD & Ivana Šimić, MA, speech therapist

DOI: <https://doi.org/10.26800/LV-144-supl2-IS11>

ENT University Clinic, University Hospital Center Zagreb

School of Medicine, University of Zagreb

Voice disorders are frequent in children, mostly associated with rhinopharyngitis and fastly resolved. Dysphonia which lasts for a long time requires detailed diagnostic procedures and specific treatment according to the etiology. If dysphonia is not recognized in time it can proceed to chronic dysphonia following communication disorders in a very sensitive school-age period. The management of dysphonic child requires multidisciplinary team composed of ORL/phoniatrician, speech therapist and psychologist. Our study included 120 patients from January 2018 to January 2020, 80 boys and 40 girls aged 4 -18 years. All the patients were examined by ORL/phoniatrician, speech therapist and psychologist and in all patients voice therapy was performed. Out of 120 patients with voice disorders 104 had acquired, functional voice disorder, and 16 had primary organic vocal cord lesion, comprising seven vocal cord cysts and nine juvenile laryngeal papillomatoses. In conclusion we can say that dysphonia is common in children. In diagnostic and treatment approaches it is obligatory to incorporate multidisciplinary team composed of ORL/phoniatrician, speech therapist and psychologist. The great majority of patients have acquired, functional disorder and require voice therapy while, in our experience, surgical approach is necessary only in 13% of patients.



IS12**Auditory neuroelectronic interfaces**

Assistant Professor Damir Kovačić, PhD

DOI: <https://doi.org/10.26800/LV-144-supl2-IS12>*Laboratory for Biophysics and Medical Neuroelectronics, Department of Physics, Faculty of Science, University of Split*

Auditory neuroelectronic interfaces represent a branch of medical bionics, a rapidly growing research and technology field that can effectively connect electronic systems such as computer chips with nervous systems. The two most successful examples of such interfaces are the cochlear implant (CI) and the auditory brainstem implant (ABI), which allow direct stimulation of the auditory nerve and the cochlear nucleus in the brainstem. These devices may evoke partial hearing and even establish full-fledged auditory communication in a completely deaf person. Nevertheless, today's fundamental limitations of non-selectivity and widespread electrical stimulation lead to considerable variability in the success of the implants.

We intend to “attack” this fundamental limitation using high-dense microelectrode arrays and nanostructured materials, such as graphene and hBN, which possess a whole range of intriguing physical and chemical properties, theoretically enabling this full integration and intimate interaction with the neural tissue. In particular, we are assessing the suitability of graphene and hBN for in-vitro growth of cell cultures of spiral ganglion neurons (SGN). Furthermore, to evaluate the quality of the auditory neuro-electronic interface, parametrization of the biomedical protocol for in-vitro culturing of auditory neurons is necessary, and the identification of design specifications of graphene and hBN to be used as stimulation and recording platform.

In this talk, I will first overview the state-of-the-art auditory neuroelectronic interfaces and present the morphological analyses of in-vitro SGN cultures extracted from neonatal rat pups and grown on graphene and h-BN substrates previously coated with poly-L-ornithine and laminin. The cultures were immunocytochemically stained at seven days in vitro (7DIV), and the subsequent fluorescence images were analyzed with the custom-made machine learning-based image processing allowing successful segmentation and classification of neurons. Neurons were examined for various morphological properties, including cell density, neurite length, and cell dispersion as a measure of cellular clusterization.

IS13**Artificial intelligence in recognition of retinal conditions; Pros and Cons**

Marko Lukić, M.D., PhD

DOI: <https://doi.org/10.26800/LV-144-supl2-IS13>*Moorfields Eye Hospital NHS Foundation Trust London, United Kingdom*

Artificial intelligence in ophthalmology has been emerging over the last decade. The current theoretical knowledge and technical abilities led to development of artificial intelligence-based systems able to recognise different retinal conditions based on colour fundus photographs or optical coherence tomography scans. Our collaborative research group applied a novel deep learning architecture to a clinically heterogeneous set of three-dimensional optical coherence tomography scans. The group demonstrated a performance in making a referral recommendation that reaches or exceeds that of experts on a range of sight-threatening retinal diseases after training on only 14,884 scans. Moreover, we demonstrate that the tissue segmentations produced by our architecture act as a device-independent representation; referral accuracy is maintained when using tissue segmentations from a different type of device. Our work removes previous barriers to wider clinical use without prohibitive training data requirements across multiple pathologies in a real-world setting. Furthermore, for conversion from dry to exudative form of age-related macular degeneration, our deep learning-based system combines prediction models on both 3D optical coherence tomography images and their corresponding automatic tissue maps generated by a segmentation network. The system predicts conversion within a clinically actionable time window of 6 months. We achieve a per-scan sensitivity of 80% at 55% specificity, and 34% sensitivity at 90% specificity. Nowadays, the current AI models shown a significant improvement in accuracy. However, there are a few main questions which should be considered; whether the current accuracy is sufficient to implement the AI based systems in real-life clinical practices and what may be medico-legal implications of using AI based systems in standard care of patients.

IS14**Auricular reconstruction-concepts and techniques in microtia, revisional and other complex cases**

Assistant Professor Ivan Rašić, M.D., PhD

DOI: <https://doi.org/10.26800/LV-144-supl2-IS14>

Department of Otorhinolaryngology and Head and Neck Surgery, University Hospital Center Sestre milosrdnice School of Medicine, University of Zagreb

The construction of an auricle from autologous tissue is highly complex and demanding. Depending on the underlying malformation, there are various surgical techniques available. Thanks to our enthusiasm and acquaintance with leading experts in the field of ear reconstruction; Professor Siegert and Dr. Magritz, in the beginning of 2016, we began to use their technique in Croatia, a first in Southeast Europe. We are honored to have done the first two procedures with Dr. Magritz and that he has helped us countless times later with his advice. The first stage consists of fabrication of a three-dimensional costal cartilage framework. The second stage is performed 5-6 months later: the reconstructed ear is raised up and an additional cartilaginous graft is used to increase its projection. A mastoid fascial flap together with a full thickness skin graft protects the cartilage graft.


In some cases there is a need for temporoparietal fascia flap (TPF flap) or even free flap. This surgery is very demanding, artistic and always a little bit surprising what makes this job perfect.



ABSTRACTS

Basic Science

BS01

Natural flavonols of plant origin as novel carbon monoxide releasing moleculesSriram Balasubramani^a, Panshul Mehta^a, Dafni Vlachopoulou^a, Lucie Muchová^a^a *Institute of Medical Biochemistry and Laboratory Diagnostics; General University Hospital; First Faculty of Medicine of Charles University Prague*DOI: <https://doi.org/10.26800/LV-144-supl2-BS01> Sriram Balasubramani 0000-0002-9886-9358, Panshul Mehta 0000-0003-2707-2197, Dafni Vlachopoulou 0000-0002-8999-9257, Lucie Muchová 0000-0003-2082-1060

Keywords: CO release, Dehydrosilybin, natural flavonols, Quercetin


INTRODUCTION: Carbon monoxide (CO) is a gasotransmitter studied for its potential therapeutic applications. Photoactivatable CO releasing molecules (photoCORMs) including synthetic flavone scaffold-containing molecules are used to deliver CO to the target cells and tissues. Naturally occurring flavonoids of plant origin are an important part of a human diet with beneficial effects on many physiological processes, however, whether they are capable of CO release upon photoexcitation is unknown. Our objective was to investigate the ability to release CO from synthetic and natural flavonoids after photoexcitation and its biological consequences.

METHODS: HepG2 and HepaRG cell lines were used to measure cytotoxicity of synthetic flavonol, quercetin and dehydrosilybin with/without white light-irradiation using MTT assay. CO release was quantitated by GC-RGA. Biological effects of CO release were studied by Western blotting (β -catenin, β -actin), GC/MS (Krebs cycle intermediates) and FACS (cell cycle).

RESULTS: Quercetin and dehydrosilybin release CO upon white light irradiation with different rates-dehydrosilybin fastest, followed by synthetic flavonol and quercetin at concentrations of 400 μ M. CO release from synthetic flavonol significantly decreased cell metabolism, β -catenin protein expression and slowed cell cycle progression. All flavonols show significant toxicity at concentrations of 400 μ M upon white light irradiation.

CONCLUSION: We discovered that natural flavonols quercetin and dehydrosilybin are effective photoCORMs with dehydrosilybin as most potent CO releaser. CO production from flavonols affects cell metabolism and proliferation which might contribute to an anti-cancer effect of these molecules.

BS02

DIPEPTIDYL-PEPTIDASE IV (DPP IV/CD26) AFFECTS THE WOUND HEALING PROCESS IN A STREPTOZOTOCIN-INDUCED DIABETES MODEL IN MICELara Batičić^a, Dijana Detel^a, Edvard Bedoić^b, Jadranka Varljen^a^a *Department of Medical Chemistry, Biochemistry and Clinical Chemistry, Faculty of Medicine, University of Rijeka*^b *School of Medicine, University of Rijeka*DOI: <https://doi.org/10.26800/LV-144-supl2-BS02> Lara Batičić 0000-0002-2837-4157, Dijana Detel 0000-0001-8986-0880, Edvard Bedoić 0000-0002-9307-6033, Jadranka Varljen 0000-0002-2837-4157

Keywords: diabetes mellitus, DPP IV/CD26, hyperglycemia, wound healing

INTRODUCTION/OBJECTIVES: Diabetes mellitus is a metabolic disorder with multiple etiology, characterised by chronic hyperglycemia with disturbances of metabolism of carbohydrates, fats and proteins. It results from defects in insulin secretion, action or both. Dipeptidyl-peptidase IV/CD26 (DPP IV/CD26) molecule is known to be involved in an array of physiological and pathological processes, in the regulation of glycaemia as well. A variety of complications caused by diabetes can cause hospitalizations. DPP IV/CD26 inhibitors can be used to treat diabetes mellitus. The aim of this research was to investigate the processes of wound healing in conditions of CD26 deficiency in experimental hyperglycaemia.

MATERIALS AND METHODS: In this experiment two strains of mice were used, wild type and CD26-deficient mice. Experimental diabetes was induced using a solution of streptozotocine in citrate buffer (50mg/kg, i.p.) during five days. Serum samples as well as pancreas, cutaneous (control) tissue and wound tissue were analyzed. Pathohistological, immunohistochemical and immunobiochemical analyses were performed on wound samples and control skin. Serum samples were analysed for DPP IV/CD26 activity and concentration of target angiogenic factors.

RESULTS: Results of this study revealed that DPP IV/CD26 has an important role in the regulation of blood glucose concentration. Inactivation of DPP IV/CD26 improves the state associated with hyperglycemia. The process of cutaneous wound healing is improved in conditions of CD26 deficiency.


CONCLUSION: The inhibition of DPP IV/CD26 has positive effects on the wound healing process in hyperglycemia. DPP IV/CD26 inhibition can be suggested as a therapeutic option for treatment of diabetes mellitus and its complications like delayed wound healing.

BS03**Effects of Pentadecapeptide BPC 157 on Ulcer, Intracranial, Portal and Caval Hypertension and Aortal Hypotension after Stomach Perforation**

Luka Kalogjera^a, Lea Klepač^a, Hrvoje Vraneš^a, Vilim Dretar^a, Ivan Maria Smoday^a, Luka Ćorić^a, Katarina Oroz^a

^a Department of Pharmacology; School of Medicine, University of Zagreb

DOI: <https://doi.org/10.26800/LV-144-supl2-BS03>

 Luka Kalogjera 0000-0002-1703-0033, Lea Klepač 0000-0002-6801-9715, Hrvoje Vraneš 0000-0003-3544-8385, Vilim Dretar 0000-0002-3969-712X, Ivan Maria Smoday 0000-0002-4416-7262, Luka Ćorić 0000-0002-1965-9660, Katarina Oroz 0000-0002-4861-9529

Keywords: BPC 157, hypertension, pharmacology, stomach perforation

INTRODUCTION/OBJECTIVES: **INTRODUCTION:** We report that rat stomach perforation (surgery with 5-mm diameter metal needle on the ventral side in the prepyloric area) induced a defect that would not heal. Stomach perforation rapidly induced the hypertension in superior sagittal sinus, portal and caval hypertension and aortal hypotension. Previously, stable gastric pentadecapeptide BPC 157 largely diminished or even eliminated the consequences of Budd-Chiari syndrome in rats (portal and caval hypertension and aortal hypotension). Now, we will examine of BPC 157 on Ulcer and blood pressures in vessels after Stomach Perforation.

MATERIALS AND METHODS: **MATERIALS AND METHODS:** rats were anesthetized, laparotomy and stomach perforation were performed. Animals were divided into treated and control groups. Treated rats received BPC 157 treatment (10 µg/kg, 10 ng/kg 1mL) intragastrically at 1 min after stomach perforation and rats in control group received 1mL saline. At 5 min after stomach perforation, recordings of the blood pressure were made in anesthetized and laparatomized rats. We recorded pressures in sinus sagittalis superior, portal vein, inferior vena cava and abdominal aorta pressure.

RESULTS: **RESULTS:** Without therapy, in control groups, intracranial hypertension, portal and caval hypertension and aortal hypotension occurred rapidly. Both BPC 157 regimens counteracted intracranial hypertension, portal and caval hypertension and aortal hypotension. Finally, BPC 157 completely healed stomach defect.


CONCLUSION: **CONCLUSION:** BPC 157 showed anti-ulcer effect and also opposed the intracranial hypertension, portal and caval hypertension and aortal hypotension in groups of treated animals.

BS04**Histological Aspect of Pentadecapeptide BPC 157 Therapeutic Effects on Early and Definitive Spinal Cord Injury**

Katarina Oroz^a, Ivan Maria Smoday^a, Luka Kalogjera^a, Luka Ćorić^a, Hrvoje Vraneš^a, Leon Palac^a, Mislav Pečnik^a

^a Department of Pharmacology; School of Medicine, University of Zagreb

DOI: <https://doi.org/10.26800/LV-144-supl2-BS04>

 Katarina Oroz 0000-0002-4861-9529, Ivan Maria Smoday 0000-0002-4416-7262, Luka Kalogjera 0000-0002-1703-0033, Luka Ćorić 0000-0002-1965-9660, Hrvoje Vraneš 0000-0003-3544-8385, Leon Palac 0000-0002-2666-5911, Mislav Pečnik 0000-0003-1975-3152

Keywords: BPC 157, pharmacology, spinal cord injury

INTRODUCTION/OBJECTIVES: This study aimed to show an immediate effect on the histological level of the stable gastric pentadecapeptide BPC 157 therapy which was applied in rats with acute spinal cord injury as well as in the rats with definitive spinal cord injury.

MATERIALS AND METHODS: A compressive injury was made with a neurosurgical piston in Wistar rats subjected to laminectomy at lumbar level L2-L3. Injection of either saline (1mL) or BPC 157 (2 µg/kg 1mL) was intraperitoneally administered at 10 minutes post-injury (acute injury) or 4 days post-injury (definite injury). Animals were sacrificed 20 minutes after treatment. A 10-mm long piece of the spinal column was collected from each sacrificed animal and fixed, decalcinated, and embedded in paraffin. Serial cross-sections were stained with haematoxylin/eosin and toluidine blue. Samples were analysed under light microscopy. Pathological changes were scored appropriately.

RESULTS: At 10 minutes after injury, a haemorrhagic zone is present over grey and white matter. 20 minutes after saline administration (30 minutes post-injury) massive haemorrhage and oedema are present in the control group. Contrary, BPC 157 treated group have discrete oedema and minimal haemorrhage. On day 4, there is a large haemorrhagic zone, massive oedema, and vacuolation of tissue matter in control rats. Contrarily, in BPC 157 rats there is only mild haemorrhage and discrete vacuolation of tissue matter.


CONCLUSION: BPC 157, applied early as well as postponed, has a beneficial effect in the recovery of spinal cord injury. Histologically seen, it reduces haemorrhage, oedema, and vacuolation of tissue matter.

BS05**Ketamine, relation to the NO-system and BPC157**

Ivan Maria Smoday^a, Hrvoje Vranes^a, Katarina Oroz^a, Luka Ćorić^a, Luka Kalogjera^a, Mislav Pečnik^a, Vilim Dretar^a

^a Department of Pharmacology; School of Medicine, University of Zagreb

DOI: <https://doi.org/10.26800/LV-144-supl2-BS05>

 Ivan Maria Smoday 0000-0002-4416-7262, Hrvoje Vranes 0000-0003-3544-8385, Katarina Oroz 0000-0002-4861-9529, Luka Ćorić 0000-0002-1965-9660, Luka Kalogjera 0000-0002-1703-0033, Mislav Pečnik 0000-0003-1975-3152, Vilim Dretar 0000-0002-3969-712X

Keywords: BPC157, ketamine, Pharmacotherapy, Schizophrenia

INTRODUCTION/OBJECTIVES: Ketamine is a NMDAR antagonist and can be used in rats for modelling “negative-like” behaviour symptoms resembling those in schizophrenia. NMDARs function is linked with the NO-system. Modulating the NO-system with L-Arginine and L-NAME while antagonizing NMDAR could give insight on the potential treatment points of negative symptoms in schizophrenia. Stable gastric pentadecapeptide BPC 157 (Body protecting compound 157) has shown NO-system-modulating and dopamine modulating effects. We explored ketamine induced “negative-like” symptoms and the effects on BPC 157 on them.

MATERIALS AND METHODS: Male Wistar rats (200-250g, 12 weeks old) were used for the investigation. Ketamine was given intraperitoneally and dosed depending on the symptom investigated: 3mg/kg caused cognitive dysfunction, 30mg/kg caused anxiogenic effects and anhedonia, 8mg/kg for 3 days caused social withdrawal. Cognitive dysfunction was estimated with novel object recognition test, anxiogenic effects with open field test, anhedonia with sucrose test and social withdrawal with Koros test. L-NAME (5mg/kg), L-Arginine (100mg/kg) and BPC 157 (0.01mg/kg), were given alone or in combination, immediately after ketamine administration.

RESULTS: L-NAME and L-Arginine antagonized each other's activity when given together in the novel recognition test, which indicated that ketamine induced cognitive dysfunction is significantly NO- related. They didn't antagonize each other in ketamine induced social withdrawal, anhedonia, while they both had anxiogenic effects which indicate these effects are less NO-related. BPC 157 alone antagonizes cognitive dysfunction (by modulating the NO-system), social withdrawal, and anhedonia but promotes anxiolytic effects.

CONCLUSION: Further research will tell how BPC 157 modulates social withdrawal and anhedonia. Anxiolytic effects were described in previous investigations.

BS06**Synthesis and evaluation of biased agonists of immunometabolic receptor GPR84: a new class of immune cell modulators**

Vanessa Rogga^a, Pinqi Wang^b, Vincent Luscombe^c, Angela Russell^{b,d}


^a Faculty of Pharmacy and Biochemistry, University of Zagreb

^b Department of Chemistry, University of Oxford, United Kingdom

^c Sir William Dunn School of Pathology, University of Oxford, United Kingdom

^d Department of Pharmacology, University of Oxford, United Kingdom

DOI: <https://doi.org/10.26800/LV-144-supl2-BS06>

 Vanessa Rogga 0000-0002-2683-114X, Vincent Luscombe 0000-0002-2886-4017, Angela Russell 0000-0003-3610-9369

Keywords: GPR84, immunometabolism, ligand-based design, structure-activity relationship, synthesis

GPR84 (G protein-coupled receptor 84) is a G_{ai}-protein-coupled proinflammatory receptor that is mainly expressed on the innate immune system cells. DL-175 is a highly biased agonist of GPR84 which activates G_{ai} signaling pathways, with very low β -arrestin recruitment in cellular-based assays. This is coupled to low chemotaxis and high phagocytosis induction in macrophage functional assays (Lucy *et al*, 2019.). The purpose of this study is to investigate how the size of an attached hydrophobic moiety on DL-175 analogs correlates with activity and the potential improvement of metabolic stability compared to DL-175 when adding a fluorine atom which is a known xenobiotics metabolism blocker. We have designed, synthesized, and evaluated new potential GPR84 biased agonists: DL-175 analogs with variations on the linker and head part. Compounds VVR-014, VVR-016, VVR-018, and VVR-019 have been synthesized, characterized by Mass Spectrometry and Nuclear Magnetic Resonance, and evaluated in intracellular cAMP assays. VVR-016 and VVR-018 are inactive, VVR-014 has low activity ($EC_{50} > 10 \mu\text{M}$) and VVR-019 has modest activity (3.99 μM) in intracellular cAMP assays. VVR-014 activity in cellular cAMP assays suggests that its binding site has amino acids with larger hydrophobic residues leaving less space for a hydrophobic moiety on the compound. VVR-016 and VVR-018 inactivity suggests that pyridyl N-oxide hydrogen bond acceptor properties could be crucial for DL-175 activity. VVR-019 activity can be attributed to the smaller and less electron-dense tail group than DL-175 which suggests that a significant π - π interaction is happening in this part of the binding site.

BS07**The effect of chronic oral d-galactose administration on colon redox homeostasis in a rat model of sporadic Alzheimer's disease**Mihovil Joja^a, Jan Homolak^a, Melita Šalković-Petrišić^a^a Department of Pharmacology, University of Zagreb, School of MedicineDOI: <https://doi.org/10.26800/LV-144-supl2-BS07> Mihovil Joja 0000-0002-9177-7557, Jan Homolak 0000-0003-1508-3243, Melita Šalković-Petrišić 0000-0003-1865-7142


Keywords: Alzheimer's disease, colon, galactose, redox, streptozotocin

INTRODUCTION/OBJECTIVES: Parenteral administration of d-galactose is commonly used to model aging in rodents. Cognitive deficit observed in the model is explained by d-galactose induced oxidative stress. Conversely, chronic oral administration of d-galactose prevented cognitive deficit in the streptozotocin-induced rat model of Alzheimer's disease (STZ-icv). Hence, the study aims to assess the effect of chronic oral d-galactose on redox homeostasis in the colon of STZ-icv and control rats.

MATERIALS AND METHODS: Three-month-old male Wistar rats (N=40) were split into two groups treated bilaterally by intracerebroventricular injection of either streptozotocin (STZ-icv, 3 mg/kg) or vehicle (CTR). Animals were further assigned into a group receiving daily oral galactose solution (200 mg/kg) or vehicle (tap water). After two months, rats were euthanized and colons (N=20) dissected and stored at -80°C for further analysis. Total antioxidant capacity (TAC) was evaluated by nitrocellulose redox permanganometry (NRP) and ABTS. Lipid peroxidation was assessed by thiobarbituric acid reactive substances (TBARS), catalase activity was assessed indirectly by quantification of the carbonato-cobaltate (III) complex, low molecular weight thiols (LMWT) and total protein sulfhydryls (SH) were measured with 5,5'-dithio-bis(2-nitrobenzoate).

RESULTS: STZ-icv group had a higher concentration of LMWT and lower TBARS compared to the control group. D-galactose treatment increased LMWT, decreased TBARS and catalase activity in both STZ-icv and CTR groups. Colon TAC and SH levels were decreased only in the galactose-treated STZ-icv group.

CONCLUSION: Colon redox homeostasis is altered in the STZ-icv rat model. Chronic oral d-galactose may exert beneficial effects by shifting redox homeostasis toward a more reductive/antioxidant state.

BS08**Stable Gastric Pentadecapeptide BPC 157 Counteracting Effects on Postsplenectomy Complications in Rats**Luka Ćorić^a, Katarina Oroz^a, Hrvoje Vraneš^a, Mislav Pečnik^a, Tajana Đurašin^a, Ivan Maria Smoday^a, Vilim Dretar^a^a Department of Pharmacology, School of Medicine, University of ZagrebDOI: <https://doi.org/10.26800/LV-144-supl2-BS08> Luka Ćorić 0000-0002-1965-9660, Katarina Oroz 0000-0002-4861-9529, Hrvoje Vraneš 0000-0003-3544-8385, Mislav Pečnik 0000-0003-1975-3152, Tajana Đurašin 0000-0002-6893-0875, Ivan Maria Smoday 0000-0002-4416-7262, Vilim Dretar 0000-0002-3969-712X

Keywords: BPC 157, Postsplenectomy complications, Splenectomy, Thrombosis

INTRODUCTION/OBJECTIVES: We focused on Stable gastric pentadecapeptide BPC 157 counteracting effects on complications taking place after splenectomy in rats, including portal vein, superior mesenteric vein, lienal vein and inferior vena cava thrombosis, severe venous hypertension, abdominal aorta hypotension, liver damage and subsequent cerebral edema.

MATERIALS AND METHODS: Wistar rats were deeply anaesthetized and underwent complete laparotomy followed by splenectomy. Immediately after splenectomy, portal vein was clamped using a vascular clamp for 15 minutes to induce thrombosis of portal vein and its tributaries. Medication (BPC 157 (10 µg/kg) (treated group) or saline (5 mL) (control group)) was applied as an abdominal bath immediately after the vascular clamp removal. Rats' vessels, organs and brains were filmed 10 minutes and 24 hours after medication application using USB microcamera. Furthermore, blood pressure was measured via intravascular cannulation and thrombi were extracted and weighed. Using ImageJ software and with our knowledge of Square-cube law, we were able to express relative brain volumes and then graphically display data.


RESULTS: Blood pressure values (portal vein and inferior vena cava hypertension and aortic hypotension) showed significant differences between control and treated groups already after 10 minutes and those differences became even more distinct after 24 hours. Similar pattern is seen with thrombosis, therefore BPC 157 treated rats showed reduced thrombi weights. Macroscopically, control group presented with portal vein congestion and thrombosis, liver congestion and damage and cerebral edema, whereas the treated group showed none of the above.

CONCLUSION: These findings suggest that BPC 157 may be therapeutic solution for postsplenectomy portal venous system thrombosis.

ABSTRACTS

Case Reports

CR01

A 14-year old girl with abdominal pain and inability to urinate– case report of imperforate hymenAnte Blažević^a, Marija Vukojević^a, Ante Vuković^a, Egon Kruezi^b^a School of Medicine, University of Zagreb^b Department of Gynecology and Obstetrics; University Hospital Center “Sestre Milosrdnice”; Zagreb, CroatiaDOI: <https://doi.org/10.26800/LV-144-supl2-CR01> Ante Blažević 0000-0003-2128-5933, Marija Vukojević 0000-0003-0355-8141, Ante Vuković 0000-0002-5792-2765, Egon Kruezi 0000-0002-4801-8037


Keywords: Hematocolpos, Imperforate hymen, Pediatric Abdominal Pain

INTRODUCTION/OBJECTIVES: Imperforate hymen is a congenital malformation in the female reproductive system that gives rise to obstructive symptoms. Condition is caused due to the organ's failure to perforate during embryologic development. Symptoms often arise at menarche since diagnosis is not usually made in newborn girls. The patients can present with cyclic abdominal pain, back pain, painful urination, and constipation. Standard treatment includes hymenectomy, a surgical procedure that creates an opening in the hymen.

CASE PRESENTATION: We present you with a case of a 14-year old girl who came to the hospital on January 17th due to severe lower abdominal pain and inability to urinate. Gynecological examination revealed hymen without aperture. Transabdominal ultrasound showed a dilated vagina with hemorrhagic content (hematocolpos), 70x70 mm. There was 1100 mL of urine evacuated after catheterization. Minimally invasive surgical treatment was indicated and scheduled on the same day. The incision was made following dilatation with Hegars dilator. The leakage of hematized content was later observed. A Foley catheter in the bladder was placed. Few hemostatic sutures were set, preventing postoperative bleeding and re-closure of the vagina. Additionally, antibiotic prophylaxis and peroral analgesics were administered. The patient was released from the hospital two days later. On a regular check-up two weeks later, the patient did not report any symptoms and recovered well.

CONCLUSION: Imperforate hymen is a rare condition that can easily be overlooked or misdiagnosed. Therefore, it should be suspected in adolescent girls with abdominal pain, lower back pain, or urinary retention.

CR02

A case of an unilateral sensorineural hearing-loss after SARS CoV-2 infection in a 8-year-old boyAndrija Nekić^a, Lucija Lučev^a, Lana Kovač Bilić^b^a School of Medicine University of Zagreb^b School of Medicine University of Zagreb, Department of Otorhinolaryngology, Head and Neck Surgery, Zagreb University Hospital Centre, Zagreb, CroatiaDOI: <https://doi.org/10.26800/LV-144-supl2-CR02> Andrija Nekić 0000-0003-1214-8646, Lucija Lučev 0000-0003-0247-099X, Lana Kovač Bilić 0000-0003-2526-226

Keywords: Coronavirus, COVID-19, Hearing loss, Otolgic symptoms, SARS-CoV-2

INTRODUCTION/OBJECTIVES: Up to 30% of adult patients affected by COVID-19 have neurological manifestations. If the affected area is the inner ear, sensorineural hearing loss is the most common clinical presentation.

CASE PRESENTATION: We present a case of a previously healthy 8-year-old boy administered 20 days after asymptomatic SARS-CoV-2 infection reporting hearing loss in his left ear. The external auditory canal and the tympanic membrane were both otoscopically without any pathological signs as effusion or inflammation. The tympanogram was of the type A in both ears. The Weber test showed lateralization in the right ear, showing that the hearing loss was of the sensorineural type. This finding was further confirmed with the tonal audiogram in which the right ear was with normal hearing threshold, and the left had the hearing threshold of 35 dB at three consecutive frequencies. Furthermore, the acoustic reflex was elicited ipsilaterally and contralaterally in the right ear, whereas in the left ear it was elicited contralaterally but not ipsilaterally. This test also confirmed that the damage was in the sensorineural pathway. The prescribed therapy was oral glucocorticoids during the course of 7 days with progressive daily dosage reduction (methylprednisolone 32mg, 32mg, 16mg, 16mg, 8mg, 4mg, 4mg) accompanied with proton pump inhibitors during 14 days (esomeprazole). After four weeks at the control checkup the boy showed full clinical recovery, with normal hearing in both ears confirmed by tonal audiogram.

CONCLUSION: This case demonstrates that non-pulmonary sensorineural symptoms can also occur in pediatric patients as a result of COVID-19.


CR03**A rare case of a hemorrhagic renal angiomyolipoma during pregnancy: a case report**Marko Belošević^a, Natalia Pappo^a, Maja Banović^b^a School of Medicine, University of Zagreb^b Department of Obstetrics and Gynecology, University Hospital Centre ZagrebDOI: <https://doi.org/10.26800/LV-144-supl2-CR03> Marko Belošević, Natalia Pappo 0000-0002-9667-7782, Maja Banović

Keywords: angiomyolipoma, nephrectomy, pregnancy, tuberous sclerosis

INTRODUCTION/OBJECTIVES: Renal angiomyolipoma is a benign tumor that occurs sporadically or is associated with tuberous sclerosis. Due to hormone sensitivity, this tumor tends to grow more rapidly during pregnancy.

CASE PRESENTATION: A 31-year-old woman at 35 weeks of gestation presented to the emergency department with nausea and pain in the left lumbar region radiating to the groin. Her medical history was significant for tuberous sclerosis and several spontaneous pneumothoraces. Laboratory tests showed anemia and leukocytosis. Ultrasonography revealed a mass adjacent to the uterus measuring 15 × 9 cm with mixed echogenicity, suggestive of a retroperitoneal tumor. As the patient's condition worsened, she underwent an emergency cesarean section and the delivery of a 2077g male neonate. Subsequently, she underwent exploration of the retroperitoneal space. A hemorrhagic renal tumor was found and removed, and a left nephrectomy was performed. A pathohistological analysis of a tumor sample confirmed a diagnosis of angiomyolipoma. Post-operative course was uneventful. On follow up, the patient was diagnosed with renal insufficiency, multiple right renal angiomyolipomas and lymphangiomyomatosis. After birth, the male neonate was bradycardic and was not breathing spontaneously. He had an Apgar score of 4/6. Resuscitation was successful. MRI showed signs of perinatal hypoxic-ischemic brain injury, and he was later diagnosed with developmental delay.

CONCLUSION: Hemorrhagic renal angiomyolipoma during pregnancy is a rare and life-threatening condition. This case describes simultaneous cesarean section and nephrectomy in a pregnant woman with tuberous sclerosis. Women with a history of tuberous sclerosis should be examined more extensively during pregnancy. Angiomyolipomas should be kept in mind.

CR04**Acute kidney injury as a result of hypovolaemia and excessive potassium intake**Kristijan Harak^a, Marin Glavčić^b, Marinko Grgić^c^a Health Centre of Zagreb County^b Institute for Emergency Medicine of Split-Dalmatia County^c Health Centre of Varaždin CountyDOI: <https://doi.org/10.26800/LV-144-supl2-CR04> Kristijan Harak 0000-0002-1501-1955, Marin Glavčić 0000-0002-9065-40103, Marinko Grgić 0000-0003-2402-7147

Keywords: acute kidney injury, fatigue, hypovolaemia, itch, potassium

INTRODUCTION/OBJECTIVES: Acute kidney injury is characterized by decreased urine production and fluid and electrolyte imbalance occurring over hours or days. The underlying aetiology is generally classified as prerenal, renal and postrenal. The commonest causes of AKI are sepsis, cardiogenic shock, drugs and major surgeries.

CASE PRESENTATION: We discuss the case of a 92-year-old female patient who came to the general practice complaining of generalised itch and fatigue. The patient began experiencing symptoms two weeks prior to admission. Past medical history showed arterial hypertension for which the patient was taking calcium channel blocker and loop diuretic with potassium in the lowest dose, COPD, atopic dermatitis and heart failure (HfpEF) for which the patient was taking digoxin. Physical examination showed no gross abnormalities. The vital signs were stable. Laboratory tests showed rise in serum creatinine, urea (3 times higher) and potassium (6,3 mmol/L). After contacting the patient's family, it was determined that the patient was not taking potassium pills, which further complicated the diagnostic process. It was later discovered that the patient was taking only 200 mL of water and eating 4-5 bananas a day. The patient was treated with IV fluids. Following 7 days of therapy, the generalised itch was markedly reduced and renal laboratory parameters were in decline.

CONCLUSION: This case report shows that a detailed auto- and heteroanamnesis must be taken and less likely causes should not be ruled out as a potential trigger of the acute kidney injury.

CR05**An atypical case of pleural empyema**


Sandra Knežević^a, Ana-Marija Petani^b, Lucija Kučina^a,
Maša Kopušar^a, Ivana Žitinić^{a,c}

^a Faculty of Medicine, University of Rijeka

^b School of Medicine, University of Zagreb

^c Emergency medicine, Clinical Hospital Rijeka

DOI: <https://doi.org/10.26800/LV-144-supl2-CR05>

 Sandra Knežević 0000-0003-4863-1963, Ana-Marija Petani 0000-0001-9421-4867, Lucija Kučina 0000-0002-1250-2388, Maša Kopušar 0000-0001-5910-9826, Ivana Žitinić 0000-0002-8630-5424

Keywords: Dyspnea, Lung Neoplasm, Pleural Effusion, Pleural Empyema, Thoracentesis

INTRODUCTION/OBJECTIVES: An empyema is a collection of pus in the pleural space presenting with fever, cough and chest pain. It often occurs as a complication of pneumonia, but it can also occur after lung surgery, following a chest trauma etc.

CASE PRESENTATION: An 83-year-old woman presented to the Emergency Department (ED) with progressive dyspnea that lasted 6 days prior to admission. She had no fever and no chest pain. Auscultation of the right lung revealed inaudible breath sounds up to the scapula. Blood tests revealed severe leucocytosis [32.9 x 10⁹ cells/L] and C-reactive protein [477.7 mg/L] and respiratory acidosis. Due to the findings, an empiric antibiotic therapy was started, while looking for the primary site of infection. Chest X-ray showed a large left pleural effusion, which could fit in the picture of the patients' medical history of right-sided lung cancer, consequently a radiation-induced pleuritis, atrial fibrillation and a bilateral mastectomy due to breast cancer. Even though non-invasive positive-pressure ventilation was started upon admission, the patient became respiratory threatened, so thoracentesis was performed in ED. Surprisingly, 960 mL of foul-smelling, thick, purulent exudate was drained. Microbiological analysis of the aspirate came positive for *Enterococcus faecalis* and *Streptococcus constellatus*, which confirmed the diagnosis of pleural empyema. Although thoracentesis eased the symptoms, the patient developed pneumothorax and was admitted to the ICU where chest tube thoracic drainage was performed.

CONCLUSION: This case showed the significance of thoracentesis as a diagnostic tool, as well as its therapeutic role. Nevertheless, clinicians need to be familiar with its potential procedural complications.

CR06**An unusual case of hand, foot, and mouth disease in a 35-year old immunocompetent male**

Marin Glavčić^a, Kristijan Harak^b, Marinko Grgić^c, Ivona Čudina^d


^a Institute for Emergency Medicine of Split-Dalmatia County

^b Health Centre of Zagreb County

^c Health Centre of Varaždin County

^d Health Centre of Zagreb - Center

DOI: <https://doi.org/10.26800/LV-144-supl2-CR06>


 Marin Glavčić 0000-0002-9065-4010, Kristijan Harak 0000-0002-1501-1955, Marinko Grgić 0000-0003-2402-7147, Ivona Čudina 0000-0001-9640-4533

Keywords: Childhood disease, Coxsackievirus, Emergency medicine, Enterovirus, Infectology.

INTRODUCTION/OBJECTIVES: Hand, foot, and mouth disease (HFMD) is a highly contagious illness caused by coxsackievirus strain A16 and enterovirus 71 that mostly affects children under the age of five. Adults are significantly less likely to get hand, foot and mouth disease, which commonly manifests as unusual skin lesions accompanied by high fever, headache, and sore throat.

CASE PRESENTATION: We discuss the case of a 35-year-old immunocompetent man who came to the emergency room complaining of multiple painful papules and vesicles on his hands, feet, and lips. The oral cavity of the patient did not have any blisters. The patient complained of tingling sensations in the areas where the rash appeared. According to the patient's medical history, the patient had a temperature of 37.5 degrees Celsius three days before the rash emerged. Further patient history revealed that his child had a fever and diarrhoea four days before the patient developed a fever. The patient's child most likely had an unspecific case of hand, foot, and mouth disease and consequently infected the father.

CONCLUSION: Since hand, foot, and mouth disease is highly contagious, it is important to recognise that the disease can occur in immunocompetent adults in order to contain the infection. Also, despite the fact that all childhood diseases are more common in children than in adults, they should not be ruled out when making the differential diagnosis.


CR07**Application of alteplase (in a life saving situation) despite absolute contraindication.**Grga Roglić^a, Ivica Premužić Meštrović^b^a School of Medicine University of Zagreb^b Department of Cardiology, Division of electrophysiology, Clinical Hospital MerkurDOI: <https://doi.org/10.26800/LV-144-supl2-CR07> Grga Roglić 0000-0003-0445-044X, Ivica Premužić Meštrović 0000-0002-2592-8302

Keywords: Alteplase, cardiology, contraindication, pulmonary embolism.

INTRODUCTION/OBJECTIVES: Acute massive pulmonary embolism (PE) with right-sided heart failure and hemodynamic instability is an emergency with high mortality rate. Rapid diagnosis and early treatment are imperative. The aim of this report is to underscore the importance of established guidelines while acknowledging the need for an individualistic approach in complex situations.

CASE PRESENTATION: An 87-year-old female patient who underwent femoral crossover bypass procedure 16 days prior to admission was brought to the emergency department in a state of shock with dyspnea, elevated lactate (6.0 mmol/L) and liver enzymes (AST= 301 U/L, ALT= 183 U/L). Her initial blood pressure (BP) was 70/40 mmHg, PESI class V, with good response on fluid replacement and vasopressors. Echocardiography showed acute dilatation of right ventricle. MSCT pulmonary angiography revealed a massive saddle PE. Low molecular weight heparin therapy was initiated, but the patient's state soon rapidly deteriorated. Transportation to a facility for aspiration thrombectomy was deemed high-risk, due to hemodynamic instability. Systemic fibrinolysis was possible, but history of recent surgery within last 3 weeks was an absolute contraindication (ESC guidelines). After consultation with a surgeon who deemed the operated area readily compressible and approachable for surgical reintervention, an alteplase protocol was initiated. Patient's condition immediately improved. A follow-up echocardiography revealed the normalization of the right ventricle diameter and function. The only complications were bilateral inguinal hematomas without visible extravasation on MSCT angiography.

CONCLUSION: In conclusion, guidelines facilitate decision-making, but an individual approach is crucial when treating a patient in complex situations, even if it sometimes necessitates going beyond guidelines.

CR08**Astragalectomy as “last resort” in treatment of avascular necrosis of the talus**Dinko Ezgeta^a, Afan Ališić^a, Damjan Dimnjaković^b^a School of Medicine University of Zagreb^b Department of Orthopedic Surgery, University Hospital Centre ZagrebDOI: <https://doi.org/10.26800/LV-144-supl2-CR08> Dinko Ezgeta 0000-0001-9391-6269, Afan Ališić 0000-0003-1945-6262, Damjan Dimnjaković 0000-0002-5726-4301

Keywords: Astragalectomy, AVN, talus

INTRODUCTION/OBJECTIVES: Avascular necrosis (AVN) of the talus is a relatively rare lesion of the bone in which bone decays due to ischemia. Although the leading cause of AVN is prior trauma, it can also occur with non-traumatic causes such as corticosteroids, alcohol abuse, systematic illness, but also as a complication of prior surgery. While conservative treatment is always used at the beginning, surgery may be required afterwards. The goal of this report is to present a case of treatment of talar AVN with astragalectomy and tibio-calcaneal arthrodesis.

CASE PRESENTATION: 60-year-old male presented to the clinic with severe pain and restricted movement in his right ankle. The patient has undergone anterior ankle arthroscopy and open debridement of the talonavicular joint in another hospital, 3 years earlier. The MRI showed signs of AVN of the whole body of the talus. Conservative treatment was conducted, including physical therapy and treatment in hyperbaric oxygen therapy. Two years later, due to progression of pain, surgery was indicated. Due to necrosis that involved the whole body of the talus, removal of the talus, i.e. astragalectomy was performed, followed by tibio-calcaneal arthrodesis with an external fixateur. The fixateur was removed 6 months later, after the x-ray showed adequate bone fusion. At final follow-up the patient was pain free and was walking without crutches.

CONCLUSION: AVN of the talus puts up a challenging problem in modern medicine. In cases like this one, where conservative treatment fails, astragalectomy and tibio-calcaneal arthrodesis may prove as a viable treatment option.


CR09**Bilateral blindness due to endophthalmitis and corneal ulcer caused by *E. faecalis* as a result of chronic intentional self-injury**

Rea Deghenghi^a, Dora Cvrtila^a, Sanja Masnec^{a,b}, Ivan Škegro^{a,b}, Miro Kalauz^{a,b}, Marija Barišić Kutija^b, Tomislav Kuzman^{a,b}

^a School of Medicine, University of Zagreb

^b Department of Ophthalmology, Zagreb University Hospital Center

DOI: <https://doi.org/10.26800/LV-144-supl2-CR09>

 Rea Deghenghi 0000-0002-4059-0602, Dora Cvrtila 0000-0001-7335-2267, Sanja Masnec 0000-0003-1472-0511, Ivan Škegro 0000-0003-2872-7351, Miro Kalauz 0000-0001-7616-9871, Marija Barišić Kutija 0000-0002-7844-5718, Tomislav Kuzman 0000-0002-7137-5059

Keywords: corneal ulcer, *E. faecalis*, endophthalmitis, psychiatric disorder, self-harm

INTRODUCTION/OBJECTIVES: Endophthalmitis and corneal ulcer are complications of a long-term neglected keratitis and other eye infections. In serious cases they can lead to rapid deterioration in vision acuity and even complete blindness.

CASE PRESENTATION: We present a case of 56-year-old obese woman coming to our department complaining about blurry vision in her left eye for the last six months with unspecific skin lesions on her face, lips, eyelids and abdomen. Complete serological and immunological diagnostic panels were performed to exclude systemic autoimmune diseases such as SJS and SLE which were our primary concern. Corneal scraping was positive on *E. faecalis* which caused the corneal ulcer. She was treated with corticosteroid injections and antibiotics according to antibiogram. After discharge, a few months later, she was readmitted with the same diagnosis, now on her right eye, followed by a severe case of endophthalmitis. At this point, the patient only saw hand movements and had modest light perception. Suspicion to self-injury in a form of constant scratching and crust tearing was raised. The patient continuously denied self-harming, did not follow up on given therapy and psychiatric evaluation which eventually led to complete blindness and permanent immobility due to morbid obesity. With little family support, obvious self-neglect, and GP's inability to motivate her, the patient passed away from respiratory failure.

CONCLUSION: Although a rarity, intentional mechanical eye trauma should be considered in progressive and etiologically unclear eye pathology. By setting proper diagnosis earlier and with psychiatric treatment, this case could have had a different outcome.


CR10**Clinical presentation of vision loss after emulsification of silicone oil due to pars plana vitrectomy**

Karla Bodakoš^a, Antonio Kokot^{a,b}, Slaven Balog^b

^a Faculty of Medicine, University of Osijek

^b Ophthalmology Clinic dr.Balog, Osijek

DOI: <https://doi.org/10.26800/LV-144-supl2-CR10>

 Karla Bodakoš 0000-0002-4912-3453, Antonio Kokot 0000-0002-4836-7536, Slaven Balog 0000-0001-6988-9432


Keywords: ophthalmology, silicone oil, vitrectomy

INTRODUCTION/OBJECTIVES: Silicone oil is used as an intraocular tamponade in the treatment of retinal detachment and significantly improves the prognosis of vision restoration. Sometimes this procedure can result in complications; therefore we want to point out the possibility of its occurrence.

CASE PRESENTATION: A 75 year old Croatian female patient came to "Ophthalmology Clinic dr. Balog" with a vision loss in her left eye. Patient had surgical procedure one year ago when pars plana vitrectomy with silicone oil instillation and cataract surgery was performed due to retinal detachment. Previous diagnosis in medical history includes arterial hypertension. There was no history of recent injury or allergy. Upon arrival, clinical examination was performed and it involved visual acuity test, slit-lamp examination and optical coherence tomography (OCT) of both eyes. Counting fingers eye test showed a great decrease in visual acuity. Furthermore, slit-lamp examination revealed oil in the vitreous cavity of the left eye and an impression of a tiny layer of emulsified oil over the macula. OCT proved the appearance of many small drops of emulsified oil on the macula. Droplets covering the surface of the macula could be the reason for a decrease in visual acuity. Patient was advised to see vitreoretinal surgeon for further discussion about removal or reinsertion of silicone oil.

CONCLUSION: We should consider this complication in patients who have had vitrectomy with silicone oil instillation in their past. So if a complication occurs it can be effectively recognized at clinical examination and adequately instructed for further procedures.

CR11**A patient with thrombophilia and constrictive pericarditis – case report**Matea Severin^a, Maja Sirovica^a, Martina Lovrić Benčić^{a,b}^a School of Medicine, University of Zagreb^b Department of Cardiovascular Diseases, University Hospital Centre ZagrebDOI: <https://doi.org/10.26800/LV-144-supl2-CR11>

 Matea Severin 0000-0002-4851-679X, Maja Sirovica 0000-0002-4751-0513, Martina Lovrić Benčić 0000-0001-8446-6120


Keywords: constrictive pericarditis, MSCT, thrombophilia

INTRODUCTION/OBJECTIVES: The diagnosis of constrictive pericarditis is difficult. Cardiac catheterization with intracavitary pressure curves analysis is considered as a gold standard, but other methods should also be included. This condition can be complicated with comorbidities.

CASE PRESENTATION: A patient was admitted to hospital with symptoms of right heart congestion and atrial fibrillation, known for 4 years. Anticoagulant therapy with dabigatran was started. Suddenly he felt breathless and thoracic MSCT showed bilateral incapsulated pleural effusion, bronchial deformities and a small pericardial effusion that measured 0.7 cm. MSCT pulmonary angiography did not show pulmonary embolism. Fiberoptic bronchoscopy found only nonspecific mucopurulent substrate. Quantiferon test was negative. Dyspnea and pericardial effusion were worsening. Echocardiography showed dilatation of both atria with indirect signs of high right atrial pressure and constrictive hemodynamic and thrombus in right atrium (RA). Another MSCT revealed multiple thrombi in RA, segmental PA, LA auricula. Genetic analysis confirmed thrombophilia. Cardiac MR confirmed constrictive pericarditis. Despite anticoagulant therapy he had another thromboembolic episode; inferior and superior caval vein thrombosis and right iliac artery embolism. Iliac artery thromboendarterectomy was performed. PET CT revealed metabolic active pericardium, so tuberculostatic treatment was started despite of negative Quantiferon test. Pericardiectomy was done partially due to adherent thick pericardium. Pathohistological analysis of pericardium did not confirm specific inflammation - tuberculostatic therapy was stopped. Patient was discharged in improved condition.

CONCLUSION: The diagnosis of constrictive pericarditis can be challenging, sometimes without known etiology. Comorbidities should be treated simultaneously.

CR12**Congenital hypotonia of an unclear origin**Andrija Matijević^a, Danijel Mikulić^a, Grgur Matolić^a, Valentina Matijević^b^a School of Medicine, University of Zagreb^b University Department of Rheumatology, Physical Medicine and Rehabilitation, University Hospital Centre Sestre MilosrdniceDOI: <https://doi.org/10.26800/LV-144-supl2-CR12>

 Andrija Matijević 0000-0002-0483-1392, Danijel Mikulić 0000-0001-9176-2091, Grgur Matolić 0000-0002-0549-4674, Valentina Matijević 0000-0003-0096-2034

Keywords: Early Diagnosis, Infant, Muscle hypotonia, Physical Therapy Modalities

INTRODUCTION/OBJECTIVES: Congenital hypotonia is a rare condition characterized by a reduced muscle tone and strength. Hypotonias can be central, originating from the central nervous system or peripheral, related to the disorders of the peripheral nerves and/or muscles. The diagnosis process consists of physical examination, lab tests, and gene analysis.

CASE PRESENTATION: We present an 8-months old male infant referred by a primary pediatrician under the suspicion of hypotonia. Upon first inspection, the given motor response was deficient on supination, lower extremities were crossed, with lower general muscle tone. Occasional tremor of the upper limbs was noted, and when set in a four-legged position, the patient could not maintain the posture which always led to falling. When placed in a sitting position, the patient balanced himself with antelexion and leaning on his hands. Psychosocial development was concordant with age. Physical therapy was started. Six months later, the follow-up showed great improvement of the general physique. The patient was able to seat himself, manipulate objects with both hands, move to the four-legged position on his own, and stand on his feet with assistance. The pincer-grasp was not present till that time.

CONCLUSION: The reported case is an extraordinary example of significant progress, even when the diagnosis is not established on time. Early diagnosis and an early start of regular physical exercise are vital parts of managing patients with hypotonia. Although the condition is limiting, many functions could be acquired that could ensure somewhat of a normal life.


CR13**Case of allergic reaction to polyethylene-glycol from rectal suppositories and its relation to COVID-19 vaccination**Stjepan Brnić^a, Robert Likić^{a,b}^a School of Medicine University of Zagreb^b Unit for Clinical Pharmacology, Department of Internal Medicine, University Hospital Centre ZagrebDOI: <https://doi.org/10.26800/LV-144-supl2-CR13> Stjepan Brnić 0000-0002-8218-7854, Robert Likić 0000-0003-1413-4862

Keywords: allergy, COVID-19, polyethylene-glycol, vaccination

INTRODUCTION/OBJECTIVES: Polyethylene-glycol (PEG) is a compound derived from petroleum with many uses in medicine. Because of its hydrophilic properties, it is commonly found as a basis in several laxatives, but it is also widely used as an excipient in various pharmaceutical products, most notably in the mRNA technology based COVID-19 vaccines. Recent studies have shown that conjugation of PEG to nanoparticles may enhance its immunogenic properties which could explain sporadic cases of postvaccination anaphylaxis to mRNA-based vaccines.

CASE PRESENTATION: A 20-year-old male was referred to clinical pharmacologist for a consult regarding safety of COVID-19 vaccination. His past medical history was remarkable for cerebellar developmental venous anomaly, anaphylaxis to wasp sting and an allergic reaction following a rectal suppository (sodium bicarbonate, potassium bicarbonate, polyethylene-glycol; EvaQu®) administration, which manifested with angioedema, muscle spasms, chills and fever. After suspecting polyethylene-glycol was a possible trigger compound for the hypersensitivity reaction, a percutaneous skin test was indicated in order to rule out the PEG hypersensitivity, before an mRNA based COVID-19 vaccine is administered.

CONCLUSION: Polyethylene-glycol has recently been identified as a possible cause of anaphylactic reactions to mRNA-based COVID-19 vaccines. Patients with known or suspected hypersensitivity to PEG should not be vaccinated with the mRNA based vaccines before a consultation with an allergologist and evaluation of the need for hypersensitivity testing.

CR14**ECTOPIC PREGNANCY IN CESAREAN SECTION SCAR**Laura Vidović^a, Marina Šprem Goldštajn^b^a School of Medicine, University of Zagreb^b Department of Obstetrics and Gynecology, School of Medicine, University of Zagreb; Clinic of Gynecology and Obstetrics, University Hospital Petrova ZagrebDOI: <https://doi.org/10.26800/LV-144-supl2-CR14> Laura Vidović 0000-0003-4168-0973, Marina Šprem Goldštajn 0000-0003-1747-204X

Keywords: cesarean section scar, ectopic pregnancy, laparotomy

INTRODUCTION/OBJECTIVES: Ectopic pregnancy is a life-threatening condition in which the blastocyst implants anywhere outside of the endometrial lining of the uterine cavity. In most cases the ectopic gestation takes place in fallopian tubes. However, sometimes it could be found in cesarean section scars which can lead to complications such as uterine rupture, life-threatening hemorrhage and hypovolemic shock.

CASE PRESENTATION: A 35-year-old woman with a history of a previous cesarean section, presented with severe pain in the epigastric region accompanied with diffuse pain in lower abdomen. The ultrasonography detected a fetal mass within the uterine cavity with an average gestational age of 10 weeks, along with some excess fluid and coagula in the rectouterine space. The patient underwent laparoscopy which discovered a large bleeding located on the previous cesarean section scar. The procedure was converted into lower median laparotomy, removing the ectopic gestation and reconstructing the uterine wall. Within postoperative course, she received 700 mL of erythrocyte concentrate and antibiotics. The 1- and 2-week follow-up showed no further postoperative complications and a continuous fall in serial measurements of beta hCG.

CONCLUSION: Although extremely rare, cesarean scar pregnancies represent a severe obstetric condition that should always be considered alongside other types of ectopic pregnancies in a differential diagnosis of a female patient with symptoms of acute abdomen. Making the right diagnosis and initiating prompt clinical treatment is key to reducing the risk of possible complications.

CR15**Multiple pulmonary metastases from a pleomorphic adenoma of the parotid gland**


Robert Gečević^a, David Glavaš Weinberger^a, Marko Gangur^a, Ivan Đureković^a, Ivica Lukšić^{a,b}, Marko Tarle^{b,c}

^a School of Medicine University of Zagreb, Croatia

^b Department of Maxillofacial Surgery, Dubrava University Hospital, Zagreb, Croatia

^c School of Dental Medicine, University of Zagreb, Croatia

DOI: <https://doi.org/10.26800/LV-144-supl2-CR15>

 Robert Gečević 0000-0002-8533-9788, David Glavaš Weinberger 0000-0003-4671-7499, Marko Gangur 0000-0003-1710-735X, Ivan Đureković 0000-0001-9805-8187, Ivica Lukšić 0000-0002-9138-2037, Marko Tarle 0000-0002-4173-1278

Keywords: lung metastasis, parotid gland, pleomorphic adenoma

INTRODUCTION/OBJECTIVES: Pleomorphic adenomas are the most common salivary gland tumors and surgical therapy is the main method of treatment. However, there are rare reports in which these histologically benign tumors have metastasized to distant sites in an unexplained manner(1). Metastasizing pleomorphic adenoma (MPA) represents an extremely rare group of tumors. Although apparently benign, mortality in MPA can be as high as 22% (1). We describe a patient with a very rare case of pulmonary metastasis of pleomorphic adenoma of the parotid gland.

CASE PRESENTATION: A 53-year-old male patient was diagnosed with pleomorphic adenoma of the right parotid gland at the age of 30 years. Initial therapy included a right superficial parotidectomy. Nineteen years later, a palpable formation in the right infraauricular area was investigated. Recurrence of disease was confirmed, whereupon total parotidectomy followed by adjuvant radiotherapy in 27 fractions was performed. Recently, multiple bilateral infiltrations of the lung were suspected on preoperative radiological examination, which was confirmed by PET-CT and MSCT scans. Biopsy of the suspicious lesions revealed pulmonary metastases of pleomorphic adenoma. Cytoreductive therapy was initiated in 6 suspicious lesions. In short, nearly 90 infiltrations were present.

CONCLUSION: Although pleomorphic adenoma is a benign tumor, it can metastasize to regional lymph nodes and distant organs if inadequately treated. The high mortality rate of histologically defined benign disease that metastasizes requires careful primary excision and long-term clinical follow-up. The occurrence of metastases within the first 10 years after initial surgery and the presence of metastases at multiple sites are independent predictors of poor survival(3).


CR16**Large aortocoronary saphenous vein graft aneurysm – a case report**

Natalia Pappo^a, Lana Palčić^a, Goran Međimurec^b, Kristina Krželj^b, Dražen Belina^b

^a School of Medicine, University of Zagreb

^b Department of Cardiac Surgery, University Hospital Center Zagreb

DOI: <https://doi.org/10.26800/LV-144-supl2-CR16>

 Natalia Pappo 0000-0002-9667-7782, Lana Palčić 0000-0002-6223-6233, Goran Međimurec 0000-0002-9602-7114, Kristina Krželj 0000-0003-2269-3138, Dražen Belina

Keywords: aneurysm, coronary artery bypass surgery, saphenous vein graft

INTRODUCTION/OBJECTIVES: Saphenous vein graft aneurysm (SVGA) is a dilation of a venous graft more than 1.5 times its' original diameter. It is a rare complication of coronary artery bypass surgery (CABG) with an estimated incidence of 0,07%. SVGAs are discovered on average 13 years after CABG and manifest as stenocardia, dyspnoea or acute myocardial infarction (MI), although a third are discovered incidentally. They are most likely caused by atherosclerotic degeneration.

CASE PRESENTATION: A 74-year-old man presented to the ER complaining of chest pain on minimal exertion. His past medical history was notable for CABG performed 23 years prior using 4 saphenous grafts. A year ago, he had a chest radiograph done showing a 75 mm shadow in the left mediastinum. After initial workup, MI without ST elevation was diagnosed. Coronary angiography revealed 3 occluded grafts, a large aneurysm of the fourth graft and three-vessel coronary disease with stenosis of the left main coronary artery. On computed tomography, the aneurysm measured 78 mm in the largest diameter and was pressing on the main and left pulmonary arteries. Emergent CABG was performed with ligation of the occluded grafts, resection of the aneurysm and revascularization of the affected myocardium. Postoperative course was challenging, involving prolonged mechanical circulatory and respiratory support, and the patient died due to sepsis on the 28th postoperative day.

CONCLUSION: This case highlights the importance of close follow-up in patients with multiple aortocoronary venous grafts. Furthermore, SVGA should be considered in differential diagnosis of a mediastinal shadow in patients with CABG.


CR17**A Case Report of a Mysterious Rapidly Enlarging Neck Mass That Is neither a Tumour nor an Inflammation**

Antonela Geber^a, Vesna Galjuf^a, Andro Košec^b, Siniša Stevanović^b

^a School of Medicine University of Zagreb

^b Department of Otorhinolaryngology and Head and Neck Surgery, Sestre milosrdnice University Hospital Center Zagreb

DOI: <https://doi.org/10.26800/LV-144-supl2-CR17>

 Antonela Geber 0000-0002-6438-3034, Vesna Galjuf 0000-0003-0509-1303, Andro Košec 0000-0001-7864-2060, Siniša Stevanović 0000-0002-6388-1998

Keywords: lymphovascular malformation, neck mass, rapidly enlarging mass

INTRODUCTION/OBJECTIVES: The underlying cause of a neck mass can be hard to identify. In most cases it is infection or neoplastic growth. Expedient diagnostic workup is especially important in rapidly enlarging masses to address possible malignancy.

CASE PRESENTATION: A 43-year-old female patient with history of sharp object neck trauma at the age of 7 presented with a neck mass in the right supraclavicular region. Two days prior to noticing the mass, the patient wore a heavy bag over the right shoulder and reported tingling in right supraclavicular area. Physical findings included a firm, painful mass, without skin redness, measuring up to 4 cm in diameter, without regional lymphadenopathy. Laboratory results showed increased CRP (16,5 mg/L), leukocytosis (13,0 x 10⁹/L) and neutrophilia (9,68 x 10⁹/L; 74,4%). The patient was given oral antibiotics (amoxicillin/clavulanate and cefuroxime). The mass enlarged further up to 7 cm in diameter the following day. Ultrasonography showed a hypoechoic mass measuring 50x30 mm, with septa and unclear borders. Doppler showed no active blood flow. Multi-slice computed tomography (MSCT) and magnetic resonance imaging (MRI) detected a 63x55x53 mm inhomogeneous, cystic, multilocular, lymphovascular structure. Fine needle aspiration suggested a benign lymphovascular lesion with inflammation and connective tissue degeneration. Surgery was performed to remove the mass, with ligation of feeding vessels. Four weeks later, the patient remains free of recurrence. Follow-up ultrasonography showed only connective tissue scar.

CONCLUSION: Lymphovascular malformations are rare, but may present a significant diagnostic challenge. Imaging such as ultrasonography, MSCT and MRI, are crucial for timely and accurate diagnosis.

CR18**Difficulties encountered by a deaf-mute patient and paresis of the vocal cords after COVID-19 infection**


Mirella Graffel^a, Katarina Skopljak^b, Lucia Bekić^a, Luka Lažeta^c

^a School of Medicine University of Zagreb

^b Clinic for Psychiatry Sveti Ivan

^c Department of Emergency Medicine of Požega-Slavonia County

DOI: <https://doi.org/10.26800/LV-144-supl2-CR18>


 Mirella Graffel 0000-0002-9140-5737, Katarina Skopljak 0000-0002-8027-8584, Lucia Bekić 0000-0002-5067-595X, Luka Lažeta 0000-0002-2546-6160

Keywords: COVID-19, deaf-mute, vocal cords

INTRODUCTION/OBJECTIVES: The World Health Organization (WHO) definition of "deafness" refers to it as a complete loss of the ability to hear in one or both ears. Hearing is necessary for the development of speech, language, and cognitive skills. Mutism occurs secondary to non-rehabilitation of deafness. There are numerous factors leading to deafness. If left unaddressed, it leads to communication, speech, cognition, education and employment difficulties, as well as social isolation, loneliness and stigma.

CASE PRESENTATION: Patient M.D., born in 1989, a 4th year student, was admitted to his first psychiatric treatment accompanied by his mother after taking a large amount of benzodiazepines in an attempt to commit suicide. He has been deaf since birth, without a positive family history of deafness. He communicates by writing. In December 2020 he overcame COVID-19, but in the post-COVID-19 recovery he suffered from vocal cord paresis that disrupted his sound production, which previously helped him communicate, swallow and eat (he lost 17 kilograms). He was soon scheduled for vocal cord surgery, causing anxiety and fear, which provoked his acute psychological deterioration.

CONCLUSION: An increase in cases of "idiopathic" paralysis and vocal cord paresis has been observed in patients without a history of intubation who are recovering from the SARS-Cov-2 coronavirus. The cause of vocal cord paresis is postviral vagal neuropathy (PVVN) as a consequence of coronavirus infection. Even before the coronavirus infection, the patient encountered difficulties with speech, socialization, schooling and communication, but PVVN led him to mental instability accompanied by suicidal thoughts.


CR19**A rare presentation of Langerhans cell sarcoma in the parotid gland**Stela Marković^a, Josipa Živko^b, Vesna Bišof^{a,c,d}^a *University of Zagreb School of Medicine, Zagreb, Croatia*^b *Clinical hospital „Dubrava“, Zagreb, Croatia*^c *Department of Oncology, Clinical Hospital Centre Zagreb, Zagreb, Croatia*^d *School of Medicine, University of Osijek, Osijek, Croatia*DOI: <https://doi.org/10.26800/LV-144-supl2-CR19> Stela Marković 0000-0003-2149-2422, Josipa Živko 0000-0001-7297-5366, Vesna Bišof 0000-0002-2826-9664

Keywords: Langerhans cell sarcoma, radiotherapy, rare tumor, salivary glands

INTRODUCTION/OBJECTIVES: Langerhans cell sarcoma (LCS) is a very rare, high-grade malignancy of the Langerhans cells and may vary from isolated lesion to multifocal disease. Parotid gland involvement is an exceptionally rare clinical presentation of LCS even in patients with multifocal disease.

CASE PRESENTATION: We report a case of LCS in the left parotid gland that occurred in a 63-year-old male. The patient presented with a palpable mass on the left side of the face. Ultrasonography showed three hypoechoic nodules in the left parotid gland. The patient underwent parotidectomy and selective neck dissection levels II-III. Immunohistochemical studies of the tumor tissue showed marked positivity to S100 and CD68, and focally positive CD1A staining. The presence of Birbeck granules on electron microscopy couldn't be reliably established. With 20 mitoses per 10 HPFs, tumor tissue exhibited high proliferative activity. Tumor was confined to the parotid gland with no involvement of adjacent lymph nodes. On the initial assessment, there were no signs of systemic dissemination. Four months post parotidectomy, PET-CT revealed focally increased metabolism in the soft tissue nodule located along the posterior edge of the gonial angle on the left side protruding medially, which raised suspicion of disease recurrence. Ultrasonically guided FNA did not show the presence of malignant cells. Surgery was followed by adjuvant radiotherapy 66 Gy in 33 fractions. There has been no evidence of recurrence or disease progression over the past 14 months since diagnosis.

CONCLUSION: LCS should be kept in mind in the differential diagnosis in patients with parotid enlargement.

CR20**ACUTE LIVER FAILURE IN SECONDARY HEMOPHAGOCYTIC LYMPHOHISTIOCYTOSIS AFTER COVID – 19 VACCINATION**Matea Živko^a, Nikola Sobočan^b^a *School of Medicine University of Zagreb*^b *Department of gastroenterology, University hospital Merkur*DOI: <https://doi.org/10.26800/LV-144-supl2-CR20> Matea Živko 0000-0001-5033-3506, Nikola Sobočan 0000-0001-6721-9232

Keywords: adult multisystem inflammatory syndrome, acute liver failure, covid-19 vaccination, hemophagocytic lymphohistiocytosis

INTRODUCTION/OBJECTIVES: Hemophagocytic lymphohistiocytosis (HLH) is hyperinflammatory hyperferritinemic syndrome. Secondary HLH is known in adults and can be triggered by infections, malignancies or autoimmune response. If not recognized, HLH leads to multiorgan failure and death. CASE PRESENTATION: A 61-year-old male came to emergency room complaining of continuous high fever which started 10 days after COVID-19 vaccination. Patient was prescribed with co-amoxiclav. 14 days later, fever still not diminishing, patient was admitted to hospital. He tested negative for SARS-CoV-2 twice. Despite empirical antibiotic treatment, fever persisted. MSCT showed hepatosplenomegaly. Based on high fever, hepatosplenomegaly and hyperferritinemia, hemophagocytic syndrome was suspected. After administering dexamethasone, fever decreased. 7 days post-hospitalization, coagulation deficit (PT 2.71), high transaminases (AST 3658 IU/L, ALT 4494 IU/L), jaundice (bilirubin 269 μmol/L) and stage III portal encephalopathy indicated acute liver failure. Patient was transferred to a larger medical center for high urgency liver transplantation as trans-jugular liver biopsy confirmed sub-massive liver necrosis. Criteria for high urgency transplantation were not met because diagnostic tests confirmed secondary hemophagocytic lymphohistiocytosis probably as a part of adult multisystem inflammatory syndrome following vaccination. Patient complied to 6 out of 8 HLH-2004 diagnostic criteria – high fever, hepatosplenomegaly, hemoglobin

CONCLUSION: HLH may result in secondary acute liver failure, but emergency transplantation is not a treatment option.


CR21**Aplastic anemia in a patient with autoimmune Hepatitis**Anđela Deak^{a,b}, Slobodanka Ostojić Kolonić^{a,b}^a School of Medicine University of Zagreb^b Division of Hematology, Department of Internal Medicine; University Hospital MerkurDOI: <https://doi.org/10.26800/LV-144-supl2-CR21> Anđela Deak 0000-0002-3286-7675, Slobodanka Ostojić Kolonić 0000-0002-6487-3623

Keywords: Aplastic anemia, autoimmune hepatitis, azathioprine

INTRODUCTION/OBJECTIVES: Aplastic anemia is a rare stem cell disorder in which the bone marrow stops making cells, leading to pancytopenia. It can be inherited, but most cases are autoimmune, triggered by drugs, viruses, or irradiation

CASE PRESENTATION: A 47-year old woman was diagnosed with autoimmune hepatitis in 2019 after suffering from subacute hepatic failure. TPMT enzyme activity was normal. She was put on corticosteroid therapy followed by azathioprine 200 mg. The patient initially had a good response to therapy with normalization of transaminase levels. During the administration of prescribed therapy, pancytopenia was found. Azathioprine therapy was discontinued and the patient was put on dexamethasone monotherapy. The blood cell count didn't improve on corticosteroid therapy. Due to comorbidities, the patient was not a candidate for splenectomy so eltrombopag was introduced into therapy. Bone marrow biopsy revealed aplastic anemia in development caused by azathioprine and secondary immune mechanisms following autoimmune hepatitis. The introduction of cyclosporine instead of azathioprine combined with corticosteroids and eltrombopag resulted in an initial positive hematopoietic response. After the initial positive outcome of the combined therapy, the patient's thrombocytopenia worsened so anti-thymocyte globulins were included in therapy. Symptomatic thrombocytopenia, such as menometrorrhagia, was managed with platelet transfusions. During the hospitalization, HLA typing was done for bone marrow transplant planning.

CONCLUSION: Azathioprine-induced aplastic anemia is not so common but it is a serious complication. Treatment with the immune system – suppressing therapy or a bone marrow transplant is necessary for patients with severe aplastic anemia.

CR22**Atypical Raynaud syndrome and skin changes caused by late stage of Lyme disease with cryoglobulinemia**Paola Negovetić^a, Ena Parać^a, Tin Šklebar^b, Ljiljana Smiljanić Tomičević^{a,c}^a University of Zagreb School of Medicine^b Dom Zdravlja Zagreb Istok^c Division of Clinical Immunology and Rheumatology, Department of Internal MedicineDOI: <https://doi.org/10.26800/LV-144-supl2-CR22> Paola Negovetić 0000-0002-2658-5938, Ena Parać 0000-0002-6759-8364, Tin Šklebar 0000-0002-2228-0766, Ljiljana Smiljanić Tomičević 0000-0003-2807-7440


Keywords: Atypical Raynaud Syndrome, Cryoglobulinemia, Lyme disease

INTRODUCTION/OBJECTIVES: Raynaud's syndrome is a disease in which the peripheral blood vessels contract, reducing the blood supply to the affected region. It manifests with coldness, colour changes, and a sensation in the affected digits. Cryoglobulinemia is a presence of cryoglobulins in the serum that cluster together during cold temperatures limiting blood flow and generating damage to muscles, skin, organs, and nerves.

CASE PRESENTATION: A male patient reports changes in the skin color of his right hand, which turned purple when exposed to cold temperatures. On examination, the digits were thickened, the skin in the right hand, was livid, warm, and without clinical symptoms of Raynaud's syndrome. Clinically, acrodermatitis chronica atrophicans was suspected. The patient's serology was positive for *Borrelia burgdorferi* and histopathology of skin changes points to the chronic acrodermatitis found in the late stages of Lyme disease. The patient was diagnosed with Raynaud's syndrome by computerized color telethermography findings. In patient's serum, cryoglobulins type 3 were found. The infection probably caused mixed cryoglobulinemia and consequently atypical Raynaud's syndrome in this patient.

CONCLUSION: Secondary Raynaud's syndrome can be caused by cryoglobulinemia due to an infection with *Borrelia burgdorferi*, with typical skin changes, appears at a late stage of Lyme disease. The patients infected with *Borrelia* often do not know that they have been exposed to it, and the disease can sometimes come to late stages until it is detected. Hence, a thorough history must be taken, and if there are any doubts, the doctor conducts an extensive examination.

CR23**Balloon aortic valvuloplasty as a bridge to liver transplantation in patients with severe aortic stenosis**Martina Petrinović^a, Dora Meštrović^a, Lucija Mihaljević^a, David Preložiček^a, Vlado Vlaho Čubela^b^a School of Medicine University of Zagreb^b Department of Cardiology; Clinical Hospital MerkurDOI: <https://doi.org/10.26800/LV-144-supl2-CR23>

 Martina Petrinović 0000-0002-3456-0968, Dora Meštrović 0000-0002-3079-5209, Lucija Mihaljević 0000-0002-6114-1902, David Preložiček 0000-0003-1762-666X, Vlado Vlaho Čubela 0000-0002-5664-1873


Keywords: aortic stenosis, balloon aortic valvuloplasty, liver transplantation

INTRODUCTION/OBJECTIVES: Liver transplantation in patients with end-stage liver disease and concomitant severe aortic stenosis is considered to be high-risk surgery, due to the increased morbidity and mortality in the perioperative period, as well as incidence of intraoperative complications. These occur due to cirrhotic cardiomyopathy, decreased systemic vascular resistance and decreased intravascular volume, which oppose the pathophysiologic requirements of aortic stenosis. Aortic valve replacement is also contraindicated in these patients due to increased perioperative mortality.

CASE PRESENTATION: A 41-year-old woman presented with an acute liver failure resulting from a fulminant Hepatitis B infection and underwent orthotopic liver transplantation. Following a series of acute cholangitis attacks due to biliary strictures, the patient was diagnosed with decompensated Child-Pugh B liver cirrhosis of the graft. She also suffered from aortic valve stenosis, detected in 2018, which progressed to severe by 2021. Subsequently, an interdisciplinary meeting was held and a balloon-dilation of the aortic valve was conducted, with the transvalvular pressure gradient reduction of 30%, which enabled the second liver transplantation to be performed.

CONCLUSION: Multiple therapeutic approaches with respect to timing the liver transplantation and valve replacement have been used, but at this point consensus has not been reached. Balloon aortic valvuloplasty as a bridge to liver transplantation could present a solution to the challenges that these comorbidities present. It is important to emphasize the significance of multidisciplinary approach involving gastroenterologists, cardiologists, cardiac and abdominal surgeons and anesthesiologists. Further research on this method is required to objectify the advantages and disadvantages of this approach.

CR24**Breast reconstruction and capsular contracture as its complication**Andrea Kostić^a, Matea Kostić^a, Manuela Bajan^a, Lucija Gatin^b, Anto Dujmović^{a,b}^a School of Medicine University of Zagreb^b Division of Plastic, Reconstructive and Breast Surgery, Department of Surgery; University Hospital Centre ZagrebDOI: <https://doi.org/10.26800/LV-144-supl2-CR24>

 Andrea Kostić 0000-0003-0686-2616, Matea Kostić 0000-0002-1546-7485, Manuela Bajan 0000-0002-8859-4928, Lucija Gatin 0000-0001-8228-0023, Anto Dujmović 0000-0002-5736-5997

Keywords: Breast cancer, breast reconstruction, capsular contracture, radiotherapy

INTRODUCTION/OBJECTIVES: In 2020, 2894 breast cancer cases were diagnosed in Croatia according to ECIS. The mastectomy is one of the surgical treatment for breast cancer. The breast reconstruction can be primer preformed in the same procedure as skin sparing mastectomy or secondary. When preformed as primer reconstruction we mostly use silicon breast implants. Patients that undergo both implant-based breast reconstruction and radiotherapy have greater risk of developing a capsular contracture. The capsular contracture is an excessive fibrotic reaction to the implant.

CASE PRESENTATION: The patient is a 48-years-old woman who was diagnosed with invasive breast cancer. The skin and nipple sparing mastectomy (SNSM) and sentinel lymph node biopsy of the right breast was preformed and prophylactic SNSM of the left breast. After surgery patient underwent a period of radiotherapy which was complicated by radiation-induced dermatitis and lymphedema of the right hand. In the local status the right breast was positioned higher with tightness in the breast tissue. After completing oncology treatment patient was hospitalized for surgical treatment of bilateral capsular contracture with lipotransfer to both breasts. After the surgery no complications were present.

CONCLUSION: In patients that undergo adjuvant radiotherapy after implant-based breast reconstruction, capsular contraction should be considered as most common complication.


CR25**Catamenial Pneumothorax due to Thoracic Endometriosis: A Case Report**

Lea Jerkić^a, Nikolina Jupek^a, Tomislav Bečejac^{a,b}, Marko Vrančić^b, Ivan Bunjevac^b, Dubravko Jalšovec^{a,b}

^a School of Medicine, University of Zagreb

^b Jordanovac Clinical Department of Thoracic Surgery, University Hospital Centre Zagreb

DOI: <https://doi.org/10.26800/LV-144-supl2-CR25>

 Lea Jerkić 0000-0002-1361-7996, Nikolina Jupek 0000-0001-8212-9040, Tomislav Bečejac 0000-0001-8603-8314, Marko Vrančić 0000-0001-8603-8314, Ivan Bunjevac 0000-0002-8947-627X, Dubravko Jalšovec 0000-0001-8603-8314

Keywords: catamenial, endometriosis, pneumothorax, VATS

INTRODUCTION/OBJECTIVES: Thoracic endometriosis syndrome (TES) is the presence of endometrial implants in a thoracic cavity. Catamenial pneumothorax is the most common manifestation of TES.

CASE PRESENTATION: A 32-year-old female was admitted to the emergency department due to progressive dyspnea and the chest x-ray confirmation of right pneumothorax after the umbilical hernia surgery. Her medical history was significant for two episodes of right-sided pneumothorax. Recently, the patient underwent video-assisted thoracic surgery (VATS) in another hospital because of a recurrent pneumothorax episode. Right pneumothorax was shown in the chest x-ray. Immediate chest tube placement followed. As post-procedure chest X-ray showed incomplete lung reexpansion, VATS was again indicated. The patient underwent a VATS procedure, partial parietal pleurectomy, and suspicious lesions were resected. Histopathological examination of the removed tissue revealed endometriosis with the focal expression of estrogen receptors. The postoperative course was uneventful. Before discharging the patient, removal of the chest tube was attempted but resulted in a partial collapse of the right lung. We performed chest drainage again and extracted the chest tube after seven days. During the three months follow-up, the patient reported no recurrence of pneumothorax. Additional examination revealed that all episodes of pneumothorax were associated with the onset of menstrual bleeding.

CONCLUSION: Catamenial pneumothorax is a rare but often recurrent condition affecting women of reproductive age. The diagnosis should be suspected if the signs of respiratory distress occur in a temporal relationship with the beginning of a menstrual cycle. The best treatment approach is thoracic surgery, VATS preferably, and hormonal therapy.


CR26**Cervical cystic lymphangioma in a pediatric patient: a case report**

Nikolina Jupek^a, Lea Jerkić^a, Mario Bilić^{a,b}

^a School of Medicine, University of Zagreb

^b Department of Otorhinolaryngology and Head and Neck Surgery, University Hospital Center Zagreb

DOI: <https://doi.org/10.26800/LV-144-supl2-CR26>

 Nikolina Jupek 0000-0001-8212-9040, Lea Jerkić 0000-0002-1361-7996, Mario Bilić 0000-0002-2525-9524

Keywords: cervical cystic lymphangioma, respiratory failure, surgical excision

INTRODUCTION/OBJECTIVES: Cystic lymphangiomas are benign congenital malformations of the lymphatic system characterized by multilocular cystic cavities filled with fluid. Most commonly they are found among the pediatric population. They have a strong predilection for the cervicofacial region.

CASE PRESENTATION: We report a case of a 14-month-old female patient who presented with left-sided swelling of the neck which was present at birth. The swelling had progressively increased in size after an episode of upper respiratory tract infection. After admission to the hospital, routine tests were made. Her complete blood count and other biochemical parameters were within normal limits. Fine needle aspiration cytology was performed unsuccessfully. On the first night of hospitalization, the patient developed respiratory failure so Computed Tomography was delayed. Conventional X-ray images showed a deviation of the trachea and larynx to the right and a large shadow covering the left side of the neck. Ultrasound revealed 7 – 8 hypoechoic and hyperechoic round and elliptical areas and the largest one was located in the submental region. Complete surgical excision of the lesion was done. Postoperatively patient recovered well, without any complications. Histopathological examination of tissue confirmed the diagnosis of cystic lymphangioma. The patient has been followed up for 8 months with no evidence of disease recurrence.

CONCLUSION: Lymphangiomas are most often asymptomatic and require no treatment, but sometimes they can cause potentially fatal complications. Complete surgical excision is recommended for lesions that persist, enlarge, or produce obstructive symptoms.


CR27**DELAY IN DIAGNOSIS OF BEHCET'S SYNDROME— A CASE REPORT**

Olesia Strelchenia^a, Andrej Samoilenko^{a,b}, Vadym Oryshchenko^{a,b}, Tetiana Strelchenia^{a,b}

^a Medical Faculty, Dnipro State Medical University, Ukraine

^b Department of Therapeutic Dentistry

DOI: <https://doi.org/10.26800/LV-144-supl2-CR27>

 Olesia Strelchenia 0000-0002-7210-8753, Andrej Samoilenko 0000-0002-6866-6754, Vadym Oryshchenko 0000-0002-7210-8753, Tetiana Strelchenia 0000-0002-6638-8859

Keywords: Behçet syndrome, oral ulcers, skin lesions, delayed diagnosis

INTRODUCTION/OBJECTIVES: Behçet's syndrome (BS) is a rare chronic multisystemic disorder with unknown etiology and a unique geographic distribution. As well as in other vasculitides, damage in BC accrues over time and could cause significant influence on functional impairment and irreversible tissue loss.

CASE PRESENTATION: A 29-year-old woman who has been suffering from BS since the age of 24 developed a full destruction of soft palate and uvula, and is associate with nasal regurgitation of food and hypernasal speech. The above symptoms developed during a 4-year period that only oral symptoms of BS were present. Oral ulcerations recurred twice a year and lasted over 10-40 days, healed with scarring and tissue loss. The patient had been treated by practitioners as a cases of Sutton's disease. Cutaneous lesions on the face, hands and lower extremities were first noted a year ago and were caused by local trauma (pathergy test equivalent). The lesions were usually painful with overhanging borders and a grayish yellow necrotic base that healed with scarring within 2 to 3 weeks. The oral examination revealed well-defined, deeply punched-out, painful ulcers on hard palate and multiple scars. The patient had gone through medical evaluation. There was no other manifestation from the other system. The biopsy was unremarkable. Duration between the time onset of BS and the diagnosis was found to be 5 years.

CONCLUSION: Long-term untimely diagnosis of BS is largely due to lack of pathognomonic clinical finding and specific laboratory test. Although rare, BS should be considered in the differential diagnosis of oral ulceration of unknown etiology.

CR28**Dysmorphophobia**

Dora Herceg^a, Ena Parać^a, Petrana Brečić^b

^a School of Medicine, University of Zagreb

^b Department for Affective Disorders; University Psychiatric Hospital Vrapče


DOI: <https://doi.org/10.26800/LV-144-supl2-CR28>

 Dora Herceg 0000-0003-3275-1696, Ena Parać 0000-0002-6759-8364, Petrana Brečić 0000-0003-0577-4083


Keywords: dysmorphophobia, psychotherapy, somatoform disorders, surgical interventions

INTRODUCTION/OBJECTIVES: According to the ICD 10 classification, dysmorphophobia belongs to somatoform disorders. An important feature is a preoccupation with a flaw in physical appearance. The perceived defect is either imagined or, if existent, significantly exaggerated by the affected person. **CASE PRESENTATION:** The paper presents a 21-year-old modelling student who first contacted a psychiatrist after her suicidal ideation. For more than two years, she had been obsessing about the idea that the right side of her face was swollen, which was objectively not the case. She initially visited an ENT specialist, who found an allergy to dust and pollen and nasal septum deformation, after which septoplasty was performed. After the surgery, occasional pain occurred alongside swelling. The patient claimed that the surgeons "moved her facial bones" during the procedure, "permanently mutilating her". She asked for reoperation and a second opinion from a private plastic surgeon who stated that everything was fine physically and recommended that she contacts a psychologist. The patient then visits a psychiatrist who diagnoses dysmorphophobia, introduces antidepressant therapy and conducts individual supportive and behavioral cognitive therapy. Improvement is achieved, and the patient returns to her previous lifestyle and re-engages in all activities.

CONCLUSION: People suffering from dysmorphophobia often seek medical examinations or surgical procedures to correct their imaginary defect. Such interventions can cause the situation to worsen, leading to the intensification of existing or the emergence of new preoccupations, which again lead to new unsuccessful actions.


CR29**HEART TRANSPLANTATION AS THERAPY FOR DOXORUBICIN INDUCED CARDIOMYOPATHY**Mihovil Santini^a, Nika Barbara Pravica^a, Mario Udovičić^{a,b}^a School of Medicine University of Zagreb^b Department of Cardiology, University Hospital DubravaDOI: <https://doi.org/10.26800/LV-144-supl2-CR29> Mihovil Santini 0000-0002-1428-4484, Nika Barbara Pravica 0000-0001-5478-2392, Mario Udovičić 0000-0001-9912-2179

Keywords: dilated cardiomyopathy; heart transplantation; R-CHOP chemotherapy

INTRODUCTION/OBJECTIVES: Cardiotoxic effects of the established therapy protocols can cause severe cardiomyopathy and advanced heart failure, which may require advanced heart failure treatment.**CASE PRESENTATION:** In November 2014, a 39-year old female patient was admitted to the cardiology department presenting with newly detected dilated cardiomyopathy and acute heart failure, NYHA 4,**INTERMACS 2.** Previously, she was diagnosed with follicular center cell lymphoma (FCC) and successfully treated with R-CHOP chemotherapy, first in 2008 and again in May 2014 due to a relapse. Despite therapy, her condition was worsening and she was put on venoarterial extracorporeal membrane oxygenation (VA-ECMO), followed by temporary Centrimag biventricular assist device (BiVAD) support. Due to the recent lymphoma relapse a heart transplantation was not a viable option at that time. After two weeks, the left ventricular assist device (LVAD) HeartWare was implanted, with satisfactory right ventricular function. In June 2018 she presented for the first time with manifest right-sided heart failure. Since its progression could not be otherwise managed, the patient was put on the high urgent waiting list of Eurotransplant for heart transplantation in November 2018. In January 2019, a heart transplant operation was successfully performed and three years later, the patient remains well, and without any signs of relapse of the FCC.**CONCLUSION:** Temporary circulatory support followed by LVAD implantation as a bridge to candidacy strategy, and finally, the heart transplantation proved to be an excellent decision even though less than 5 years have passed since the relapse of the malignant disease.**CR30****Hyperthyroidism as a secondary cause of worsening hypertension - a case report**Mia Edl^a, Lucija Čolaković^a, Lada Zibar^{a,b}^a Faculty of Medicine, Josip Juraj Strossmayer University of Osijek, Osijek, Croatia^b University Hospital Merkur, Department of Nephrology, Zagreb, CroatiaDOI: <https://doi.org/10.26800/LV-144-supl2-CR30> Mia Edl 0000-0002-7818-5741, Lucija Čolaković 0000-0002-0212-3843, Lada Zibar 0000-0002-5454-2353

Keywords: Blood pressure, Hypertension, Hyperthyroidism, Secondary hypertension

INTRODUCTION/OBJECTIVES: Hyperthyroidism increases systolic blood pressure (BP) by decreasing systemic vascular resistance, increasing heart rate, and raising cardiac output. Symptoms of hyperthyroidism may include palpitations, nervousness, sweating, weight loss, frequent bowel movements, heat intolerance, and insomnia. Treatment of hyperthyroidism alone lowers systolic BP in most patients.**CASE PRESENTATION:** A 75-year-old woman reported to a nephrologist for extremely high hypertension, with BP jump above 200/110 mmHg 2 - 3 times/month for the last 2 years, after many years of perfectly controlled hypertension. She complained of fatigue, weight loss, insomnia, and nervousness. A workup for secondary hypertension was suggested. Laboratory findings showed thyroid-stimulating hormone of 0.17 mU/L (ref. range 0.35-4.9 mU/L) and free thyroxine of 12.82 pmol/L (ref. range 9.00-19.00 pmol/L). Thyroid imaging revealed a toxic nodular goiter. Subclinical hyperthyroidism was diagnosed and thiamazole treatment was introduced. Upon the treatment, her BP was within normal values with amlodipine 5 mg. She felt well, has gained weight, while control findings indicated adequate suppression of the thyroid.**CONCLUSION:** Although hyperthyroidism is a well-known cause of secondary hypertension, it is still seldom to meet it as such in clinical practice. We presented a case of hyperthyroidism as the cause of secondary dysregulation of long-lasting essential hypertension. Secondary hypertension is generally infrequent and thus easy to miss. Deterioration of BP control in a patient with previously well-controlled hypertension for years should also raise suspicion for a secondary cause. By treating hyperthyroidism, BP was under control again, confirming the presented relationship.


CR31**Intraductal papillary neoplasm of the bile duct (IPNB) as an uncommon cause of abdominal pain and cholangitis**Stjepan Herceg^a, Lucija Virović Jukić^b^a School of Medicine, University of Zagreb^b Department of Gastroenterology and Hepatology, Sestre Milosrdnice University Hospital Center, Zagreb, CroatiaDOI: <https://doi.org/10.26800/LV-144-supl2-CR31> Stjepan Herceg 0000-0001-9543-4482, Lucija Virović Jukić 0000-0002-6350-317X

Keywords: bile ducts, cholangiocarcinoma, endoscopic ultrasound (EUS), intraductal papillary, neoplasm, magnetic resonance cholangiopancreatography (MRCP)

INTRODUCTION/OBJECTIVES: Intraductal papillary neoplasm of the bile duct (IPNB) is a relatively new entity characterized by dilation of bile ducts filled with papillary neoplasms, which represents premalignant lesion of cholangiocarcinoma, with common malignant transformation.

CASE PRESENTATION: A 75-year-old woman presented to our Department after an episode of dull epigastric pain radiating into the chest and the back accompanied by fever and cholestatic liver lesion, which was consistent with an episode of acute cholangitis. A CT scan performed before admission showed dilated intrahepatic bile ducts and hyperdense content within the dilated common bile duct 4 cm proximally to duodenal papilla that was suspicious of a neoplasm. Therefore, we performed an endoscopic ultrasound (EUS), which also showed dilated common bile duct, mostly filled with echogenic masses, suspicious of IPNB. During EUS, a fine needle aspiration was performed, and cytological analysis was consistent with adenocarcinoma. To assess the extent of bile ducts involvement, a magnetic resonance cholangiopancreatography (MRCP) was performed, which showed beading and dilation of intrahepatic and both extrahepatic bile ducts including common bile duct, with filling defects forming papillary formations in some places. Furthermore, a hypointense mass was found within the common bile duct, confirming a cytology report and CT finding of the malignant tumor. The patient is now scheduled for surgery of the IPNB associated cholangiocarcinoma of the distal part of the common bile duct.

CONCLUSION: IPNB is a very rare condition and an uncommon cause of cholangitis. Thus, timely diagnosis is important for proper treatment.


CR32**Invasive Fungal Sinusitis Presenting as Unilateral Vision Loss: A Case Report**Lea Jerkić^a, Kristina Lončarić^b^a School of Medicine, University of Zagreb^b Clinical Department of Ophthalmology and Optometry, Sestre Milosrdnice University Hospital CenterDOI: <https://doi.org/10.26800/LV-144-supl2-CR32> Lea Jerkić 0000-0002-1361-7996, Kristina Lončarić 0000-0003-0928-7952

Keywords: invasive fungal sinusitis, optic neuropathy, sphenoidotomy

INTRODUCTION/OBJECTIVES: Invasive fungal sinusitis is a rare condition mainly affecting the immunocompromised. As a result of the invasion of the optic canal, optic neuropathy and subsequent vision loss can develop.

CASE PRESENTATION: A 76-year-old female presented for an ophthalmologic consultation complaining of a three-week history of vision loss in the right eye. She also had right-sided temporal and periauricular headaches for the last two months. Her medical history was remarkable for diabetes mellitus type II, hyperlipidemia, hypertension, cerebrovascular insult with right hemiparesis, internal carotid artery stenosis and stage III B-cell chronic lymphocytic leukemia. The ophthalmic history was remarkable for cataract surgery and nonproliferative diabetic retinopathy. Her best-corrected visual acuity at presentation was 0.125 in the right eye and 1.0 in the left eye with a positive right relative afferent pupillary defect. Ophthalmoscopic examination revealed right optic disc pallor. Optical coherence tomography of the optic nerve head, visual field tests, and neuroimaging were performed. Computed tomography revealed a right sphenoid sinus filled with hyperdense mass, sclerotic bony walls with erosion, and discontinued sphenoid septum, central wall, roof, and medial optic canal which was indicative of chronic invasive fungal sinusitis. The patient underwent sphenoidotomy to remove the mycotic mass. The patient's vision did not recover.

CONCLUSION: The diagnosis of invasive fungal sinusitis should be suspected in predisposed patients with sinusitis and vision loss or ophthalmoplegia. Due to delays in the diagnosis, it is often too late to save or improve the vision.

CR33**Is it Crohn's or coeliac, or both?**Matilda Sabljak^a, Ana Barišić^{a,b}^a School of Medicine University of Zagreb^b Department of internal diseases; University Hospital Centre Zagreb; School of Medicine University of ZagrebDOI: <https://doi.org/10.26800/LV-144-supl2-CR33> Matilda Sabljak 0000-0002-4433-2635, Ana Barišić 0000-0003-1419-6967

Keywords: Crohn's disease, coeliac disease, lymphoma

INTRODUCTION/OBJECTIVES: Crohn's disease and coeliac disease are chronic disorders that may cause overlapping symptoms: diarrhoea, weight loss, abdominal pain, and fatigue. There are only a few reports in the literature on patients with coexisting coeliac and Crohn's disease.

CASE PRESENTATION: We present a case of a 42-year-old female patient who presented in 2020 with chronic abdominal pain. Laboratory workup revealed elevated CRP and faecal calprotectin levels. Serology for coeliac disease was negative. Upper GI endoscopy revealed gastritis, while duodenal biopsies did not reveal relevant pathological alterations. Colonoscopy with ileoscopy was normal, while histology showed non-specific inflammation within the terminal ileum. Due to persistent abdominal pain accompanied by weight loss, patient was admitted to our hospital in October 2021. Upper endoscopy was performed, and histopathology revealed total villous atrophy, while colonoscopy was normal. Serology for coeliac disease was positive, and the gluten-free diet was started. Small bowel follow-through showed multiple stenoses of ileum, while retrograde single-balloon enteroscopy showed multiple ulcerations in the ileum. Biopsy results confirmed active ileitis, consistent with Crohn's disease, therefore adalimumab therapy was started. Due to further weight loss and symptoms of the bowel obstruction, despite implemented diet and pharmacotherapy, the patient had to undergo exploratory laparotomy, and resection of the stenotic segment of ileum was performed. Histopathological investigation confirmed Crohn's disease, while suspected lymphoma, as a possible complication of coeliac disease, was excluded.

CONCLUSION: The association of coeliac disease and Crohn's disease is possible although rare, which is why this case emphasizes the importance of detailed diagnostic procedure with tissue sampling.

CR34**LARYNX – PRIMARY MANIFESTATION OF T-CELL ACUTE LYMPHOBLASTIC LEUKEMIA**Jelena Benčić^a, Drago Baković^a, Lana Kovač Bilić^b^a School of Medicine University of Zagreb^b University Hospital Centre Zagreb, Department of Otorhinolaryngology and Head and Neck SurgeryDOI: <https://doi.org/10.26800/LV-144-supl2-CR34> Jelena Benčić 0000-0002-2936-5201, Drago Baković 0000-0001-6674-6735, Lana Kovač Bilić 0000-0003-2526-2261

Keywords: extramedullary infiltration, laryngeal neoplasms, laryngostenosis, lymphoblastic leukemia

INTRODUCTION/OBJECTIVES: Laryngeal lymphomas are very rare, and all cases described so far relate to isolated laryngeal lymphomas. We describe the first case of precursor T-cell lymphoblastic leukemia (T-ALL) known to us, which manifests as subglottic stenosis and leads to severe airway obstruction.

CASE PRESENTATION: We present a 37-year-old female patient experiencing dyspnea, without fever, weight loss, and night sweats. Fiber laryngoscopy showed a soft swelling of the subglottis causing the obstruction. CT showed a solid tumor mass in the subglottis that reached intraluminally to the fifth cervical vertebra. Tracheotomy was performed and the tumor was removed with CO2 laser. Pathohistologically, a diagnosis of T-cell non-Hodgkin's lymphoma was made. Solid tumor of the anterior mediastinum was verified on CT of the thorax, abdomen, and pelvis. Bone marrow biopsy showed 30% of blasts typical for T-ALL. The patient began the first cycle of chemotherapy to which an adequate response was not achieved. With the second chemotherapy, remission occurred and fiber laryngoscopy was repeated, showing no tumor in the larynx. As the patient did not have compatible bone marrow donor, autotransplantation of bone marrow was planned. However, after the third cycle of chemotherapy, during the preparation for autotransplantation, the patient died from *P. aeruginosa* sepsis.

CONCLUSION: Extramedullary infiltration by leukemic cells is a rare form of ALL, especially in the larynx. The number of studies on the role of molecular abnormalities in the extramedullary form of ALL is limited and additional efforts are needed to enable faster diagnosis and adequate treatment.

CR35**Lingua villosa nigra – a case report**

Matea Smajić^a, Petra Smajić^{a,b}, Nika Pušeljić^a, Ivanka Muršić^{a,c}, Lada Zibar^{a,d}


^a Faculty of Medicine, J. J. Strossmayer University of Osijek, Osijek, Croatia,

^b Clinical Hospital Centre Osijek, Department of Infectious Diseases, Osijek, Croatia

^c Clinical Hospital Centre Osijek, Department of Dermatology and Venereology, Osijek, Croatia,

^d University Hospital Merkur, Department of Nephrology, Zagreb, Croatia

DOI: <https://doi.org/10.26800/LV-144-supl2-CR35>

 Matea Smajić 0000-0001-7448-3349, Petra Smajić 0000-0002-7015-713X, Nika Pušeljić 0000-0002-0626-4651, Ivanka Muršić 0000-0003-3247-1002, Lada Zibar 0000-0002-5454-2353

Keywords: COVID-19, ertapenem, immunosuppression, lingua villosa nigra

INTRODUCTION/OBJECTIVES: Lingua villosa nigra (LVN) is benign hairy appearance of the dorsal surface of the tongue, caused by defective desquamation and reactive hypertrophy of the filiform papillae. It is mostly related to poor oral hygiene, antibiotics, smoking and specific food/drink.

CASE PRESENTATION: 54-year old kidney transplant patient experienced hairy tongue changes after a mild form of COVID-19 (coronavirus disease). After the kidney transplantation in 2020, she takes immunosuppressive drugs (tacrolimus and mycophenolate mofetil), have excellent kidney function (creatininemia 60 μmol/L) but suffers from recurrent urinary tract infections (UTIs). During her COVID-19, she was treated with ertapenem for an UTI relapse. Two days after the therapy cessation, she noticed hairy brown changes on her tongue after feeling as a food stuck on the surface of the tongue. LVN caused by fungal infection was diagnosed. She is a cigarette smoker, takes a glass of red wine and a cup of black coffee daily. She does oral hygiene regularly. LVN was treated by peroral fluconazol 50 mg daily and myconazolnitrate oral gel topically for 7 days, with gentle scraping of the tongue and the changes withdrew except at the tongue root. However, after she stopped taking the therapy, the LVN relapsed.

CONCLUSION: We presented a rare case of LVN in kidney transplant immunosuppressed patient. Ertapenem in combination with her daily habits could have induced LVN and fungal infection of the tongue. Persistence of this condition is usual, thus it is important to take a long lasting antifungal therapy and scrap the tongue regularly.

CR36**Long lasting tinnitus and vertigo as a result of a facial nerve anomaly – A CASE REPORT**

Marinko Grgić^a, Marin Glavčić^b, Kristijan Harak^c

^a Health Center of Varaždin County

^b Institute for Emergency Medicine of Split-Dalmatia County

^c Health Center of Zagreb County

DOI: <https://doi.org/10.26800/LV-144-supl2-CR36>


 Marinko Grgić 0000-0003-2402-7147, Marin Glavčić 0000-0002-9065-4010, Kristijan Harak 000-0002-1501-1955

Keywords: stapedotomy, tinnitus, vertigo

INTRODUCTION/OBJECTIVES: A 34-year-old patient was admitted to a general practice due to tinnitus and vertigo. After no pathological features were found during the examination in primary practice, he was referred to an otorhinolaryngologist.

CASE PRESENTATION: The patient presented for the first time with occasional tinnitus, dizziness, and vertigo lasting for eight months. The patient was examined by an otorhinolaryngologist who found a swollen nasal mucosa and a deviated septum and began treating the case as chronic nasopharyngitis with nasal corticosteroids. The audiogram did not show hearing loss. Magnetic resonance imaging with angiography did not detect any pathological formations. At that time, further examination was suggested, but the patient is not inclined to do so due to subjective improvement. Two years later, the patient reports to the doctor again due to left-sided hearing loss. The cochleaostapedal reflex was absent and the audiogram showed mixed hearing impairment on the left. Due to this finding, it was decided to perform an exploratory procedure of the left ear and a possible stapedotomy due to the suspicion of otosclerosis. During the procedure, an anomaly of the facial nerve was observed, which was positioned over the stapes plate. A stapedotomy is abandoned and the perichondrium of the tragus is taken and an underlay was placed. On a control audiogram three weeks after surgery, the patient's hearing improved with mild persistence of mixed hearing loss.

CONCLUSION: Although facialis anomaly is not common, it can cause conductive hearing loss, and this possibility should be considered in differential diagnoses.

CR37**Low back pain - an unusual presentation of acute lymphoblastic leukemia in a child – a case report**Kiarash Pourmodjib^a, Zrinko Šalek^{a,b}, Ernest Bilić^{a,b}^a School of Medicine University of Zagreb^b Division for Pediatric Hematology/Oncology, Department of Pediatrics; University Hospital Centre ZagrebDOI: <https://doi.org/10.26800/LV-144-supl2-CR37> Kiarash Pourmodjib 0000-0003-1241-537X, Zrinko Šalek 0000-0002-1279-4974, Ernest Bilić

Keywords: ALL, chemotherapy, LDH, pancytopenia, sacroileitis

INTRODUCTION/OBJECTIVES: Acute lymphoblastic leukemia is the most common malignant disease in children. Common initial symptoms are fatigue, pallor, bleeding tendency and bone pain. Laboratory findings show cytopenia with or without leukocytosis and often elevated lactate dehydrogenase. First line therapy is corticosteroids, chemotherapy and in high-risk cases with non - favorable outcome hematopoietic stem cells transplantation.

CASE PRESENTATION: A 9.5-year-old girl initially presented with back pain. She had immense pain after she fell during physical activity. Her pain increased so that she was physically restricted. First the orthopaedic diagnosed the child with asymmetrical pelvis and treated the patient conservatively, which didn't help. In the next weeks she had severe thoracolumbar spine pain, that spread to the right side of the abdomen. One month from beginning of the low back pain, she was admitted in the hospital. The MRI of the thoracolumbar region showed signs of spondylitis and stress fractures. Scintigraphy showed inhomogeneous pronounced accumulation of radionuclides in regions Th10 and Th11. The findings of pancytopenia and moderate increase in ESR, raised the suspicion of lymphoproliferative disease. Bone marrow aspiration confirmed the diagnosis of ALL. FISH showed chromosome 21 tetrasomy in 51% of interphase nuclei and ETV6 gene deletion in 33% interphase cores, while PCR showed the IgH clonality. LDH values were normal. Two months after the diagnosis our patient is in good condition, in first complete remission after induction treatment.

CONCLUSION: This case report presented an ALL patient with normal LDH values and pancytopenia. The low back pain delayed the decision about the correct diagnosis.


CR38**Meningoencephalic herniation of the temporal bone**Stela Marković^a, Josipa Živko^b, Mislav Malić^c^a University of Zagreb School of Medicine, Zagreb, Croatia^b Clinical hospital „Dubrava“, Zagreb, Croatia^c Department of ENT and H&N Surgery, University Hospital Centre „Zagreb“, Zagreb, CroatiaDOI: <https://doi.org/10.26800/LV-144-supl2-CR38> Stela Marković 0000-0003-2149-2422, Josipa Živko 0000-0001-7297-5366, Mislav Malić 0000-0003-3260-5146




Keywords: cranial meningoencephalocele, mastoidectomy, otitis media with effusion, tympanoplasty

INTRODUCTION/OBJECTIVES: Meningoencephalocele is a potentially life-threatening condition in which meningeal or encephalic tissue is herniated into the middle ear or mastoid through the bony defect in the tegmen plate.

CASE PRESENTATION: A 55-year-old woman presented to the ENT department with a headache around the left ear, ear fullness, and conductive hearing loss. She had previously had a tympanomastoidectomy two years ago. Otoscopy showed effusion behind the intact tympanic membrane. Although more common conditions such as otitis media with effusion or eustachian tube dysfunction present with such symptoms, a history of salty taste in her mouth lead us to suspicion of iatrogenic meningoencephalocele. The diagnosis of brain tissue herniation was confirmed via radiographic imaging. She was treated surgically with a reconstruction of the skull base defect and made a full recovery.

CONCLUSION: This condition is rare and serious and one has to be suspicious when there is otitis media with effusion in a previously operated ear. Potential complications include cerebrospinal fluid leak, epilepsy and intracranial infection. The treatment of choice is surgery and the approach is chosen depending on the size of the bone defect.



CR39**Multifragmental orbital floor blowout fracture followed by car accident and treatment with prolene mesh**Lovro Kovač^a, Nikolina Bajlo^a^a *Medicinski fakultet Sveučilišta u Rijeci*DOI: <https://doi.org/10.26800/LV-144-supl2-CR39> Lovro Kovač 0000-0001-5718-8364, Nikolina Bajlo 0000-0002-5100-2423**Keywords:** blowout orbital floor fracture, multifragmental fracture of nasal bone, musculus rectus inferior entrapment**INTRODUCTION/OBJECTIVES:** Most common orbital fracture is blowout fracture and it is often result of trauma in which object that hits eyeball transfers force to it and indirectly to orbital floor (medial of sulcus infraorbitalis) which is the "locus minoris resistentiae" of orbital walls. Result of floor trauma is orbital fat tissue prolaps into the maxillary sinus which is commonly followed with inferior rectus muscle prolapse. Real-life example of trauma whose mechanism is explained in this section will be topic of this case report.**CASE PRESENTATION:** In this work, we describe 23-year-old male Croatian patient who suffered a blowout fracture of the orbital floor after a car accident. After he was admitted to the ER and when were life-threatening conditions eliminated the patient was moved to the otorhinolaryngology department where intubation occurs due suspicious naso-orbital trauma that caused low oxygen saturation. Imaging showed a multifragmental fracture of the left orbit bottom and nasal bones that were surgically repaired with prolene mesh.**CONCLUSION:** This report demonstrates manifestation of orbital floor blowout trauma and consequent treatment with prolene mesh which effectiveness is followed-up by examination one month after accident.**CR40****Multiple primary tumours: papillary thyroid carcinoma, chronic lymphocytic leukemia (CLL) and Non-Hodgkin mantle cell lymphoma in a male patient**David Glavaš Weinberger^a, Mihael Grzelja^a, Inga Mandac Smoljanović^{a,b}^a *School of Medicine University of Zagreb*^b *Department of Hematology, Clinical Hospital Merkur, Zagreb*DOI: <https://doi.org/10.26800/LV-144-supl2-CR40> David Glavaš Weinberger 0000-0003-4671-7499, Mihael Grzelja 0000-0003-1973-3506, Inga Mandac Smoljanović 0000-0001-5234-9464**Keywords:** B-CLL, mantle cell lymphoma, multiple primary tumours, papillary thyroid carcinoma**INTRODUCTION/OBJECTIVES:** Multiple primary tumours (MPM) are defined as more than one synchronous cancer in the same patient. Lymphoma and thyroid cancer are common individually, although they rarely present synchronously. Papillary thyroid carcinoma (PTC) has been associated with the radiotherapeutic treatment of Hodgkin's lymphoma. Concomitant chronic lymphocytic leukaemia (B- CLL) and mantle cell lymphoma (MCL) is rare combination where a multiparametric approach is necessary to diagnose two distinct cell populations at the same time.**CASE PRESENTATION:** A 63-year-old man, with prior history of hyperthyroidism, was admitted to the ENT department for diagnostics and treatment of a thyroid nodule. Fine needle aspiration (FNA) of the thyroid confirmed the diagnosis of PTC, while FNA of the cervical lymph node showed lymphocyte proliferation. Laboratory tests showed lymphocytosis. Flow cytometry indicated both B-CLL/MCL phenotype. Biopsy of the lymph node and bone marrow displayed lymphoproliferative infiltrate with 95% small lymphocytic lymphoma (SLL) and 5% MCL. Complete thyroidectomy and lymphadenectomy were performed, the patient was further referred for diagnostics and radioiodine therapy. His CLL and MCL have continued to be ambulatory followed up, without the need for treatment.**CONCLUSION:** While lymphomas typically occur alone, patients with a history of CLL/SLL have an increased risk of developing other malignancies. Flow cytometry is of great importance in patients suspected for synchronous lymphoproliferative disorders. It is unknown whether the occurrence of a composite lymphoma is a coincidence or if their etiology is common. Although MPMs are rare, this case highlights the need to consider and investigate certain patient populations at a higher risk for developing MPMs.


CR41**New Variant of Unknown Significance found in ERCC6 gene -Cerebro-oculo-facio-skeletal syndrome**

Nika Pušeljić^a, Ivana Jurić^a, Matea Smajić^a, Silvija Pušeljić^b

^a Faculty of Medicine, University of Osijek

^b Division of Neurology, Genetic, Metabolic disease and Endocrinology, Department of Pediatrics, University Hospital Center

DOI: <https://doi.org/10.26800/LV-144-supl2-CR41>

 Nika Pušeljić 0000-0002-0626-4651, Ivana Jurić 0000-0002-2332-8055, Matea Smajić 0000-0001-7448-3349, Silvija Pušeljić 0000-0002- 9500-2185

Keywords: Cerebro-oculo-facio-skeletal syndrome, ERCC6, Whole Exome Sequencing

INTRODUCTION/OBJECTIVES: Cerebro-oculo-facio-skeletal syndrome (COFS) is a genetic disorder caused by a mutation of the DNA repair genes presenting with severe sensorineural involvement. The aim was to present a possible new pathogen mutation in the ERCC6 gene responsible for the clinical presentation of COFS.

CASE PRESENTATION: We present an 18 months old boy of healthy non-consanguine parents, born from the first pregnancy with perinatal risk factors in whom phenotypic dysmorphism has been observed at birth. Phenotypic features include microcephaly, left occipital plagiocephaly, deeply implanted small eyes, blepharophimosis, the tuberous tip of the nose, longer filter, gothic palate, left ear without cartilage, microrotorgnancy, wide-set nipples, furrow 4 fingers right palm, clenched fists, and knee contracture. Clinically presenting with global psychomotor delay showed as possible gyration disorder on ultrasound of the brain, and cortical atrophy on magnetic resonance. Genetic processing was started with karyotyping, which excluded chromosomopathies and Chromosomal Microarray Analysis also didn't show changes. Whole Exome Sequencing shows a Variant of unknown significance (VOUS) in the ERCC6 (10-50708680-A G gene; c.1589T> C). Individuals with COFS and ERCC6 mutation are sometimes considered as having Cockayne Syndrome Type II.

CONCLUSION: This mutation hasn't been described yet, and the currently available database is not sufficient to link variation to COFS. Due to the clinical presentation of this patient, there is a clinically reasonable suspicion that hat it is a new mutation of the ERCC6 gene that could potentially be pathogenic. Parental testing should also be done to classify the variant and confirm the pattern of segregation.


CR42**Nusinersen treatment in SMA type III: treating an adult patient**

David Preložiček^a, Dora Meštrović^a, Lucija Mihaljević^a, Martina Petrinović^a, Ervina Bilić^{a,b}

^a School of Medicine University of Zagreb

^b Department of neurology, University Hospital Center Zagreb; School of Medicine University of Zagreb

DOI: <https://doi.org/10.26800/LV-144-supl2-CR42>

 David Preložiček 0000-0003-1762-666X, Dora Meštrović 0000-0002-3079-5209, Lucija Mihaljević 0000-0002-6114-1902, Martina Petrinović 0000-0002-3456-0968, Ervina Bilić 0000-0003-4466-6528

Keywords: nusinersen, Revised Hammersmith Scale, spinal muscular atrophy

INTRODUCTION/OBJECTIVES: Spinal muscular atrophy (SMA) is a rare disorder which presents as a loss of (spinal) lower motor neuron with consequential muscular atrophy. It is caused by absence of SMN1 gene on chromosome 5 due to exon 7, or additionally exon 8, deletion. Presence or absence of SMN2 and NAIP genes determine the severity and time of onset of the disease. SMA is divided in 5 types ranging from 0 to 4 with 0 being the most severe with the earliest time of onset and 4 being the mildest with the latest time of onset.

CASE PRESENTATION: A 30-year-old female patient was admitted for nusinersen treatment. Patient was diagnosed with SMA type III at the age of 3 years with the exact chromosomal abnormalities confirmed via molecular genetic testing 2 years prior to the start of the treatment. Efficacy of the treatment was evaluated by Revised Hammersmith Scale (RHS) and Revised Upper Limb Module (RULM). The results before treatment were 29/69 RHS and RULM 43/43. Walking difficulties were the most prominent symptom prior to the therapy. After six primary doses, results were 39/69 RHS and RULM 43/43, with patient showing remarkable improvement especially regarding walking on her own.

CONCLUSION: Nusinersen can be effective at treating SMA type III in adult age. It modulates alternative splicing of the SMN2 gene, functionally converting it into an SMN1 gene. The patient has shown improvement and will continue the treatment with maintenance doses each 4 months should there be no stopping criteria met.


CR43**Open surgical treatment of malperfusion syndrome in Stanford B aortic dissection**Stjepan Pinotić^a, Zlata Pinotić^a, Krešimir Pinotić^b^a Faculty of Medicine; Josip Juraj Strossmayer University of Osijek^b Division for Vascular Surgery; Department of Surgery; University Hospital Centre OsijekDOI: <https://doi.org/10.26800/LV-144-supl2-CR43> Stjepan Pinotić 0000-0002-8825-6291, Zlata Pinotić 0000-0001-6329-3611, Krešimir Pinotić 0000-0003-4559-5485

Keywords: Dissection, Malperfusion, Surgery

INTRODUCTION/OBJECTIVES: Aortic dissection is a life-threatening condition in which a tear occurs in the intima of the aorta. There are two types of aortic dissection, Stanford A and B. Stanford B aortic dissection involves the descending aorta and is treated by lowering blood pressure (BP), with surgery being reserved for complications, such as malperfusion syndrome.

CASE PRESENTATION: We report a case of a 46-year-old male with Stanford B aortic dissection with malperfusion syndrome of the right common iliac artery (RCIA). The diagnosis was made based on his symptoms, which included sudden severe chest pain spreading to the abdomen and paresthesia of his right leg. Physical examination was remarkable for paleness and pulselessness of the right leg, which suggested malperfusion of the RCIA. After stabilizing his BP and confirming the diagnosis on CT angiography, an emergency laparotomy with fenestration, excision, and fixation of the intima of the abdominal aorta was performed. The outer aortic wall was then closed over Teflon felt. Additional thrombectomy of both common iliac arteries ensured the patient's right leg reperfusion. Two weeks later he underwent elective Thoracic Endovascular Aortic Repair (TEVAR), which was performed to secure the long-term anatomic benefit. He was later discharged from the hospital, suffering no surgical complications, and was prescribed antihypertensive therapy.

CONCLUSION: Malperfusion syndrome is the second most common complication of aortic dissection and it requires immediate surgical treatment. In this case, the open surgical procedure with supplemental elective TEVAR proved to be a viable alternative treatment option to the recommended Endovascular Fenestration.

CR44**The importance of long-term treatment of cholesteatoma**Vana Stojić^a, Tea Štrbac^b, Stjepan Frkanec^c, Andro Košec^{c,d}^a Department of Emergency Medicine of Zagreb County, Zagreb, Croatia^b Emergency Department, General Hospital Zabok and Hospital of Croatian Veterans, Zabok, Croatia^c University of Zagreb, School of Medicine, Zagreb, Croatia^d Otorhinolaryngology and Head and Neck Surgery, University Hospital Centre "Sestre Milosrdnice"DOI: <https://doi.org/10.26800/LV-144-supl2-CR44> Vana Stojić 0000-0001-6678-3878, Tea Štrbac 0000-0001-8171-8281, Stjepan Frkanec 0000-0003-2309-3783, Andro Košec 0000-0001-7864-2060

Keywords: Cholesteatoma, hearing, TORP

INTRODUCTION/OBJECTIVES: Cholesteatoma is a benign epithelial lesion within the middle ear or mastoid air cell spaces. It acts locally destructive, may be congenital, but is usually acquired and caused by chronic otitis media. Conductive hearing loss is a symptom, but may also be a result of surgery aimed at cholesteatoma removal. There are multiple surgical strategies aimed at hearing restoration.

CASE PRESENTATION: We present a patient that underwent total of 4 surgeries in period of 4 years. He presented with conductive hearing loss of 50-85 dB on the right and 50-75dB on the left side prior to treatment. Destruction of all three ear ossicles was present in both ears. Firstly, the surgical removal of cholesteatoma was performed in each ear via closed technique tympanomastoidectomy. Postoperatively, the patient was fitted with hearing aids to be able to function in daily activities due to profound conductive hearing loss. After residual or recurrent disease was excluded, total ossicular replacement prostheses (TORP) were implanted in both ears. Initial results were still poor due to a challenging postoperative anatomical setting and prostheses migration. Finally, two years later, successful insertions of TORPs with reinforced cartilage grafts in were performed bilaterally and the result was bilateral normacusis.

CONCLUSION: This amazing outcome of hearing and, consequently, life quality is a result of appropriate surgical strategy and patience. Long term follow-up is essential in treating chronic ear disease with hearing loss, and staged surgeries should always be attempted until all options are exhausted.


CR45**Tubulointerstitial Nephritis in a Patient with Ulcerative Colitis**Adriana Adamović^a, Ivica Horvatić^b^a School of Medicine, University of Zagreb, Salata 3, 10000 Zagreb, Croatia^b Department of Nephrology, Clinical Hospital Dubrava, 10000 Zagreb, CroatiaDOI: <https://doi.org/10.26800/LV-144-supl2-CR45> Adriana Adamović 0000-0002-2978-0632, Ivica Horvatić 0000-0001-9050-5747

Keywords: mesalazine, tubulointerstitial nephritis, ulcerative colitis

INTRODUCTION/OBJECTIVES: Ulcerative colitis (UC) is a chronic inflammatory bowel disease that affects rectum or extends to other parts of the colon. It has a relapsing and remitting course, usually extending over years. It also has extra-intestinal manifestations, including renal, like tubulointerstitial nephritis (TIN). TIN is an inflammatory disease that affects renal tubules and the interstitium. Other causes include drugs and toxins. The first line of treatment for UC is 5-aminosalicylic acid (mesalazine). One of the rare complications of mesalazine is also TIN.

CASE PRESENTATION: A 24-year-old male with past medical history of UC was referred to nephrology department because of an elevated serum creatinine level (530 $\mu\text{mol/L}$, normal range 64-104 $\mu\text{mol/L}$), with unremarkable urinalysis. UC was diagnosed two years before and since then he has been on oral mesalazine. Renal biopsy showed interstitial fibrosis and tubular atrophy with inflammatory infiltration in 90% of the parenchyma. Possible differential diagnosis was TIN due to mesalazine. Mesalazine has been left out of therapy and has been replaced with methylprednisolone (dose 0.5mg/kg/day). After a few months, levels of creatinine significantly decreased (259 $\mu\text{mol/L}$). Methylprednisolone was gradually tapered to a dose of 4-8mg/day with stagnant levels of creatininemia.

CONCLUSION: Chronic kidney disease caused by TIN remains a significant finding in patients with UC. It is a diagnostic and therapeutic challenge, since it could be a consequence of mesalazine therapy or an extra-intestinal manifestation of UC. In patients with UC, renal function parameters (serum creatinine and urine) should be monitored regularly.


CR46**Upper GI bleeding in a patient with rare inherited bleeding Disorder – a case report**Nora Knez^a, Tin Rosan^a, Nikolina Novak^a, Ana Mrzljak^b, Dražen Pulanić^b^a School of Medicine University of Zagreb^b University Hospital Centre ZagrebDOI: <https://doi.org/10.26800/LV-144-supl2-CR46> Nora Knez 0000-0002-4933-4947, Tin Rosan 0000-0002-7585-5770, Nikolina Novak 0000-0001-7416-7805, Anna Mrzljak 0000-0001-6270-230, Dražen Pulanić 0000-0002-1177-8921

Keywords: bleeding, gastrointestinal, Glanzmann's thrombasthenia, thrombocytopenia

INTRODUCTION/OBJECTIVES: Glanzmann thrombasthenia (GT) is a rare inherited thrombocytopathy characterized by insufficient platelet aggregation and normal platelet count. The genetic molecular feature of GT is deficiency or dysfunction of the platelet integrin $\alpha\text{IIb}\beta\text{3}$ (CD41/CD61) receptor for fibrinogen, resulting in bleeding episodes of varying severity. In general, the presence of mucocutaneous bleeding and a normal platelet count raise the suspicion of this disorder. We report a case of gastrointestinal (GI) bleeding in a patient with GT.

CASE PRESENTATION: A 56-year-old woman was admitted due to melena. Her past medical history revealed GT and severe menorrhagia. Her physical examination was unremarkable. Her laboratory results showed normal platelet count (261 $\times 10^9/\text{L}$), iron deficiency anemia (Hb 80 g/L; Fe 6 $\mu\text{mol/L}$, ferritin 18,4 $\mu\text{g/L}$), normal fibrinogen (3,3 g/L), PT (0.99) and APTT (21.6 seconds). Flow cytometry revealed reduced surface expression of CD41 (0,5%) and CD61 (0.5%). Her upper endoscopy (UE) was unremarkable; colonoscopy showed old traces of blood, while capsule endoscopy revealed some fresh post-bulbar bleeding. Repeated UE showed active arterial duodenal bleeding and the hemostasis was successfully achieved by clipping. Because of anemia red blood cells transfusion and intravenous iron supplementation were administered. Hemostasis was achieved with platelet transfusions, along with tranexamic acid. In addition, lower factor XIII (FXIII) level was detected which was supplemented as well.

CONCLUSION: GT is a rare inherited bleeding disorder characterized by impaired platelet aggregation. Therapy is supportive and essential in acute or chronic bleeding and in preoperative management. GI bleeding in GT patients is challenging and requires a combination of different modalities.


CR47**DIAGNOSIS AND MANAGEMENT OF TUMOR LYSIS SYNDROME IN A 10-YEAR-OLD PATIENT**Marin Boban^a, Matej Jelić^b^a School of Medicine, University of Zagreb^b University Hospital Centre Zagreb, Department of Pediatrics, Division of Hematology and Oncology, ZagrebDOI: <https://doi.org/10.26800/LV-144-supl2-CR47> Marin Boban 0000-0002-5552-0295, Matej Jelić 0000-0001-6685-180X

Keywords: Burkitt's, lymphoma, Non-Hodgkin, Tumor lysis syndrome

INTRODUCTION/OBJECTIVES: Burkitt's lymphoma is a highly aggressive B-cell non-Hodgkin lymphoma characterized by the translocation of the MYC gene on chromosome 8. Tumor lysis syndrome (TLS) is an oncologic emergency condition resulting from rapid tumor cell death and release into the bloodstream.

CASE PRESENTATION: A 10-year-old boy was admitted due to suspicion of an ongoing malignant process. Laboratory data showed a hyperleukocytosis (WBC 39.7 x10⁹/L), thrombocytopenia (platelets 27x10⁹/L), anemia (hemoglobin 88 g/L), elevated lactate dehydrogenase (LDH 10510 U/L). A bone marrow aspiration was performed and diagnosis of Burkitt's lymphoma was established. After initiating treatment according to protocol NHL-BFM-2012 with pre-phase to reduce tumor mass, patient laboratory data showed elevated potassium (4.7 mmol/L), elevated uric acid (24.4 mmol/L), and LDH kept rising to a level of 15100 U/L. Also, early signs of damaged kidney function were noticed which included oliguria and elevated creatinine levels (277 umol/L). Patient was transferred into ICU where he immediately started taking rasburicase along with pre-phase. Treatment with rasburicase lasted for 8 days. During the patient's stay at ICU, other signs of TLS occurred, including hyperphosphatemia and hypocalcemia, but with no seizures or cardiac symptoms so we decided not to treat hypocalcemia.

CONCLUSION: Since it is an oncologic emergency, especially in patients with diagnosis of NHL, it is crucial to anticipate the risk and recognize early signs of tumor lysis syndrome and proceed with decision making according to the grade of TLS. It is challenging to treat electrolyte imbalance in patient with TLS owing to the risk of crystallizing calcium phosphate.

CR48**Endogenous Endophthalmitis with Panophthalmitis – case report**Petra Kovačević^a, Matej Lovrić^a, Nika Samardžić^a, Martina Lukšić^b, Jelena Juri Mandić^{a,c}^a School of Medicine University of Mostar^b Medical School University of Zagreb^c Department of Ophthalmology, University Hospital Centre ZagrebDOI: <https://doi.org/10.26800/LV-144-supl2-CR48> Petra Kovačević 0000-0001-5449-3427, Matej Lovrić 0000-0001-9882-2632, Nika Samardžić 0000-0002-1423-8453, Martina Lukšić 0000-0002-8933-3930, Jelena Juri Mandić 0000-0003-0211-7491

Keywords: endophthalmitis, panophthalmitis, hematogenous dissemination

INTRODUCTION/OBJECTIVES: Endophthalmitis is defined as inflammation of the internal ocular structures and it could be of exogenous or endogenous origin. Endogenous bacterial endophthalmitis (EBE) accounts for about 2%-6% of all cases and occurs during bacteremia when infective agent penetrates the blood-ocular barriers. Endogenous panophthalmitis (EP) results in the most extensive ocular involvement with inflammation of periocular tissues. All therapeutic options are aimed to stop the spreading of infective inflammation from orbital space into cavernous sinus and is considered to be a life saving treatment.

CASE PRESENTATION: We report a case of endogenous endophthalmitis and panophthalmitis. A 80-year-old female patient presented with amaurosis and pain in the left eye. She was previously hospitalized and treated for diabetes mellitus and epigastric pain, and hematemesis. Ocular symptoms occurred subsequently seven days later. After complete diagnostic work up and conservative treatment urgent enucleation was required.

CONCLUSION: EP and EBE is a rare, life-threatening disease which require rapid and accurate treatment. Diabetes mellitus could predispose its development. The conditions should be suspected in older patients with comorbidities and without trauma or surgery in medical history. A multidisciplinary approach is needed.


CR49**External fixation with a locking plate for a tibial fracture complicated by osteomyelitis: a case report**Lea Kalajžić^a, Tin Karakaš^a, Maša Kopusar^b, Srećko Sabalić^c^a School of Medicine, University of Zagreb^b School of Medicine, University of Rijeka^c Department of Traumatology, "Sestre Milosrdnice" University Hospital CenterDOI: <https://doi.org/10.26800/LV-144-supl2-CR49> Lea Kalajžić 0000-0002-4824-021X, Tin Karakaš 0000-0001-6504-0669, Maša Kopusar 0000-0001-5910-9826, Srećko Sabalić 0000-0003-0070-5206

Keywords: external fixation, locking plate fixation, osteomyelitis

INTRODUCTION/OBJECTIVES: External fixation using a locking plate is an uncommon approach, however good clinical outcomes have been reported in the literature so far. It provides certain benefits over conventional external fixators, which hinder everyday activities due to their bulkiness. Aside from being more convenient for the patient, external fixation with locking plate results in less soft tissue trauma, low-profile stable fixation and shortened hospital stay.

CASE PRESENTATION: We present a 41-year-old male patient who sustained a tibial shaft fracture, treated with open reduction and internal fixation (ORIF) with plate and screws, complicated by osteomyelitis. A decision to treat by external locking plate fixation was made due to severity of infection and compromised soft tissue envelope. Microbiological analysis of a bone biopsy sample was positive for *Staphylococcus aureus*. Infection was initially treated with cloxacillin and rifampicin intravenously for two weeks, followed by ten-week oral course of trimethoprim-sulfamethoxazole and rifampicin. The locking plate was removed six months post-operatively, after patient showed signs of bone healing and complete absence of bone infection. On a six-month follow-up, patient ambulates without assistance and is completely pain free.

CONCLUSION: This case report supports external locking plate fixation as a treatment option for a selected population of patients. Evidence concerning the biomechanical characteristics of external locking plate fixation is still inadequate to support the clinical use, therefore more robust studies are required.

CR50**Facial nerve paralysis caused by a parotid haemangioma: a case report**Antonia Bukovac^a, Marko Velimir Grgić^b, Luka Bukovac^a, Branimir Bradarić-Šlujo^a, Gabrijel Buljan^a, Anton Malbašić^a^a School of Medicine, University of Zagreb^b Clinical Department of Otolaryngology and Head and Neck Surgery, University Hospital Centre "Sestre Milosrdnice", Zagreb, CroatiaDOI: <https://doi.org/10.26800/LV-144-supl2-CR50> Antonia Bukovac 0000-0002-0412-433X, Marko Velimir Grgić 0000-0003-4196-5303, Luka Bukovac 0000-0001-7559-7137, Branimir Bradarić-Šlujo 0000-0002-4261-724X, Gabrijela Buljan 0000-0003-4060-9497, Anton Malbašić 0000-0002-8699-8662

Keywords: facial paralysis, haemangioma, parotid gland

INTRODUCTION/OBJECTIVES: Haemangiomas, benign vascular tumors, are the most common tumor found in children. They can occur in any location including the salivary glands, most often the parotid. Most haemangiomas involute spontaneously, requiring only conservative management. Active treatment of parotid haemangiomas is needed in the rare case of disfigurement, airway obstruction, hemorrhaging or other severe complications.

CASE PRESENTATION: The patient is an 11-year-old girl first presenting with a palpable mass in her right parotid causing pain and discomfort which measured approximately 3,5 cm. A following MRI scan supported the diagnosis of a haemangioma permeating throughout the parotid. Surgical treatment was indicated, but the tumors large size determined a high risk of intraoperative facial nerve damage. To combat this, the patient underwent angiography and embolization. Instead of an expected reduction, the haemangioma continued to expand which lead to facial asymmetry and weakness with periods of intense pain. This resulted in a right facial palsy House-Brackmann grade III. The patient then underwent surgery to remove the haemangioma and to repair the facial nerve. A pathohistological diagnosis of intraoperative samples confirmed a haemangioma. Following the procedure, the patient developed a right facial palsy House-Brackmann grade VI but retained the ability to blink. The degree of the patients future functional recovery remains uncertain.

CONCLUSION: Haemangiomas are most commonly a benign condition, but some cases can lead to severe complications. Every case must be carefully assessed and all possible outcomes must be taken into consideration, such as facial paralysis.


CR51**Follow up of uveal melanoma - case report**

Matej Lovrić^a, Petra Kovačević^a, Dario Vučić^a, Franciska Lovrić^a, Suzana Konjovoda^b

^a School of Medicine, University of Mostar, Bosnia and Herzegovina

^b Department of Ophthalmology and Optometrics; General Hospital Zadar, Department of Health Studies, University of Zadar, Croatia

DOI: <https://doi.org/10.26800/LV-144-supl2-CR51>

 Matej Lovrić 0000-0001-9882-263, Petra Kovačević 0000-0001-5449-3427, Dario Vučić 0000-0002-1687-5261, Franciska Lovrić 0000-0001-5008-8934, Suzana Konjevoda MD PhD 0000-0003-3979-6790

Keywords: brachitherapy, choroidal nevus, uveal melanoma

INTRODUCTION/OBJECTIVES: Uveal melanoma (UM) is the most common primary intraocular malignancy in adults. Ocular treatment aims at preserving the eye and vision, and preventing metastases. Enucleation has largely been superseded by various forms of radiotherapy, phototherapy and local tumor resection, often combined. Almost half of patients develop metastases, which usually involve the liver, and have around 1 year like expectancy.

CASE PRESENTATION: A 72-year-old man has presented with gradual painless blurred vision of the right eye in the last 2 months. A complete ophthalmological examination was performed including ocular sonography. Patient was diagnosed with paramacular choroidal melanoma of the right eye. The patient was treated with brachytherapy. Patient underwent computed tomography examination for assessment of systemic metastasis. One year later, patient was diagnosed with an atypical choroidal nevus in the macular area on the left eye. We decided to do a follow up the nevus before beginning a new treatment.

CONCLUSION: Bilateral ophthalmological malignancy is very rare, but must not be underestimated. Examinations of both eyes are essential. Early diagnosis and care improve the survival and the visual prognosis.


CR52**CASE REPORT: GLOMUS JUGULOTYMPANICUM**

Andro Košec^{a,b}, Josip Prnjak^a

^a Department of Otorhinolaryngology and Head and Neck Surgery, University Hospital Centar „Sestre Milosrdnice“

^b University of Zagreb, School of Medicine

DOI: <https://doi.org/10.26800/LV-144-supl2-CR52>

 Andro Košec 0000-0001-7864-2060, Josip Prnjak 0000-0001-8100-6890

Keywords: Fisch classification, glomus tumor, infratemporal fossa approach type A

INTRODUCTION/OBJECTIVES: Paragangliomas or glomus tumors arise from neural crest derivatives of the autonomic nervous system. They account for 0,6% of all head and neck tumors. Glomus jugulare tumors are located in the jugular foramen and are derivatives of the paraganglia in the jugular bulb adventitia. Glomus jugulotympanicum is the term that describes a tumor that has spread into the middle ear cavity.

CASE PRESENTATION: 72- year old female patient presented with a sudden onset of right facial nerve paresis that happened two months ago, scored III/VI on House-Brackmann scale. She has also been complaining about unilateral right-sided hearing loss for years. A month prior to her appointment, a myringotomy was done in a different facility due to conductive hearing loss. She noticed a purulent discharge leaking after the procedure. A physical exam showed a purulent discharge in the right auditory canal and pulsations from the frontal quadrants of the eardrum. PTA showed severe mixed hearing loss on the right side. MDCT angiography discovered an expansile lesion arising from the jugular bulb infiltrating the tympanic cavity, consistent with the glomus jugulotympanicum tumor.

CONCLUSION: Glomus tumors are highly vascularised and preoperative embolization is needed. Infratemporal fossa Fisch type A approach is a preferred surgical technique for treatment of the glomus jugulare tumors.


CR53**Immunotherapy and Gamma knife "stop and go" therapy in a mRCC patient**

Nikolina Novak^a, Marija Gamulin^{a,b}, Tin Rosan^a, Nora Knez^a

^a School of Medicine, University of Zagreb

^b Unit for Uro-Oncology, Department of Oncology, University Hospital Centre Zagreb

DOI: <https://doi.org/10.26800/LV-144-supl2-CR53>

 Nikolina Novak 0000-0001-7416-7805, Marija Gamulin 0000-0003-2431-7910, Tin Rosan 0000-0002-7585-5770, Nora Knez 0000-0002-4933-4947

Keywords: gamma knife, kidney cancer, metastasis, nivolumab, sunitinib

INTRODUCTION/OBJECTIVES: Incidence of kidney cancer is 3 % of the overall population, with most common type being clear cell kidney carcinoma (mccRCC). Our objective is to report a successful treatment of mccRCC with long survival.

CASE PRESENTATION: The patient is a 78-year-old man, ECOG 0 with hypertension, diagnosed with a left kidney ccRCC stage III (T3N0M0) in 2008. A left nephrectomy was performed. In 2010 PETCT-FDG showed lung and right kidney metastases. As our patient belongs to favourable prognostic risk group (MSKCC), he was treated with sunitinib. Skin rash, mucositis and hypertension were observed as side effects. A half year pause in therapy resulted in relapse during 2015. Sunitinib was reintroduced and remission was kept until 2018 when he had an epileptic episode caused by two brain metastases confirmed by brain MR. The lesions were treated with gamma knife (GK) and second line therapy - nivolumab was introduced. After 10 months nivolumab was stopped due to rash and extreme itching that was treated with prednisolone. A CT scan in 2020 showed a relapse in the mediastinal lymph nodes and stationary mass in pancreas. Nivolumab was reintroduced and continued until late 2021 when a new brain lesion was shown on MR and treated by GK.

CONCLUSION: Immunotherapy and gamma knife resulted in the benefit regarding the treatment of mccRCC. Eleven years since diagnosis and 4 years since brain metastases the patient is alive with ECOG 0.


CR54**Intraocular non-Hodgkin lymphoma mimicking uveitis**

Marija Vukojević^a, Ante Blažević^a, Mislav Blažević^a, Nenad Vukojević^{a,b}

^a School of Medicine, University of Zagreb

^b Department of Ophthalmology; University Hospital Centre Zagreb

DOI: <https://doi.org/10.26800/LV-144-supl2-CR54>


 Marija Vukojević 0000-0003-0355-8141, Ante Blažević 0000-0003-2128-5933, Mislav Blažević 0000-0002-0759-8688, Nenad Vukojević 0000-0001-7561-8858

Keywords: Immunomodulatory Therapy, Lymphoma, Uveitis

INTRODUCTION/OBJECTIVES: Uveitis is an intraocular inflammation that affects the middle eye layer and causes permanent structural damage and loss of visual function. It is most commonly caused by non-infectious factors, while infection occurs in 10-20% of uveitis cases. However, there is no actual intraocular inflammation in 3-5% of patients with clinical manifestations of uveitis. In these patients, some neoplastic and non-neoplastic processes may manifest as uveitis.

CASE PRESENTATION: A 51-year old male patient was diagnosed with bilateral panuveitis after experiencing pain and blurred vision. He was treated with systemic and local corticosteroids for a month, with no adequate response to medication. Several diagnostic tests were conducted, including infectious causes and vitreous body biopsy. All tests were negative, and vitreous body biopsy showed no tumor cell presence. However, during diagnostic and treatment, the patient developed neurological symptoms like confusion and could not concentrate. NMR of the brain was recorded, showing large mottled hyperintense lesions on both middle cerebellar peduncles in the caudal parts of the cerebellar hemispheres and multifocally in the subcortical and deep white matter. A stereotaxic brain biopsy was performed, and it showed infiltration constructed from clusters of large atypical centroblast-type lymphatic cells. Immunohistochemically, tumor cells corresponded to diffuse large-cell non-Hodgkin's lymphoma of the B-immunophenotype. The patient was later treated according to oncology protocol.

CONCLUSION: We should always consider the underlying neoplastic process in uveitis that doesn't respond to immunomodulatory therapy. On-time diagnosis and treatment could save not only visual function but also lives.


CR55**Case report: Invasive fungal rhinosinusitis in the immunocompetent host**Matilda Pudić^a, Katarina Đurić Vuković^b^a School of Medicine University of Zagreb^b University Hospital Centre ZagrebDOI: <https://doi.org/10.26800/LV-144-supl2-CR55> Matilda Pudić 0000-0003-1438-0457, Katarina Đurić Vuković 0000-0003-4763-6711

Keywords: Aspergillus, Immunology, Invasive fungal rhinosinusitis

INTRODUCTION/OBJECTIVES: Invasive fungal rhinosinusitis is a rare and, because of the possible CNS invasion, potentially life-threatening disease. It usually occurs in immunocompromised patients undergoing chemotherapy, transplantation, patients with hematologic malignancy, diabetes or AIDS. However, there have been noted few cases of invasion occurring in previously healthy individuals.

CASE PRESENTATION: A 46-year-old female, working as a chiropodist, with an insignificant medical history, initially presented with subacute frontoethmoidal sinusitis and was treated with several antibiotics and endoscopic sinus drainage. One month later, the patient developed severe headache, facial pressure, nasal congestion and purulent discharge. Fiberoptic nasendoscopy revealed grey/green deposits with hyphae in left maxillary sinus. While waiting for nasal swab and sinus aspiration finding, immunologic tests were performed, including serum protein electrophoresis, galactomannan and beta-D-glucan antigen test, fungus-specific IgE and HIV DUO testing. However, immunological findings excluded all causes of immunosuppression and allergic fungal sinusitis, as well. As microbial cultures revealed *Aspergillus niger*, systemic voriconazole was administered, and the patient was urgently referred for surgery. Endoscopic exploration showed bilateral sinus affection with bone erosions. Therefore, an extensive debridement was performed.

CONCLUSION: Invasive fungal rhinosinusitis occurring in immunocompetent patients emphasizes the need to identify other risk factors – anatomical, local or systemic, in order to speed up the diagnosis and avoid fatal outcome.


CR56**HACEK endocarditis complicated by pancreatitis after antibiotic therapy**Iva Bušić^a, Ivana Jurin^b^a School of Medicine, University of Zagreb, Croatia^b Department for Cardiovascular Diseases, University Hospital Dubrava, Zagreb, CroatiaDOI: <https://doi.org/10.26800/LV-144-supl2-CR56> Iva Bušić 0000-0002-5552-1984, Ivana Jurin 0000-0002-2637-9691

Keywords: acute pancreatitis, ceftriaxone, HACEK endocarditis


INTRODUCTION: HACEK (*Haemophilus* spp., *Aggregatibacter* spp., *Cardiobacterium hominis*, *Eikenella corrodens*, and *Kingella kingae*) endocarditis (HE) is a relatively rare disease with an excellent prognosis and simple management if the organism is properly identified. Administration of appropriate antimicrobial therapy in this case led to an excellent resolution of HE but also to a rare complication – acute pancreatitis.

CASE PRESENTATION: A 40-year-old male patient with a mechanical aortic valve was admitted to the cardiology department due to chills, tremors, fatigue, and mild fever. The patient denied catarrhal symptoms, angina, palpitations or crisis of consciousness. Echocardiogram showed a small vegetation on the mechanical valve, and *Haemophilus parainfluenzae* was found in blood cultures, which confirmed HACEK endocarditis. Ceftriaxone was introduced into therapy according to the antibiogram. In the following days, the patient's condition improved significantly and he was discharged. However, after discharging, the patient presented with abdominal pain and nausea, while laboratory findings showed elevated amylase and lipase levels, verifying acute pancreatitis. Until the condition improved, the patient was kept nihil per os and intravenous fluid was provided.

CONCLUSION: Although generally rare, cases of HACEK endocarditis are significantly more common in patients with pre-existing heart disease or prosthetic valves. Cholelithiasis is, admittedly, a known side effect of ceftriaxone, but globally, only few cases of ceftriaxone-associated pancreatitis have been reported. There is no specific test for establishing a diagnosis of drug-induced acute pancreatitis; instead, the diagnosis is often based on exclusion of all other common causes of acute pancreatitis.


CR57**Lymphocytic interstitial pneumonitis (LIP) as an extraglandular manifestation of primary Sjögren's syndrome: a case report**Nikolina Kuštra^a, Robert Ledenko^a, Ivan Padjen^b^a University of Zagreb, School of Medicine^b Division of Clinical Immunology and Rheumatology, Department of Internal Medicine, University Hospital Centre ZagrebDOI: <https://doi.org/10.26800/LV-144-supl2-CR57> Nikolina Kuštra 0000-0002-9131-224X, Robert Ledenko 0000-0002-5105-6202, Ivan Padjen 0000-0002-9249-9325

Keywords: glucocorticoids, rheumatoid factor, Sjögren's syndrome

INTRODUCTION/OBJECTIVES: Lymphocytic interstitial pneumonitis (LIP) is a disease of unknown etiology, which usually occurs after the age of 50, and is manifested by chronic cough and dyspnea. It is a rare but relatively specific feature of Sjögren's syndrome.**CASE PRESENTATION:** A 61-year-old male was hospitalized due to fever, cough and increased inflammatory markers. His chest X-ray and chest CT scan were consistent with interstitial lung disease. CT scan revealed bilateral basal cystic lesions (up to 3 cm in diameter) and thickening of the interlobular septa. Moreover, he complained of dry mouth. His sicca syndrome was confirmed by a low saliva flow rate as well as positive Schirmer test. Laboratory workup revealed an increased erythrocyte sedimentation rate (out of proportion to the C-reactive protein levels), as well as increased rheumatoid factor and positive antinuclear antibodies (double-stranded DNA, SS-A and SS-B). Bone marrow aspiration revealed no sign of hematological disease. Bronchoalveolar lavage cytology was consistent with LIP. The patient was diagnosed with LIP in the context of Sjögren's syndrome and was commenced on prednisone 30 mg with gradual dose tapering. He was also started on hydroxychloroquine and subsequently also on azathioprine as a steroid-sparing agent. The treatment led to normalization of inflammatory markers and improvement of symptoms. A follow-up chest CT scan revealed residual cysts in the lung parenchyma.**CONCLUSION:** We presented a patient with Sjögren's syndrome and LIP with a favorable clinical course. Glucocorticoids are the first line of treatment, however an additional immunosuppressive agent may be added to facilitate disease control and steroid tapering.**CR58****Manifestations of tuberculosis that we rarely think about**Maja Kopušar^a, Tin Karakaš^b, Lea Kalajžić^b, Sandra Knežević^a, Klara Poldan Skorup^c^a Faculty of Medicine, University of Rijeka, Croatia^b School of Medicine, University of Zagreb, Croatia^c Department of Emergency Medicine, Clinical Hospital Centre Rijeka, Rijeka, CroatiaDOI: <https://doi.org/10.26800/LV-144-supl2-CR58> Maša Kopušar 0000-0001-5910-9826, Tin Karakaš 0000-0001-6504-0669, Lea Kalajžić 0000-0002-4824-021X, Sandra Knežević 0000-0003-4863-1963, Klara Poldan Skorup 0000-0003-0063-7282

Keywords: Cerebrovascular insult, Pulmonary embolism, Tuberculosis

INTRODUCTION/OBJECTIVES: Tuberculosis is a multi-system infectious disease caused by Mycobacterium Tuberculosis. Tuberculosis mostly affects lungs but it can spread in the form of extrapulmonary tuberculosis. Around 4.3% of patients experience ischemic stroke and 1.5-3.4% of them experience pulmonary embolism.**CASE PRESENTATION:** A 41-year-old male patient, was admitted to the Emergency Department due to plegic left arm and depressed left corner of the lip. Vital signs were normal, besides low blood oxygen saturation (SpO₂). Blood pressure was 134/108 mmHg, heart rate 106 bpm, body temperature 36.8 °C, respiratory rate 22 per minute and SpO₂ was 77%. During the physical examination, the left arm was sinking into antigravitational position. Auscultatory, diffuse bilateral crepitations were present. No other abnormalities were noticed. Biochemistry tests showed signs of inflammation (CRP 106.9 mg/L), heart failure (NT pro-BNP: 11214 ng/L) and hypercoagulable state (D-dimer 25). Fresh ischemic lesion of the right frontoparietal lobe was noticed on the CT. Thoracic X-ray showed multiple bilateral spots and an inhomogeneous shaded lung parenchyma. Also, during the CT angiography, multiple emboli were noticed in segmental pulmonary arteries. PCR of the sputum was ordered and the patient tested positive for tuberculosis. The patient was treated with Rifampicin, Isoniazid and Pyrazinamide and two weeks later was discharged from hospital care. Pulmonary rehabilitation was recommended as a further course of treatment.**CONCLUSION:** Tuberculosis can affect almost any organ systems. If diagnosed and treated correctly, consequences can be minimized. Also, less common manifestations shouldn't be overlooked, because if neglected, the outcome might be fatal.

CR59**NOT EVERY RESPIRATORY FAILURE NOWDAYS IS COVID. POMPE DISEASE**Dina Gržan^a, Ivan Pećin^{a,b}, Vesna Galjuš^a^a School of Medicine University of Zagreb^b UHC Zagreb, Department of Internal medicine, Division of metabolic diseases, Referral centre for rare and metabolic diseases Ministry of health Republic of CroatiaDOI: <https://doi.org/10.26800/LV-144-supl2-CR59> Dina Gržan 0000-0002-3312-5569, Ivan Pećin 0000-0003-4425-6473, Vesna Galjuš 0000-0003-0509-1303

Keywords: enzyme replacement therapy, Pompe disease

INTRODUCTION/OBJECTIVES: Pompe disease, also known as glycogen storage disease type II, is an autosomal recessive disorder caused by deficiency of the lysosomal enzyme acid- α -glucosidase. It is a chronic and progressive disease characterized by storage of glycogen mostly in muscles. Late onset cases typically present with proximal muscle weakness and respiratory insufficiency or exertional dyspnea. Treatment is now available with intravenous infusion of recombinant acid α -glucosidase.

CASE PRESENTATION: We present a 45-year-old patient that was healthy up to 2017. when he started developing mild muscle weakness. He was not able to stand up from sitting position. At the beginning of 2020. his symptoms aggravated following a respiratory tract infection (SARS CoV-19 was suspected but test was negative). He developed severe respiratory failure and was treated in the ICU. Given the clinical presentation, late onset form of Pompe's disease was suspected. Diagnose was confirmed with low Alpha glucosidase enzyme concentration and muscle biopsy (glycogen deposits) and 32-13T>G- missense gene variation. At the time he was tracheostomized and dependent on home oxygen concentrator. Enzyme replacement therapy with Myozyme was introduced. After a year on Myozyme the patient is subjectively well and has been decannulated. His 6MWT is improving and he is starting to live a more active life.

CONCLUSION: Pompe disease is rare, and the awareness about it is low. Pompe disease should be always in differential diagnosis of patients presenting with muscle weakness and respiratory insufficiency lacking clear pulmonal pathology. Early diagnosis and treatment improves outcome and significantly improves the quality of patients' lives.


CR60**Pemetrexed treatment for adenocarcinoma of unknown primary origin with BAP-1 mutation – implementing NGS analysis into clinical practice**Andrea Racetin^a, Borislav Belev^b^a School of Medicine University of Zagreb^b University Hospital Centre ZagrebDOI: <https://doi.org/10.26800/LV-144-supl2-CR60> Andrea Racetin 0000-0002-2267-6592, Borislav Belev 0000-0002-1887-7324

Keywords: BAP-1 mutation, Next-generation sequencing (NGS), pemetrexed

INTRODUCTION/OBJECTIVES: Genome analysis like „Next-generation sequencing“ (NGS) has impacted research of complex diseases including cancer. NGS allowed a cost- and time-effective sequencing of tumor DNA, introducing us to a „genomic era“ of cancer research and treatment.

CASE PRESENTATION: The 65-year-old female patient with a history of arterial hypertension and hypothyroidism presented with palpable lesion and pain under her left rib cage. After comprehensive diagnostic evaluation, other lesions were found in the left lung hilum, pleura and XI left rib. The patient was operated and histopathological analysis showed adenocarcinoma possibly originating from pancreas, biliary tract or gallbladder. During the diagnostic procedure and operation, the primary origin was not found. Adjuvant therapy included cisplatin and gemcitabine but, because of disease progression, it was changed to docetaxel. Despite the systematic treatment, progression was noticed both intrathoracic and intra-abdominal. NGS analysis of tumor material revealed a BAP-1 (BRCA1- Associated Protein 1) mutation linked to several tumors including malignant mesothelioma. The treatment was continued with pemetrexed indicated for malignant mesothelioma and NSCLC (non-small cell lung cancer). Regression of metastatic lesions was achieved.

CONCLUSION: This case represents that finding the molecular background of cancer can lead us to more specific and effective treatment and better outcomes in the future.


CR61**Pituitary apoplexy in a patient with atrial fibrillation as a side effect of dabigatran treatment**Dora Cvrtila^a, Tina Dušek^b^a School of Medicine, University of Zagreb^b Department of Endocrinology, University Hospital Centre ZagrebDOI: <https://doi.org/10.26800/LV-144-supl2-CR61> Dora Cvrtila 0000-0001-7335-2267, Tina Dušek 0000-0002-1266-3501

Keywords: apoplexy, atrial fibrillation, dabigatran, NOACs

INTRODUCTION/OBJECTIVES: Atrial fibrillation (AF) is the most common heart rhythm abnormality usually present in elderly population significantly increasing the risk for thromboembolic incidents and therefore requiring the long-term treatment with anticoagulant agents. In the last decade, novel oral anticoagulant drugs or NOACs such as dabigatran, apixaban and rivaroxaban have taken over warfarin's role in patients with high risk of blood clotting. They are non-peptide, thrombin or coagulation factor Xa inhibitors, consequently patients do not need to control their INR.

CASE PRESENTATION: In this report we present a 74-year-old female patient who came to the Department of Endocrinology, KBC Zagreb, with hand tingling and progressive deterioration in vision acuity on her right eye. After a head CT, a nonfunctional pituitary macroadenoma and previously detected permanent atrial fibrillation were present. The patient suffered pituitary apoplexy with progression to subarachnoid space six weeks after the initiation of treatment with dabigatran. She was successfully treated conservatively with almost complete hemorrhage resorption 3 months after the cessation of anticoagulant treatment without additional surgical interventions.

CONCLUSION: Although NOACs are very effective in blood clot prevention, there seems to be a high risk of major gastrointestinal bleeding, solid tumor complications and other, yet not clearly defined consequences. Therefore, when treating a patient with atrial fibrillation who is at high risk of developing a thrombus, but also has predispositions for continuous active bleeding, anticoagulant therapy should be carefully weighted, and the patient should be frequently followed-up on. A conservative and supportive measures were decided to be the best approach in this case.

CR62**Pregnancy outcomes in women with Fontan circulation**Ozana Miličević^a, Vesna Elvedić Gašparović^b, Iva Barišić^a, Mia Alerić^a, Leo Matijašević^a^a School of Medicine University of Zagreb^b Department of Obstetrics and Gynecology, University Hospital Centre ZagrebDOI: <https://doi.org/10.26800/LV-144-supl2-CR62> Ozana Miličević 0000-0003-0289-3386, Vesna Elvedić Gašparović 0000-0002-0960-3989, Iva Barišić 0000 0003 2964 0901, Mia Alerić 0000-0002-8232-7191, Leo Matijašević 0000-0002-7010-9111

Keywords: cesarean section, Fontan circulation, pregnancy

INTRODUCTION/OBJECTIVES: The Fontan operation is a life-saving procedure performed on pediatric patients diagnosed with univentricular heart disease. The Fontan circulation is established by redirecting blood flow directly to the pulmonary circulation without passing through a ventricle. As more women with Fontan circulation reach adulthood and become pregnant, it is important to recognize obstetrical risks and provide optimal care for this rare condition.

CASE PRESENTATION: We present a 30-year-old primigravida at 36 weeks gestation who was referred to our hospital because monitoring of a high-risk pregnancy was needed. Her past medical history included tricuspid atresia and hypoplastic right ventricle treated by the Fontan procedure at the age of 4. Women with Fontan circulation are at a higher risk for miscarriage, preterm labor and intrauterine growth restriction. Therefore, team with an obstetrician, cardiologist and anesthesiologist was assembled. During the examination, regular fetal movements were observed, while fetal echocardiography excluded fetal abnormalities. Owing to the uncertainty of vaginal delivery in this case, at 37 weeks gestation a transverse cesarean section was performed in the presence of cardiologist under general anesthesia. A female neonate was successfully delivered and the mother was transported to the intensive care unit in hemodynamically stable state.

CONCLUSION: Systemic venous congestion and fixed cardiac output in Fontan patients is further exacerbated by an increase in oxygen demand during pregnancy. This case illustrates the importance of collaboration between specialists, since a favorable fetomaternal outcome is achievable if it is managed in a specialized center with multidisciplinary approach.

CROSS


CR63 RECOGNIZING SPONDYLOARTHRITIS IN PRIMARY CARE

Marin Boban^a, Dragan Soldo^b

^a University of Zagreb, School of Medicine

^b Community health center Zagreb - Centre

DOI: <https://doi.org/10.26800/LV-144-supl2-CR63>

 Marin Boban 0000-0002-5552-0295, Dragan Soldo 0000-0003-2186-3107

Keywords: Arthritis, Rheumatology, Spondylarthritis

INTRODUCTION/OBJECTIVES: The present study surveys the problems of diagnostics of early ankylosing spondylitis (AS) and axial spondylarthritis (SpA). Spondylarthritis represents approximately 5% of the total number of chronic low back pain (CLBP) cases and poses a differential diagnostics challenge for Physicians. Regarding most SpA are chronic and can cause severe incapability, early diagnosis is of great significance.

CASE PRESENTATION: A 32-year-old female patient comes to the general practitioners' office because of chronic lower back pain (CLBP) affecting the lumbal area of the spine. Since the CLBP persisted after weeks of analgetic administration, the patient was instructed to do a Magnetic Resonance (MR) of the affected part of the back. MR showed Disk protrusion, area L3-L4, and compression of dural sack, area L4- L5, with signs of the degenerative process in spinal joints. Afterward, the patient was instructed to do a neurology check-up to diagnose possible radiculopathy since she reported experiencing a sensation of itching and burning throughout the right leg and weakness in both fists. Also, the patient was instructed to start physical therapy. After a neurology check-up came up clean and there was no improvement regarding physical therapy, the patient was instructed to see rheumatologist because of the morning stiffness and night pain in the joints. At the rheumatology department, diagnosis of Spondyloarthritis was confirmed.

CONCLUSION: Because of the non-specific early symptoms such as CLBP, early-stage diagnosis of Spondyloarthritis presents a problem for physicians. It's important to look for specific signs of Spondyloarthritis so diagnosis could be made as early as possible.


CR64 Formation of pseudoaneurysm and arteriovenous fistula following percutaneous left atrial appendage occluder implantation

Jakov Emanuel Bogdanić^a, Jurica Putrić Posavec^a, Vedran Velagić^{a,b}, Ivan Prepolec^{a,b}

^a School of Medicine University of Zagreb

^b Department of Cardiology; University Hospital Centre Zagreb

DOI: <https://doi.org/10.26800/LV-144-supl2-CR64>

 Jakov Emanuel Bogdanić 0000-0001-6656-8289, Jurica Putrić Posavec 0000-0003-1667-802X, Vedran Velagić 0000-0001-5425-5840, Ivan Prepolec 0000-0001-5870-202X

Keywords: arteriovenous fistula, atrial fibrillation, gastrointestinal bleeding, left atrial appendage occluder, pseudoaneurysm

INTRODUCTION/OBJECTIVES: Left atrial appendage harbours most of the blood clots responsible for cardioembolic events in patients with atrial fibrillation. In patients with adverse reactions to blood clotting medication, such as gastrointestinal bleeding, percutaneous occlusion of the appendage with a device is a minimally invasive procedure with results comparable to warfarin. A possible complication of percutaneous intervention is the formation of pseudoaneurysms and arteriovenous fistulae.

CASE PRESENTATION: A 75-year-old female patient on oral anticoagulation and antiaggregation therapy suffering from paroxysmal atrial fibrillation, ischaemic heart disease, arterial hypertension, diabetes, peripheral artery disease, and iron deficiency anaemia reports melena on oral anticoagulants. Investigation finds no source of the -GI bleeding, indicating blood clotting medication as the main cause. A percutaneous implantation of an Amplatzer Amulet device is performed followed by bleeding from the right groin which is stopped upon pressure and protamine administration. The next day a colour Doppler ultrasound reveals a small tract with detection of flow, with no signs of pseudoaneurysm or arteriovenous fistula. However, a month later an MSCT scan reveals a small pseudoaneurysm at the origin of the superficial femoral artery and an arteriovenous fistula communicating with the common femoral vein. Occlusion of the fistula and resection of the pseudoaneurysm are performed without complications, and the patient is transferred to intensive care for observation.

CONCLUSION: Left atrial appendage occluders are a suitable treatment for atrial fibrillation patients who can't take oral anticoagulants. Pseudoaneurysms and arteriovenous fistulae are possible complications of percutaneous procedures and can be successfully resolved surgically.

CR65**Recurrent retroperitoneal dedifferentiated liposarcoma**Ines Trkulja^a, Lucija Brkić^{a,b}, Klara Kuzman^{a,b}, Emil Kinda^{a,b}, Petar Matošević^{a,b}^a School of Medicine University of Zagreb^b Department of Surgery; University Hospital Centre ZagrebDOI: <https://doi.org/10.26800/LV-144-supl2-CR65> Ines Trkulja 0000-0002-3482-8733, Lucija Brkić 0000-0003-0692-483X, Klara Kuzman, Emil Kinda, Petar Matošević 0000-0001-6295-6161

Keywords: Anthracyclines, Docetaxel, Gemcitabine, Liposarcoma, Radiation Tolerance

INTRODUCTION/OBJECTIVES: Liposarcomas (LPS) are malignant tumors deriving from the adipocytic differentiation process. They are divided into four subtypes of LPS – well-differentiated (WDLPS), dedifferentiated (DDLPS), myxoid (MLPS), and pleomorphic (PLPS). Regarding histological subtype and molecular pathology, tumors have different recurrence rates, radiosensitivity, and chemosensitivity, representing a challenge to every physician involved in their treatment decision. DDLPS commonly appears as a focal outgrowth of a WDLPS lesion.

CASE PRESENTATION: An 82-year-old male was readmitted to our facility after the positron emission tomography-computed tomography (PET-CT) showed a 7x4,5 cm anteriorly positioned recurrent abdominal mass. He had three prior surgeries - two in Greece in 2020 and one in our facility in 2021 and was oncologically monitored afterward. The patient has previously received 16 cycles of anthracycline chemotherapy (docetaxel/gemcitabine) followed by tumor extirpation in 2020. The pathohistology of a 12,5x12x6,2 cm nodular tumorous mass in 2021 showed atypical mesenchymal cells with a hyperchromatic nuclei corresponding to a DDLPS. In addition, pleomorphic adipocytes with the individual hyperchromatic nuclei were found on the edges, corresponding to a WDLPS. Molecular pathology showed amplification of the MDM2 gene – one of the cancer-related genes. A tumorous mass in the upper hemiabdomen and diffusely located nodules were removed during the most recent surgery in 2022.

CONCLUSION: When treating retroperitoneal LPS, peri- and postoperative management, as well as surgical procedures, should be decided on a case-by-case basis. A multidisciplinary team consisting of specialists is crucial for better patient outcomes and life quality.

CR66**Renal denervation as a therapeutic modality in a patient with resistant hypertension**Tin Rosan^a, Nikolina Novak^a, Ingrid Prkačin^b^a School of Medicine, University of Zagreb, Zagreb, Croatia^b Department of Internal Medicine, Clinical Hospital Merkur, Zagreb, CroatiaDOI: <https://doi.org/10.26800/LV-144-supl2-CR66> Tin Rosan 0000-0002-7585-5770, Nikolina Novak 0000-0001-7416-7805, Ingrid Prkačin 0000-0002-5830-7131

Keywords: renal denervation, resistant hypertension, type 2 diabetes

INTRODUCTION/OBJECTIVES: Resistant hypertension (HTN) is defined as blood pressure (BP) that remains above 140/90 mmHg despite the administration of three antihypertensive medications, including a diuretic. The sympathetic nervous system (SANS) overactivity has been proven to contribute to the development and maintenance of resistant hypertension. Renal denervation (RDN) produces inhibition of the SANS by ablating nerves distributed in the intima of renal arteries and could be a therapeutic option for resistant HTN.

CASE PRESENTATION: We present a 54-year-old woman with type 2 diabetes (T2D) and resistant HTN lasting for more than 30 years. She was first admitted to the emergency department in July 2013 due to the hypertensive urgency. At that point she was taking six antihypertensive drugs: urapidil, lercanidipine, valsartan, hydrochlorothiazide, nebivolol and torasemide. Despite the medications, her average BP on examination was 178/101 mmHg (the maximum BP recorded was 240/140 mmHg). RDN was indicated and performed in January 2017. After few months, the beneficial effect of RDN on BP was shown with average values 141/91 mmHg. During the follow-ups over last 4 years, HTN is being monitored and well controlled at values 137/77 mmHg with continued antihypertensive therapy. The patient also regularly treats other comorbidities like T2D, chronic kidney disease (CKD), obesity and hyperlipidaemia.

CONCLUSION: RDN is an effective and safe procedure for resistant hypertension. The goal is not a complete withdrawal of antihypertensive medications, but it helps with lowering the cardiovascular morbidity and mortality. Patients with type 2 diabetes and CKD may be the target population that would benefit from RDN.


CR67**Somatic cough syndrome in a 13-year-old girl: a case report**

Jelena Bošnjak^a, Ana Đanić Hadžibegović^b, Martina Fojtik Budanko^b

^a School of Medicine University of Zagreb

^b University Hospital Centre Zagreb, Department of Otorhinolaryngology

DOI: <https://doi.org/10.26800/LV-144-supl2-CR67>

 Jelena Bošnjak 0000-0002-9598-8642, Ana Đanić Hadžibegović 0000-0001-8513-5032, Martina Fojtik Budanko 0000-0002-1532-4038

Keywords: behavioral therapy, persistent cough, somatic cough syndrome, videolaryngoscopy

INTRODUCTION/OBJECTIVES: Somatic cough syndrome is a disorder with complex and not fully known etiology. It usually presents in children. Because of diverse clinical presentation, diagnosis is often made after an extensive search for organic cause.

CASE PRESENTATION: A 13-year-old girl presented to the ENT clinic with a 5-week history of continuous coughing that affected her everyday social activities. The patient coughed every ten seconds during awake state and the cough stopped during sleep. It started after worsening of *H. pylori*-negative gastritis and GERD, and did not get better during proton pump inhibitor therapy. Videolaryngoscopy showed signs of LPR, normal vocal folds movement, and during cough only the retraction of the membranous part of trachea was observed. The patient was a great student, growing up in normal functioning family. She was highly motivated for success in all fields, prone to perfectionism, with high sensitivity to criticism. Combination of behavioral and supportive therapy was recommended. After a week of breathing exercises with speech and language pathologist a significant improvement occurred, and the cough completely resolved after 2 months. She was able to go back to her normal everyday activities.

CONCLUSION: Somatic cough syndrome has a severe impact on life quality of both patient and parents. It should always be differential diagnosis, especially if organic cause of cough cannot be found. The role of non-pharmacological therapy in treatment is crucial.


CR68**Temporal bone meningocele presenting as a secretory otitis media**

Gabrijela Buljan^a, Jelena Bošnjak^a, Antonia Bukovac^a, Anton Malbašić^a, Jakov Ajduk^{a,b}

^a School of Medicine University of Zagreb

^b Department of Otorhinolaryngology, University Hospital Centre "Sestre Milosrdnice"

DOI: <https://doi.org/10.26800/LV-144-supl2-CR68>

 Gabrijela Buljan 0000-0003-4060-9497, Jelena Bošnjak 0000-0002-9598-8642, Antonia Bukovac 0000-0002-0412-433X, Anton Malbašić 0000-0002-8699-8662, Jakov Ajduk 0000-0003-3648-0280

Keywords: meningocele, otitis media, otorrhea


INTRODUCTION/OBJECTIVES: Temporal bone meningocele is an uncommon condition in which middle fossa meninges prolapse into the middle ear through a tegmen defect. These bone defects may be spontaneous or acquired, resulting from head trauma or ear surgery. Some of the most common symptoms include conductive hearing loss, headache, otorrhea and recurrent acute otitis media. Rare but more severe complications may be otogenic meningitis or cerebral abscess.

CASE PRESENTATION: The patient is a 69-year-old female who presented with a history of recurrent right-sided otitis media over the last 5 years. Tone audiogram suggested a mild conductive hearing loss on the right ear where type B tympanogram was also found. Myringotomy with ventilation tube insertion was performed. Purulent content was found in the middle ear, *Klebsiella pneumoniae* was isolated. After the antibiotic therapy a clear secretion continued for three weeks. The finding of beta-2 transferrin in the fluid from the external ear canal confirmed the cerebrospinal fluid. CT and MRI showed a meningocele prolapsing through a right-sided mastoid and tympanic tegmen defect. The patient underwent surgical repair of meningocele via mastoidectomy with autologous temporalis muscle fascia and fibrin glue. The postoperative course was uneventful and the patient remains asymptomatic.

CONCLUSION: Temporal bone meningocele is a potentially life-threatening condition as it puts the patients at risk of otogenic infection spread and for developing meningitis. The malformation is an indication for surgery in order to prevent these complications. For this reason it must be considered as a differential diagnosis of secretory otitis media in adult population.



CROSS


CR69**Testicular cancer masquerading as an incarcerated inguinal hernia – A case report**Karla Lužaić^a, Lucija Brkić^b, Tomislav Bruketa^b^a *School of Medicine, University of Zagreb, Zagreb, Croatia*^b *Department of Surgery, University Hospital Centre Zagreb, Zagreb, Croatia*DOI: <https://doi.org/10.26800/LV-144-supl2-CR69> Karla Lužaić 0000-0002-3132-8944, Lucija Brkić 0000-0003-0692-483X, Tomislav Bruketa 0000-0001-5892-2444

Keywords: abdominal pain, general surgery, inguinal hernia, testicular neoplasms

INTRODUCTION/OBJECTIVES: An incarcerated inguinal hernia is a surgical emergency. Testicular tumors can present with scrotal swelling, hence they could easily be mistaken for a hernia. Both conditions, if left untreated, are life-threatening and lead to severe complications.

CASE PRESENTATION: A 79-year-old male patient was admitted to the emergency department (R) for pain and swelling in the right lower hemiabdomen. Previous medical history noted benign prostatic hyperplasia and an inguinal hernia. The pain appeared yesterday afternoon. The patient had no nausea, vomiting, or diarrhea. Physical examination revealed a soft abdomen without tenderness to palpation or focal rigidity accompanied by pain and a palpable mass in the right lower hemiabdomen. Blood tests were in the reference range, excepting moderately increased neutrophils and monocytes. Inflammatory marker, C-reactive protein (CRP), was not increased. Imaging showed bowel meteorism with no signs of mechanical obstruction or pneumoperitoneum. The patient underwent emergency hernia repair surgery. However, macroscopically altered testicular tissue with an enlarged spermatic cord was found intraoperatively. Hence, right orchidectomy and resection of the spermatic cord with no complications were performed. The patient of good general condition and symptoms relief was discharged to home care.

CONCLUSION: A testicular tumor can present as an incarcerated inguinal hernia. Since incarcerated inguinal hernia is a cause life-threatening condition, emergency hernia repair surgery is indicated. In this case, a testicular tumor was found intraoperatively, consequently, instead of hernioplasty, orchidectomy was recommended.


CR70**The role of fortified eyedrop antibiotic therapy in Pseudomonas aeruginosa corneal infection – a case report**Mia Edl^a, Suzana Matić^{a,b,c}, Tomas Edl^b, Lucija Čolaković^c^a *Faculty of Medicine, Josip Juraj Strossmayer University of Osijek, Croatia*^b *Faculty of Dental Medicine And Health, Josip Juraj Strossmayer University of Osijek, Croatia*^c *Department of Ophthalmology, Osijek University Hospital Centre, Osijek, Croatia*DOI: <https://doi.org/10.26800/LV-144-supl2-CR70> Mia Edl 0000-0002-7818-5741, Suzana Matić Tomas Edl, Lucija Čolaković

Keywords: amniotic membrane transplantation, corneal ulcer, fortified medication, topical therapy

INTRODUCTION: Pseudomonas aeruginosa is a gram-negative bacterium and a leading cause of corneal ulcers. In the eye, extracellular enzymes may lead to keratitis, ulcer, endophthalmitis, rapid corneal destruction, and perforation leading to a quick loss of vision and necessity for urgent vitrectomy, amniotic membrane transplantation, or eye evisceration if no other therapy showed to be useful.

CASE PRESENTATION: A case report of P.aeruginosa corneal ulcer in a 70-year-old woman, who was admitted to the Department of Ophthalmology Osijek in December 2021. Visual acuity was light perception, slit lamp examination revealed conjunctival suppurative secretion, 3 mm central corneal ulcer, and 2 mm level of hypopyon in the anterior chamber. Empirical ciprofloxacin eyedrop therapy ulcer scheme was introduced and culture results confirmed P.aeruginosa infection highly sensitive to ceftazidime, ciprofloxacin, and amikacin. Intravenous ceftazidime was also introduced for 10 days. As the eye was full of suppuration after 72 hours and the central corneal zone was the same size and thinner, fortified amikacin eyedrop (40 mg/mL) every 2 hours was instilled resulting in loss of suppuration after 2 weeks but with corneal perforation that was successfully surgically resolved with amniotic membrane transplant. Before the surgery, the corneal swab was sterile, amikacin eyedrops were continued until a total period of 1 month and the cornea healed with a small stromal corneal scar.


CONCLUSION: This case report implicates the importance of prompt introduction of fortified antibiotic therapy in cases of P.aeruginosa with an aim at preventing irreversible loss of vision, endophthalmitis, and loss of eye structure due to perforation.

CR71**Therapeutic penetrating keratoplasty in a patient with acute perforated corneal ulcer caused by *Pseudomonas aeruginosa* keratitis**Božana Mrvelj^a, Tomislav Kuzman^{a,b}^a *University of Zagreb, School of Medicine, Zagreb, Croatia*^b *Department of Ophthalmology, Zagreb University Hospital Centre*DOI: <https://doi.org/10.26800/LV-144-supl2-CR71> Božana Mrvelj 0000-0001-9586-6090, Tomislav KuzmanKeywords: corneal ulcer, keratitis, keratoplasty, *Pseudomonas aeruginosa*

INTRODUCTION/OBJECTIVES: Penetrating keratoplasty is a surgical procedure where a damaged section of the cornea is surgically removed and replaced with a healthy donor tissue. Therapeutic keratoplasty performed in case of active inflammation is called 'à chaud' (french – hot). Here we present a case of keratoplasty à chaud in a patient with a perforated corneal ulcer caused by *Pseudomonas aeruginosa* infection.

CASE PRESENTATION: A 25-year-old male presented to an emergency ophthalmological department with redness, pain, and vision loss in his left eye. The patient reported wearing soft contact lenses prior to this incident. The ophthalmic examination revealed corneal edema, central corneal ulcer with descemetocele, corneal melting and a threat of total perforation. From the appearance of first symptoms to potential blindness, passed hardly 24 hours. A conjunctival swab was obtained and, subsequently, the patient was hospitalized and treated with empirical antibiotic and antimycotic therapy for keratitis. Meanwhile, *Pseudomonas aeruginosa* was isolated from the culture. Corneal infection caused by *P.aeruginosa* has significantly worse outcome than infection with other bacterial pathogens, causing rapid corneal melting, as it is extremely aggressive. Therapeutic penetrating keratoplasty à chaud was urgently performed. In this case, keratoplasty along with elimination of the affected tissue, restores the integrity of the cornea and saves visual function. During the following days, clinical features improved, and the patient recovered with great anatomic and functional outcome.

CONCLUSION: Therapeutic penetrating keratoplasty à chaud is a crucial procedure for restoring the patient's vision and preventing corneal blindness that developed in a case of perforated corneal ulceration.


CR72**Case report: Transcervical approach for removal of the tumor of the primary parapharyngeal space (PPS)**Dora Rebek Divković^a, Ana Kvolik^b^a *School of Dental medicine University of Zagreb*^b *Department of maxillofacial surgery, University Hospital Center Osijek*DOI: <https://doi.org/10.26800/LV-144-supl2-CR72> Dora Rebeka Divković 0000-0001-7587-7286, Ana Kvolik 0000-0002-3991-6433

Keywords: branchial cyst, PPS tumor, surgery, transcervical approach

INTRODUCTION/OBJECTIVES: Tumors of the primary parapharyngeal space (PPS) account for less than 1% of all head and neck tumors. Because of the asymptomatic aspect of the disease, PPS tumors are usually detected in the advanced stage. In this case report, we present rare a PPS tumor and its treatment.

CASE PRESENTATION: A 41-year-old male patient was admitted to the Osijek University Hospital in November 2021. The patient complained of pain in the neck, ear and, odynophagia. CT showed a well-demarcated cystic mass on the right side of the parapharynx. Due to suspicion of the tumor of the primary parapharyngeal space, an MRI was performed. Pre-operative MRI in the axial section showed a 45x31x52 mm (APxLLxCC) mass extending from the base of the skull to the submandibular region, leaning against the medial pterygoid muscle and the paravertebral muscle. The patient was treated with surgical resection via a transcervical approach. Pathohistological findings show cyst walls built of collagenous connective tissue with moderate inflammatory infiltrates of lymphocytes and plasma cells, lined with multicellular squamous epithelium. The described histological picture corresponds to a branchial cyst. The patient's recovery was uneventful and he had no complaints on 2 months follow-up.

CONCLUSION: In summary, the efficiency of PPS surgery is contingent on two factors: the accurate identification of the lesion, and the appropriate surgical approach.


CR73**Where did the lungs go? Vanishing Lung Syndrome in an HIV positive patient**Hana Škornjak^a, Đivo Ljubičić^b^a School of Medicine University of Zagreb^b Department of Pulmonology, Clinical Hospital DubravaDOI: <https://doi.org/10.26800/LV-144-supl2-CR73> Hana Škornjak 0000-0003-2376-6634, Đivo Ljubičić 0000-0001-7071-9078

Keywords: antiretroviral therapy, emphysema, HIV, smoking

INTRODUCTION/OBJECTIVES: Vanishing-lung syndrome is a rare condition characterized by lung emphysema with giant bullae. Giant bullae occupy more than 30% of hemithorax and are often misdiagnosed as pneumothorax. We present the case of a 34-year-old HIV positive man, who had worsening respiratory symptoms for six months before seeking clinical care.

CASE PRESENTATION: In June 2019 the patient presented at the GP clinic due to progressive piercing chestpain and shortness of breath. In patient's history there was a record of treatment with azithromycin for pneumonia (January 2019). He was diagnosed with HIV in 2012 and started taking regular antiretroviral therapy in 2015. With treatment (altegravir, tenofovir/emtricitabine) he achieved undetectable HIV-viremia and was immunocompetent (CD4-lymphocytes 826 st/ μ L, June 2019). Since 2012 he smoked up to 40 cigarettes/day due to anxiety and depression. Clinical examination performed in June 2019 found right-sided hyperresonant sound on percussion and diffusely decreased sounds on auscultation. Spirometry indicated severe obstruction of the small airways. Results of a 6-minute-walk-test was below the reference range (280m, SaO₂ 95-87%), with severe dyspnea. CT-scan showed bilateral emphysema in the upper thorax, with two large bullae completely compressing the lung on the right. After the bullectomy, the lung function improved and the patient had no symptoms.

CONCLUSION: It is important to increase awareness of the risk of COPD in HIV patients, particularly those who smoke and advise them about importance of smoking cessation. Young smokers with emphysema should be offered an HIV-test. HIV is a chronic disease and if well treated, patients do not have reduced life expectancy.

CR74**Hepatitis E virus infection after kidney transplantation**Adrijan Tiku^a, Petra Terzić^a, Karlo Tkalec^a, Željka Jureković^b, Anna Mrzljak^{a,c}^a School of Medicine University of Zagreb, Zagreb, Croatia^b Department of Nephrology, University Hospital Merkur^c Department of Gastroenterology, University Hospital Centre ZagrebDOI: <https://doi.org/10.26800/LV-144-supl2-CR74> Adrijan Tiku 0000-0001-5564-467X, Petra Terzić 0000-0002-7687-1430, Karlo Tkalec 0000-0003-2811-8716, Željka Jureković 0000-0003-0690-2577, Anna Mrzljak 0000-0001-6270-2305

Keywords: hepatitis E virus, immunodeficiency, kidney transplantation

INTRODUCTION/OBJECTIVES: HEV usually presents as acute self-limiting hepatitis. However, in immunocompromised populations it may lead to chronic hepatitis and liver cirrhosis. We present a case of an HEV infection in a kidney transplant recipient.

CASE PRESENTATION: A 23-year-old male kidney recipient presented in August 2020 with elevated liver parameters (AST 36 U/L, ALT 80 U/L, GGT 72 U/L, ALP 98 U/L, bilirubin 10 μ mol/L). His past medical history includes two kidney transplants (2003, 2019). His maintenance immunosuppression consisted of tacrolimus, mycophenolate-mofetil, and steroids. His serology for EBV, CMV, HAV, HBV, HCV was negative, while HEV-IgG, IgM and HEV-RNA tested positive. The patient was treated with ribavirin for 8 weeks with dose reduction due to the development of anaemia. At the end of treatment HEV RNA tested negative, and his liver tests returned to normal (AST 24 U/L, ALT 26 U/L, GGT 26, U/L ALP 79 U/L, bilirubin 8 μ mol/L) and remained unremarkable until November 2021, when peaked at AST 69 U/L, ALT 170 U/L, GGT 137 U/L, ALP 133 U/L, bilirubin 8 μ mol/L. He was re-tested for HEV, and HEV-RNA was 6.43E+5 IU/mL. The patient re-started a second course of ribavirin scheduled for 12 weeks.

CONCLUSION: In immunocompromised individuals the management of HEV infection may be challenging. The reduction of IS, which may not always be feasible, is the first step, and the addition of ribavirin helps to achieve sustained virological response (SVR). However, patients who do not achieve SVR are at risk of developing advanced liver disease and should be retreated and carefully followed.


CR75**External and a four-act internal pelvic fixation in a patient with polytrauma**

Leo Matijašević^a, Ozana Miličević^a, Lucija Brkić^{a,b}, Tin Ehrenfreund^b

^a School of Medicine University of Zagreb, Zagreb, Republic of Croatia

^b Department of Surgery, University Hospital Centre Zagreb, Zagreb, Croatia

DOI: <https://doi.org/10.26800/LV-144-supl2-CR75>

 Leo Matijašević 0000-0002-7010-9111, Ozana Miličević 0000-0003-0289-3386, Lucija Brkić 0000-0003-0692-483X, Tin Ehrenfreund

Keywords: External Fixators, Femur Head, Fracture Fixation, Pubic Symphysis, Sacroiliac Joint

INTRODUCTION: Fractures of the pelvic ring carry a high mortality and morbidity rate due to possibly great blood loss and abdominal organ trauma. However, external pelvic fixation can stabilize the patient enough to undergo emergency surgeries when treating a patient with multiple life-threatening injuries.

CASE PRESENTATION: A 35-year-old male sustained multiple pelvic fractures, abdominal and aortic injuries after a traffic accident. The patient was admitted to our facility's ER conscious and maintained verbal contact but under the influence of alcohol. His GCS was 13, he was respiratory sufficient and hemodynamically stable. He was diagnosed with a left pneumothorax, a descendent aortic rupture, spleen rupture, renal contusion, and B1 type pelvic fracture—rupture of the pelvic symphysis, fracture of the left acetabulum and fracture of the left ilium and fracture of transverse process of L5 vertebra. After the left hemithorax was drained, a supra-acetabular pelvic external fixator and a right tibial skeletal traction according to Brown were installed. Five days later, the patient underwent a four-act internal pelvic fixation. Firstly, through the modified Stoppa approach the transverse fracture of iliac bone was reduced and fixed with two screws. Then, the left sacroiliac joint was reduced and fixated with two plates and six screws. Thirdly, the symphysis was finally fixated with a plate and four screws. Lastly, through Kocher-Langenbeck approach large fragment of posterior acetabular wall was reduced and fixed with plate and four screws. The patient is recovering.

CONCLUSION: External fixation brings an excellent opportunity to carry out emergency procedures when treating a polytraumatic patient with multiple pelvic injuries. It is crucial to stabilize the patient and prevent future pelvic hemorrhage.


CR76**Overlap Syndrome at Rheumatology Department – Case Report**

Mia Šelović^a, Marija Bakula^{a,b}

^a School of Medicine University of Zagreb

^b Division of Clinical Immunology and Rheumatology, Department of Internal Medicine, University Hospital Center Zagreb

DOI: <https://doi.org/10.26800/LV-144-supl2-CR76>

 Mia Šelović 0000-0002-1393-7826, Marija Bakula 0000-0002-0176-362X


Keywords: dermatomyositis, overlap syndrome, systemic lupus erythematosus

INTRODUCTION/OBJECTIVES: Systemic lupus erythematosus (SLE) is an autoimmune connective tissue disease, affecting mostly women of childbearing age. Dermatomyositis (DM) is a rare autoimmune inflammatory myopathy affecting both skin and muscles. Overlap syndrome is an autoimmune disease which shares features of at least two recognised connective tissue diseases. We present a case of an overlap syndrome refractory to treatment.

CASE PRESENTATION: A female patient was diagnosed with SLE in 1992. at the age of 20, with initial affection of central nervous system. She was treated for neurolyupus since 1997. with cyclophosphamide and hydroxychloroquine. Kidney biopsy in 2004. proved membranous glomerulonephritis with proteinuria of 2g/24h. During the next 10 years the patient was stable with serologically active disease and developed Raynaud's syndrome. In the summer of 2018. she developed progressive muscle weakness of shoulder and hip girdle with characteristic skin features. Muscle enzymes were highly elevated, along with positive PM- Scl antibodies, myositis specific Ro-52 antibodies, rise in complement consumption and myoglobinuria. Higher levels of glucocorticoids and methotrexate were introduced. Due to overcoming muscle weakness, puffy fingers, digital ulcers, generalized dermatomyositis with calcinosis and serological activity in 2020, she was started on rituximab and intravenous immunoglobulins which induced partial remission.

CONCLUSION: Connective tissue diseases are often hard to diagnose, with symptoms slowly accumulating over years. This patient has a rare overlap syndrome. She first developed SLE and dermatomyositis presented 16 years after. Despite SLE being in remission, DM was induced by exposure to UV radiation, which caused treatment-refractory disease.

CR77**Juvenile dermatomyositis with vasculopathy**Mia Kovačević^a, Magdalena Kujundžić^a, Marijana Frković^b^a School of Medicine University of Zagreb^b Division for Pediatric Rheumatology, Department of Pediatrics; University Hospital Centre ZagrebDOI: <https://doi.org/10.26800/LV-144-supl2-CR77>

 Mia Kovačević 0000-0002-8156-4777, Magdalena Kujundžić 0000-0001-6359-2654, Marijan Frković 0000-0002-1520-3375

Keywords: Infliximab, juvenile dermatomyositis, vasculopathy

INTRODUCTION/OBJECTIVES: Juvenile dermatomyositis (JDM) is rare, but serious disease with many possible complications. Hallmarks of this disease are heliotrope erythema, periorbital edema and Gottrone papules combined with symmetric proximal muscle weakness that usually slowly progresses over period of weeks and months. In most cases the age of onset is between 4 and 10 years. There are four subtypes of the disease with variable course, organ involvement and long-term clinical outcome.

CASE PRESENTATION: We present a case of a 7-year-old girl with characteristic skin changes and signs of proximal muscle weakness. Her disease started six months prior to hospitalization with subtle changes in her normal everyday activity and periorbital erythema. One month prior to hospitalization she had difficulty with walking up the stairs combined with progressive overall fatigue. After full laboratory and imaging work-up were done, the diagnosis of the most severe type of JDM with vasculopathy was confirmed. Initial therapy, that consisted of glucocorticoids, methotrexate, intravenous immunoglobulins, cyclophosphamide and plasmapheresis, was not sufficient and progressive deterioration of symptoms and laboratory findings were observed. Finally, the administration of infliximab (anti-TNF α) stopped the progression of the disease and led to slow regression of symptoms in period of several weeks.

CONCLUSION: It is well-known that course of the JDM depends on clinically defined subgroups, early diagnosis, and aggressive initial therapy. Besides, there are increasing number of new discoveries about immunologic and genetic aspects of the disease. Combination of well-known and newly discovered aspects of the disease open up new opportunities for taking care advancement of JDM patients.

CR78**Diabetic ketoacidosis and electrolyte disorders in patient with short bowel syndrome following acute mesenteric ischemia**Martina Pastorčić^a, Daniela Bandić Pavlović^{a,b}^a School of Medicine, University of Zagreb^b Department of anesthesiology, reanimatology and intensive care and pain management, University Hospital Centre ZagrebDOI: <https://doi.org/10.26800/LV-144-supl2-CR78>

 Martina Pastorčić 0000-0001-9215-9200, Daniela Bandić Pavlović 0000-0002-0529-8657

Keywords: acute mesenteric ischemia, diabetic ketoacidosis, short bowel syndrome

INTRODUCTION/OBJECTIVES: Acute mesenteric ischemia (AMI) is defined as a sudden occurrence of insufficient blood supply to the intestine that can lead to necrosis (gangrene) of the intestine wall or its ischemia alone. It is therefore a life-threatening condition that requires rapid diagnosis and proper treatment. In presence of irreversible ischemic lesions the only treatment option is surgery. Short bowel syndrome commonly develops as a result of such treatment and can be a precipitating factor for the emergence of acid-base and electrolyte disorders.

CASE PRESENTATION: A 62-year-old male with a history of type 2 diabetes presented to the Karlovac General Hospital Emergency department with diffuse abdominal pain and diarrhea. Following diagnostic verification of upper mesenteric artery and coeliac truncus thrombosis and rapid exacerbation of patient's condition, explorative laparotomy, resection of the gangrenous part of the small intestine and enterostomy were performed. The postoperative course was complicated by the first diabetic ketoacidosis event. The patient was then transferred to the University Hospital Center Zagreb in order to perform end-loop resection and jejunioileal anastomosis. Shortly, another explorative laparotomy was urgently needed and previously mentioned procedures were repeated. Afterwards, the patient was placed in an intensive care unit with laboratory findings indicating a second diabetic ketoacidosis event (pH=7.05) and electrolyte disorders. In the following days, the patient was contactable and had regulated glycemia due to continuous insulin therapy, but febrile and with persistent electrolyte imbalance. He is still in life-threatening condition and is undergoing treatment.

CONCLUSION: The complexity of AMI treatment is shown in its equally complex complications.

CR79**LAPAROSCOPIC TREATMENT OF POST-TRAUMATIC SPLENIC CYST**

Nora Rako^a, Tea Cindrić^b, Hanna Pašić^c, Jasenka Kraljević^d


^a *Emergency Department, Internal Medicine Department, University Hospital and School of Medicine Split, Croatia*

^b *Local Health Center Zagreb East*

^c *Psychiatry department, University Hospital Sisters of Charity, Zagreb, Croatia*

^d *Department of Surgery, University Hospital and School of Medicine Split, Croatia*

DOI: <https://doi.org/10.26800/LV-144-supl2-CR79>

 Nora Rako 0000-0001-7701-1224, Tea Cindrić 0000-0002-6509-1666, Hanna Pašić 0000-0001-9942-0838, Jasenka Kraljević 0000-0002-0725-6469

Keywords: laparoscopic surgery, pseudo-cysts, spleen, trauma

INTRODUCTION/OBJECTIVES: Post-traumatic splenic cysts are classified as secondary cysts. It is possible diagnosis in patient with lump in the left upper quadrant with or without other symptoms. After diagnosis is established, surgery should be performed early due to possible complications such as rupture and abscess formation.

CASE PRESENTATION: A 25-year old male patient presented with painless swelling in left upper quadrant. On physical examination, a large painless tumour was found in the left upper quadrant. Patient has past history of blunt abdominal trauma due to direct blow below left costal margin 5 years ago which he vaguely remembered. A month ago an abdominal U/S check-up was done and a compressive encapsulated cystic lesion of the spleen was found. It was filled with a dense liquid content. Contrast-enhanced abdominal MSCT confirmed the diagnosis of 19 cm large post-traumatic splenic pseudocyst. The patient underwent laparoscopic exploration, fenestration and decapsulation of the cyst. Pathologic examination displayed a fibrotic cystic wall with no epithelial lining, indicating a posttraumatic pseudocyst of the spleen. Postoperative recovery was uneventful and patient was discharged 6 days after with no postoperative complications.

CONCLUSION: This case has showed that splenic cysts can develop and present as left upper quadrant lump even five years after blunt abdominal trauma. Early surgical treatment of splenic cysts prevents complications due to rupture and abscess formation which can lead to peritonitis and hemoperitoneum. Laparoscopic surgery is procedure of choice for splenic cysts as a safe and effective approach with spleen preservation.

ABSTRACTS

Clinical Medicine

CM01

Survival analysis of COVID-19 in the population of Mexico.Polanco Armenta Christian Alexis^a^a Faculty of Medicine, National Autonomous University of MexicoDOI: <https://doi.org/10.26800/LV-144-supl2-CM01> Polanco Armenta Christian Alexis 0000-0002-8001-612X

Keywords: COVID-19, death, risk factors.

INTRODUCTION/OBJECTIVES: Deaths from COVID-19 during 2020 were the leading cause of death in Sonora, Mexico. The objective of this analysis is to identify the risk factors associated with deaths from COVID-19 in the population of Sonora, Mexico, through survival analysis.

MATERIALS AND METHODS: The data released by the Mexican Ministry of Health in confirmed cases with COVID-19 in Sonora, Mexico in the period from March 21, 2020 to October 31, 2021, were the ones used. This analysis includes 111,472 records of confirmed cases. The Kaplan-Meier method was used to draw the survival curves and their comparison using the log Rank test. These graphs served to test the assumption of proportional hazard. A Cox proportional hazards model that included the covariates of interest was fitted using a forward process, that is, from a null model, all covariates with $p < 0.05$. were included in the model and taking into account the information criterion and Akaike. The data was analyzed with the statistical package SPSS version 27.

RESULTS: 70.6% of deaths were in people admitted for emergencies. Except for asthma, the prevalence of each of the comorbidities was higher in the people who died than in those who survived. had a special role. pneumonia with prevalences of 18.6%, 16.4%, 11.6% and 10.9% respectively, although it was reliable that most of the patients died of pneumonia.

CONCLUSION: The risk of dying during the analysis period was higher for men, patients admitted to the emergency department, hospitalized people, individuals from older age groups, people who required intubation, patients with comorbidities, especially cardiovascular disease, pneumonia, HIV and diabetes. The cause for which the most infected died was due to pneumonia.

CM02

Botulin toxin A in lower lid entropion correctionAna Ninčević^a, Miro Kalauz^b, Josip Knežević^b, Sanja Masnec^b^a School of Medicine University of Zagreb, Zagreb, Croatia^b Department of Ophthalmology, University Hospital Center Zagreb, Zagreb, CroatiaDOI: <https://doi.org/10.26800/LV-144-supl2-CM02> Ana Ninčević 0000-0003-4815-4271, Miro Kalauz 0000-0001-7616-9871, Josip Knežević, Sanja Masnec 0000-0003-1472-0511

Keywords: botulinum toxin, senile entropion, treatment

INTRODUCTION/OBJECTIVES: to evaluate the clinical results and report the results of 12 cases of senile involutional entropion of the lower lid treated with botulinum toxin

MATERIALS AND METHODS: Twelve patients with senile entropion were treated with an injection of botulinum toxin. The mean age was $67,2 \pm 7,3$. The toxin (Botox; Allergan Corporation, Irvine, CA) was supplied in a vial contained 100 units of freeze-dried botulinum toxin A. This was reconstituted and diluted with 2 ml of saline which resulted with a concentration of five units in 0.1. The reconstituted toxin was injected over the orbicularis oculi muscle subcutaneously 4 mm below the eyelash margin of lower eyelid at three sites with a 30-gauge needle. Five units of the toxin were injected in each site (15 units total). The patients were examined 7 days after the application, 30 days and then monthly up to 1 year.

RESULTS: In all treated patients improvement of the eyelid margin was visible within three to four days after the injection with the duration which varied from 8 to 16 weeks. No complications or side effects of the treatment was recorded.

CONCLUSION: Botulinum toxin A can be effective temporary treatment for senile lower lid entropion.

CM03**EFFECTS OF COVID-19 PANDEMIC ON ONCOLOGICAL PATIENTS' DEMOGRAPHICS AND PET-CT UTILIZATION**

Berkin Ersoya^a, Elif Cengiz^b, Eylül Şenödeyici^b, Gizem Yildirim^c, Dengiz Koray Şahintürk^b, Mustafa Alperen Koşucu^b, Fatma Selin Soyluoğlu^d


^a University of Hamburg School of Medicine, Hamburg, Germany

^b Trakya University School of Medicine, Edirne, Turkey

^c Başkent University School of Medicine, Ankara, Turkey

^d Department of Nuclear Medicine, Trakya University School of Medicine, Edirne, Turkey

DOI: <https://doi.org/10.26800/LV-144-supl2-CM03>

 Berkin Ersoy 0000-0001-7111-648x, Elif Cengiz 0000-0002-5902-2904, Eylül Şenödeyici 0000-0002-4132-1594, Gizem Yildirim 0000-0001-5942-2169, Dengiz Koray Şahintürk 0000-0001-9865-0930, Mustafa Alperen Koşucu 0000-0002-2381-5099, Fatma Selin Soyluoğlu 0000-0003-4473-7138

Keywords: COVID-19, pandemic, PET-CT scan

INTRODUCTION/OBJECTIVES: Although the COVID-19 pandemic has created various health problems in many people, it has also caused disruptions in the clinical management of patients with existing cancerous disease. This retrospective cohort study aims to observe the impact of COVID-19 pandemic in PET-CT utilization, which has an important role in the diagnosis, staging, and follow-up of cancer patients.

MATERIALS AND METHODS: The data of 6053 patients who have undergone PET-CT imaging from 2019 to 2021 at the nuclear medicine department of Trakya University School of Medicine were analyzed. To examine the situation before and after COVID-19, we compared the 6-month periods in 2019, 2020, and 2021, starting from March 11, 2020, when the first case was seen in Turkey. Patients' age, type of cancer, and date of the PET-CT scans were recorded.

RESULTS: The mean ages of the patients admitted in 2019, 2020, and 2021 were 61.93, 61.16, and 61.57 years, respectively. Bronchus and lung cancer was the most common cancer type regardless of year or age groups with an average of 29.37%, followed by prostate cancer with 8.27% and 10.0%, in 2019 and 2021, respectively, while it was breast cancer with 11.48% in 2020. When compared with April 2019, PET-CT scan numbers had significantly declined in April 2020. A negative correlation was observed between the number of PET-CT scans and the number of COVID-19 cases from week one through week five.

CONCLUSION: The COVID-19 outbreak had a significant effect on PET-CT scans performed in Trakya University School of Medicine.

CM04**The impact of surgery type and prosthesis material on hearing results in stapes surgery**


Josipa Živko^a, Stela Marković^b, Andro Košec^c

^a Emergency medicine department, Clinical hospital Dubrava

^b School of Medicine University of Zagreb

^c Department of Otorhinolaryngology, Clinical hospital center "Sestre milosrdnice"

DOI: <https://doi.org/10.26800/LV-144-supl2-CM04>

 Josipa Živko 0000-0001-7297-5366, Stela Marković 0000-0003-2149-2422, Andro Košec 0000-0001-7864-2060


Keywords: ossicular prosthesis, otosclerosis, stapes surgery

INTRODUCTION/OBJECTIVES: Stapes surgery is generally performed for otosclerosis and there are numerous surgical techniques and prosthesis materials available. Constant evaluation of postoperative hearing outcomes is crucial for identification and further advancement of the current best option.

MATERIALS AND METHODS: This study is a retrospective analysis of the hearing threshold levels before and after stapedectomy/stapedotomy in 365 patients during a ten year period. The patients were classified in three groups depending on the prosthesis and surgery type (stapedectomy with Schucknecht's prosthesis placement and stapedotomy with either Causse's or Richard's prosthesis). The postoperative ABG was calculated by subtracting the BC PTA from the AC PTA.

RESULTS: The hearing threshold levels were evaluated preoperatively and postoperatively using pure-tone audiogram with frequency range from 250 Hz to 12 kHz. The results show the air-bone gap reduction to

CONCLUSION: The results were similar using the three observed options. The choice on the surgery type and prosthesis material should be made individually for each patient and the surgeon must be competent for using different surgical approaches in order to achieve the best results.

CM05**TOCILIZUMAB treatment in COVID-19**Lucija Vusić^a, Marija Gomerčić Palčić^b^a School of Medicine University of Zagreb^b Department of pulmonology, Sestre milosrdnice University Hospital Center ZagrebDOI: <https://doi.org/10.26800/LV-144-supl2-CM05> Lucija Vusić 0000-0001-9367-8651, Marija Gomerčić Palčić 0000-0002-6836-4447


Keywords: COVID-19, interleukin-6, tocilizumab

INTRODUCTION/OBJECTIVES: Tocilizumab (TCZ) is a humanized monoclonal antibody against the interleukin-6 (IL-6) receptor. It is found that IL-6 is one of the most important cytokines involved in COVID-19-induced cytokine storms and its higher levels are found in critically ill patients with COVID-19. Real-life data about the effect of TCZ on the inflammatory activity in COVID-19 patients as well as its side effects are still missing.

MATERIALS AND METHODS: This is a retrospective observational study conducted from October 2021 until January 2022 in the COVID-19 Departments and Intensive Care Units of Sestre milosrdnice University Hospital Center in Zagreb. Tocilizumab was administered intravenously at 8 mg/kg body weight to 31 patients, 7 females and 24 males who had high levels of interleukin-6.

RESULTS: The average age of those patients was 60 years. 13 of them had an excellent response resulting in rapid respiratory recovery and were dismissed from the hospital. However, 18 of them died. The most common comorbidity was type 2 diabetes mellitus. During the follow-up period, the most frequent complications were thromboembolic events and nosocomial infections.

CONCLUSION: Tocilizumab has shown to be effective in certain subpopulations of critically ill patients with COVID-19 in our Center. However, some factors, such as levels of IL-6, duration of disease, and comorbidities, need to be taken into consideration before starting the treatment.

CM06**Aortic root valve-sparing surgery: influence on the left ventricle**Lorka Tarnovski^a, Igor Rudež^b^a Family medicine practice „dr. Ivančica Peček“, Health center Zagreb West^b Department of Cardiac and Transplant Surgery, University Hospital „Dubrava“DOI: <https://doi.org/10.26800/LV-144-supl2-CM06> Lorka Tarnovski 0000-0002-6576-8614, Igor Rudež 0000-0002-7735-6721

Keywords: aortic regurgitation, aortic root surgery, valve-sparing


INTRODUCTION/OBJECTIVES: Aortic regurgitation (AR) is a state of excessive blood return from the aorta to the left ventricle (LV) during diastole. Surgical therapy of AR includes valve-sparing surgery (AVRep) with or without root and ascending aorta replacement or valve replacement (AVR).

MATERIALS AND METHODS: The research included a total of 158 patients (30 women and 128 men, the average age 53.7 ± 14.1 years) who underwent surgical treatment for AR in Clinical hospital Dubrava between 2014 and 2020. AVRep was used in 107, and AVR in 58 patients. Patients had done the preoperative, postoperative and follow-up transthoracic echocardiography.

RESULTS: Significantly more patients with NYHA grade I (30 vs 10, $p = 0.002$) and II (68 vs 28, $p < 0.001$) underwent AVRep, and more postoperative trivial (27 vs 2, $p < 0.001$) and mild (14 vs 0, $p < 0.001$) AR were noted after AVRep. There was no difference in ejection fraction (LVEF) and LV diameters postoperatively. An initial postoperative decrease of LVEF and a later increase in LVEF were noted, but significantly more after AVRep (58 vs 54, $p = 0.005$). A multiple regression analysis enhanced a slight negative effect of AVR method on LVEF in follow-up, more pronounced in older men ($\beta = -4.21$, $R^2 = 0.0431$, $p = 0.009$).

CONCLUSION: AVRep has shown to be a method of choice for patients with the dilatation of the aortic root and slightly deformed valves. In comparison to AVR, AVRep results in lower mortality and lower incidence of thromboembolic events. The AVRep showed a significant LV function recovery as well, especially in women and younger.

CROSS

CM07**Evaluation of Quantipheron (QFN) SARS-CoV-2 in vaccinated and recovered individuals**Ana Horvat^a, Marija Gomerčić Palčić^b^a School of Medicine, University of Zagreb^b Sestre milosrdnice University Hospital Center, ZagrebDOI: <https://doi.org/10.26800/LV-144-supl2-CM07> Ana Horvat 0000-0003-1062-5306, Marija Gomerčić Palčić 0000-0002-6836-4447


Keywords: antibody , cell immunity, COVID-19

INTRODUCTION/OBJECTIVES: Quantipheron (QFN) SARS-CoV-2 is a new test in which lymphocytes involved in cell immunity, in fully heparinized blood, are stimulated by combination of antigens specific for SARS-CoV-2. QFN SARS-CoV-2 is interferon gamma release assay (IGRA).

MATERIALS AND METHODS: In this prospective study, conducted from December 2021 until January 2022 in University Hospital Center Sestre milosrdnice in Zagreb, we evaluated both the total antibody and T cell responses in a cohort of COVID-19 convalescents who were vaccinated with two doses compared to the individuals only vaccinated with two doses. Blood specimens were collected from 16 subjects at different time points after the COVID-19 vaccination (5 of them were PCR-confirmed convalescent individuals) to measure durability of humoral and cell-mediated immune response.

RESULTS: Interestingly 9 out of 16 vaccinated patients didn't have CD4+ and CD8+ T cell-mediated responses in SARS-CoV-2-vaccinated subjects and only one patient had no antibodies at all. 2 out of 5 patient who were convalescents also didn't have evidence of T cell responses.

CONCLUSION: Quantipheron (QFN) SARS-CoV-2 could be useful tool to assess who needs an extra dose of vaccination and is possibly under the risk of evolving severe disease.

CM08**The role of anterolateral ligament in anterior cruciate ligament reconstruction – plantaris tendon graft technique**Mario Josipović^a, Josip Vlaić^b, Jure Serdar^a, Marko Šimunović^c, Dinko Nizić^d, Mislav Jelić^a^a Department of Orthopaedic Surgery, University Hospital Centre Zagreb, School of Medicine, University of Zagreb^b Division of Paediatric Orthopaedic Surgery, Children's Hospital Zagreb^c Department of Radiology, University Hospital Centre Zagreb, University of Zagreb School of Medicine^d Department of Radiology and Ultrasound Diagnostics, Special Hospital for Pulmonary DiseasesDOI: <https://doi.org/10.26800/LV-144-supl2-CM08> Mario Josipović 0000-0002-6096-2872, Josip Vlaić 0000-0001-6381-8684, Jure Serdar 0000-0003-0506-2190, Marko Šimunović 0000-0001-7689-6315, Dinko Nizić 0000-0002-0924-7048, Mislav Jelić 0000-0003-1806-1349

Keywords: anterior cruciate ligament, anterolateral ligament, graft, plantaris tendon

INTRODUCTION/OBJECTIVES: Anterior cruciate ligament (ACL) reconstruction is the principal treatment option in symptomatic patients with ACL rupture. Regardless of the technique utilised, ACL reconstruction alone could not always restore normal knee kinematics, especially rotational stability. Moreover, present techniques mostly use autografts such as hamstring tendons and additionally disrupt the knee biomechanics. The anterolateral ligament (ALL) of the knee has been recognised as an important structure in providing rotational knee stability. Concurrent reconstruction of ACL and ALL ligaments has proven superior in both clinical stability tests and subjective outcome scores. Using plantaris tendon as ALL graft, detrimental effects of harvesting two hamstring tendons are avoided.

MATERIALS AND METHODS: Symptomatic patients with ACL deficient knee that underwent concomitant ACL and ALL reconstruction using one hamstring tendon and plantaris tendon were evaluated. Anteroposterior and rotational knee laxity were evaluated as well as objective and subjective outcome scores.

RESULTS: Results showed marked reduction in anteroposterior and rotational knee laxity measured with Lachman and Pivot shift test. Outcome scores showed high rate of patient satisfactory and return to pre-injury level of activity.

CONCLUSION: PT autograft can be used for ALL reconstruction regardless of surgical technique utilised. Furthermore, it can be performed as single ALL reconstruction in cases of residual laxity after ACL reconstruction or as a combined ACL and ALL reconstruction in cases of primary and revision ACL surgery.




CM09**A COMPARISON OF PROSTATE BIOPSIES AND PROSTATE CANCER DIAGNOSIS MADE BEFORE AND DURING COVID-19 PANDEMIC**

Stjepan Frkanec^a, Toni Zekulić^b, Hrvoje Saić^b, Ilija Jurić^b, Tomislav Kuliš^{a,b}, Željko Kaštelan^{a,b}

^a University of Zagreb School of Medicine, Zagreb, Croatia

^b Department of Urology, University Hospital Centre Zagreb, Zagreb, Croatia

DOI: <https://doi.org/10.26800/LV-144-supl2-CM09>

 Stjepan Frkanec 0000-0003-2309-3783, Toni Zekulić 0000-0002-3498-0217, Hrvoje Saić 0000-0001-5667-0781, Ilija Jurić 0000-0001-9681-3655, Tomislav Kuliš 0000-0002-0895-5691, Željko Kaštelan 0000-0002-9262-3234

Keywords: biopsy, COVID-19, number, pandemic, prostate cancer

INTRODUCTION/OBJECTIVES: Prostate cancer (PC) is the first cancer diagnosis in men in Croatia and fifth in mortality worldwide. PC often has no symptoms, therefore early diagnosis is important. Since the end of 2019, the world has been under the threat of COVID-19 pandemic. Social interactions and other normal activities, including medical examinations, were commonly seen as potential places of danger. Because of this, many hospitals reported lower numbers of medical examinations and diagnoses (e.g. 37,9% decrease in the number of prostate biopsies reported by Kaufman et al 2021).

MATERIALS AND METHODS: In this retrospective study, we will evaluate the number and results of prostate biopsies in the department of Urology, University Hospital Center Zagreb, during 2 years of the COVID-19 pandemic (2020, 2021). We also compare the results of biopsies made in 2020 and 2021 with the results of biopsies made in 2018 and 2019, before the pandemic occurred.

RESULTS: During 2 years of pandemic a total of 1237 patients underwent prostate biopsy (decrease 25,21% from the previous two year period), in 2020, 577 (decrease 32,67%) and in 2021, 660 (decrease 22,98%) biopsies were performed. In comparison, throughout 2018 and 2019 there were a total of 1654 biopsies, in 2018, 797 and in 2019, 857 biopsies.

CONCLUSION: Although the department of UHC Zagreb was one of the few departments that continued to perform prostate biopsies during the lockdown periods in COVID-19 pandemic there were still significantly fewer biopsies. This study is an excellent starting point for further analysis and studies on this topic.

CM10**Plantaris tendon autograft successfully restores patellar stability in adolescent isolated medial patellofemoral ligament reconstruction – preliminary results**

Josip Vlaić^a, Mario Josipović^b, Mislav Jelić^c

^a Division of Pediatric Orthopedic Surgery, Children's Hospital Zagreb

^b Department of Orthopaedic Surgery, University Hospital Centre Zagreb

^c Department of Orthopaedic Surgery, University Hospital Centre Zagreb, School of Medicine, University of Zagreb

DOI: <https://doi.org/10.26800/LV-144-supl2-CM10>

 Josip Vlaić 0000-0001-6381-8684, Mario Josipović 0000-0002-6096-2872, Mislav Jelić 0000-0003-1806-1349

Keywords: gracilis tendon, medial patellofemoral ligament reconstruction, patellar instability, plantaris, tendon, tendon graft

INTRODUCTION/OBJECTIVES: Patellar instability is highly represented in adolescent patients. For a group of patients with patellar instability, isolated medial patellofemoral ligament reconstruction (MPFLR) is a standard treatment option. Although gracilis tendon (GRT) autograft has been frequently used, the optimal surgical approach and graft source for this procedure is yet to be established. The use of plantaris tendon (PLT) autograft in isolated MPFLR has never been compared to GRT autograft. The purpose of this study is to determine whether a four-folded PLT autograft used for isolated anatomic MPFLR in adolescent patients restores patellar stability.

MATERIALS AND METHODS: This is a retrospective study analyzing the results of isolated anatomic MPFLR in adolescent patients operated in the Children's Hospital Zagreb between 2016 and 2021. 15 patients, 16 knees (6 females, mean age 16.5) underwent anatomic isolated MPFLR using the same surgical technique. In 11 adolescents, two-folded GRT autograft was used, while four-folded PLT was used in 4 adolescents. Patients were clinically evaluated (patellar apprehension test, J sign) and compared before surgery and at the final follow-up. The successful outcome was a return to sporting activities.

RESULTS: Out of 15 operated patients, 2 within the GRT group needed additional surgery – distal patellar realignment due to repeated patellar dislocation. All other adolescents had excellent clinical results- patellar apprehension test negative and return to sporting activities.

CONCLUSION: We showed that four-folded PLT autograft used for adolescent isolated anatomic MPFLR restored patellar stability. However, further larger comparative clinical studies are needed to validate this approach.

CM11**Predictors of adrenal crisis in patients with Addison's disease**

Tea Cindrić^a, Gaja Tolić^b, Tea Stipetić^b, Hanna Pašić^c, Matea Mataković Trivunčević^d, Nora Rako^e, Tina Dušek^f

^a Health Centre Zagreb-East

^b School of Medicine, University of Zagreb


^c Department of Psychiatry, University Hospital Centre Sestre Milosrdnice

^d Department of pulmonary and infectious diseases, Nordsjaellands Hospital

^e Emergency Department, Internal Medicine Department, University Hospital and School of Medicine Split

^f Department of Endocrinology and Diabetology, University Hospital Center Zagreb; School of Medicine, University of Zagreb

DOI: <https://doi.org/10.26800/LV-144-supl2-CM11>

 Tea Cindrić 0000-0002-6509-1666, Gaja Tolić 0000-0002-5978-3973, Tea Stipetić 0000-0002-4928-4839, Hanna Pašić 0000-0001-9942-0838, Matea Mataković Trivunčević 0000-0003-0981-6682, Nora Rako 0000-0001-7701-1224, Tina Dušek 0000-0002-1266-3501

Keywords: Addison's disease, adrenal crisis, risk factors

INTRODUCTION/OBJECTIVES: Addison's disease is the inability of the adrenal glands to produce cortisol and aldosterone, which must be replaced by medication. During stress or acute illness, there is a risk of adrenal crisis and it is important to adjust the dose of medication. The aim of this study was to find out how well Addison's disease patients are educated about their disease, its treatment, how often adrenal crisis occurs in these patients, and what the predictive factors are for developing adrenal crisis based on their knowledge.

MATERIALS AND METHODS: The study was conducted through a telephone survey to which the patients consented. The questionnaire included questions about their diagnosis, risk factors and symptoms of adrenal crisis, and dose adjustment. The participants are treated at the UHC Zagreb. Statistical analysis was performed using Statistical Package for the Social Sciences version 17.0 for Windows.

RESULTS: Some individuals knew the origin of their disease, but most did not. The majority (18/22) have a substitute medicine somewhere. Also, 12 knew more than three risk factors and 13 out of 22 knew more than three symptoms of adrenal crisis. The patients were divided into two groups. The first included those who had experienced an adrenal crisis (N=11) and the second included those who had never experienced one (N=11). Those who had experienced an adrenal crisis knew significantly fewer risk factors for developing a crisis than patients who had never had it (P=0.03).

CONCLUSION: Educating patients about the risk factors that precede an adrenal crisis is important to prevent this medical emergency.

ABSTRACTS

Literature review


LR01

"Have a safe flight" without barotraumas

Miruna Ioana Chirilă^a, Andra Diana Tanasa^a, Ioana Lipan^a, Răzvan Constantin Ursachi^a

^a *University of Medicine and Pharmacy "Grigore T. Popa"*

DOI: <https://doi.org/10.26800/LV-144-supl2-LR01>

 Miruna Ioana Chirilă 0000-0003-1633-1691, Andra Diana Tanasa 0000-0002-3142-5250, Ioana Lipan 0000-0002-2224-6867, Răzvan Constantin Ursachi 0000-0003-4388-817X

Keywords: allergic rhinitis, barotrauma, ENT

INTRODUCTION/OBJECTIVES: The beauty of the skiers is invaluable for millions of air travelers. A proportion of them have ENT conditions. Otic barotraumas in air transport involve usually traumatic inflammation of the middle ear caused by a pressure difference between the air in the middle ear and the external atmosphere, developing after ascent or more usually descent. This can affect passengers as well as flight attendants or pilots. This type of barotrauma is much more common in patients with allergic rhinitis (AR), due to inflammation of the membrane of the nose and especially inflammation of the orifice of the Eustachian tube. Our aim is to shine some light on the importance of prophylactic methods for patients diagnosed or suspected of having AR so that they do not suffer from middle ear barotrauma (MEB).

MATERIALS AND METHODS: We conducted a literature search in the PubMed database concerning barotraumas and ENT conditions.

RESULTS: Patients with AR should follow hygiene measures and also knowing and avoiding allergens and using equalization techniques before flights. Treatment with oxymetazoline or fluticasone can be administered intranasally, 30 minutes before descent, to facilitate middle ear equalization. Pseudoephedrine decongestants can reduce otalgia in recurrent ear pain during air travel. Indirect moxibustion may also have a good clinical effect on the overall treatment of AR. For pilots and flight attendants a nine-step inflation-deflation tympanometric test can be used. This can provide information about Eustachian tube function to reduce the risk of recurrence of MEB.

CONCLUSION: For a more pleasant flight, travelers should consider these methods of decongestion.

LR02


ALZHEIMER – FEELING YOUNG, MIGHT FORGET LATER

Adrian Iulian Ababei^a, Andra Diana Tanasa^b

^a *"Alexandru Ioan Cuza" University, Biology, Iași, Romania*

^b *University of Medicine and Pharmacy "Gr. T. Popa", General Medicine, Iași, Romania*

DOI: <https://doi.org/10.26800/LV-144-supl2-LR02>

 Adrian Iulian Ababei 0000-0001-7711-7096, Andra Diana Tanasa (0000-0002-3142-5250)

Keywords: Alzheimer, beta-amyloid, brain, test


INTRODUCTION/OBJECTIVES: Alzheimer's disease (AD) affects about 17 million people worldwide, causing serious disorders of memory and cognition. This condition is caused by elevated levels of beta-amyloid (β -A) in the brain, leading to the degeneration of brain cells. Elevated β -A is neurotoxic and causes oxidative stress in the brain, which leads to neurodegeneration and dementia. At present, no sensitive and cost-effective method is available for the detection of β -A. Our aim is to shine some light on the importance of making this blood test a regular screening procedure.

MATERIALS AND METHODS: We systematically reviewed multiple papers focused on the development of a fast and inexpensive test to diagnose the early stages of dementia caused by AD.

RESULTS: When a patient complains of forgetfulness, a neurologist may not know immediately whether this is due to AD. Diagnostic tools to detect AD are either invasive like cerebrospinal fluid biomarkers or costly like PET-CT. We determine the modification of the secondary structure of β -A in human blood. Besides different types of scans and immunoassays, to estimate the amount of β -A in the brain, the blood tests measuring the hallmark AD's protein, β -A, could reduce the cost of clinical trials and potentially open the door to treating the disease earlier. The best-performing blood test identified people with elevated β -A levels with an accuracy of about 85%.

CONCLUSION: As it is crucial to diagnose AD as early as possible, we believe that this test could be the key of screening, prognostic and diagnosis.

LR03**Myocarditis following COVID – 19 mRNA vaccine administration**Mladen Pospišil^a, Eva Pleško^b, Lucija Pešorda^c^a *Institute of emergency medicine of Zagreb County*^b *Krapina-Zagorje County Community Health Centre*^c *Bjelovar-Bilogora County Community Health Centre*DOI: <https://doi.org/10.26800/LV-144-supl2-LR03>

 Mladen Pospišil 0000-0002-9462-2593, Eva Pleško 0000-0003-2925-359, Lucija Pešorda 0000-0002-8630-2792

Keywords: COVID-19, mRNA vaccine, myocarditis


INTRODUCTION/OBJECTIVES: Development of effective vaccines marked the beginning of the end for COVID-19 pandemic. Even though they represent key factor in combatting the disease, adverse events were reported following the administration of Pfizer-BioNTech and Moderna mRNA vaccines and among them myocarditis. The aim of this review was to present key points of myocarditis following the administration of Pfizer-BioNTech and Moderna mRNA vaccines like: epidemiological characteristics, clinical features, investigation and treatment.

MATERIALS AND METHODS: In providing information PubMed and Google Scholar data from June 2021 to January 2022 was analyzed alongside UK Health Security Agency guidelines for clinical management of myocarditis.

RESULTS: The recent studies show that myocarditis is a very rare adverse event predominantly affecting young males under the age of 30 with time to onset of approximately seven days after receiving the second dose. The symptoms include: fever, lethargy, significant chest pain or discomfort, tachypnea, shortness of breath, pain while breathing, palpitations and syncope. Initial investigation's results show sinus tachycardia, arrhythmias, conduction delays or non-specific ST segment and T wave changes in a 12 lead electrocardiogram. The lab results show elevation of troponin and inflammatory blood markers' levels. Cardiac imaging results are consistent with the diagnosis of myocarditis. Myocarditis following immunization using mRNA vaccine is usually mild and self-limiting disease without the need for treatment, although avoiding exercise is recommended.

CONCLUSION: In conclusion, myocarditis as an adverse event should be considered in a differential diagnosis of recent-onset chest pain if vaccination exists in patient's history since not everything is acute coronary syndrome.

LR04**Rethinking the basics: the usefulness of Lasegue's sign in diagnosing intervertebral disc herniation; a literature review**Dora Dragaš^a, Đidi Delalić^b, Josip Kajan^c, Dean Mileta^d^a *Emergency Internal Medicine Clinic, Clinical Hospital Merkur, Zagreb*^b *University of Zagreb School of Medicine, Zagreb*^c *University of Osijek School of Medicine, Osijek*^d *Emergency Internal Medicine Clinic, Clinical Hospital Merkur, Zagreb*DOI: <https://doi.org/10.26800/LV-144-supl2-LR04>

 Dora Dragaš 0000-0001-5042-8679, Đidi Delalić 0000-0003-2102-2586, Josip Kajan (0000-0002-4844-3260, Dean Mileta 0000-0003-1713-6126


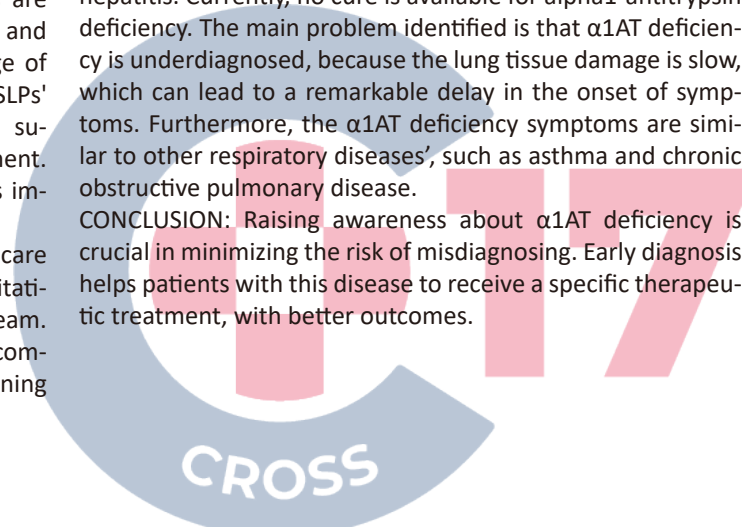
Keywords: Intervertebral Disc Herniation, Lasegue's sign, Physical Examination

INTRODUCTION/OBJECTIVES: Lasegue's sign, or straight leg raise test, is a well-known part of the physical examination of the musculoskeletal system. It is taught religiously in medical schools and textbooks all around the world in both physical examination classes and later in internal medicine and orthopedics. However, is it good enough in diagnosing intervertebral disc herniation? This review aims to find out.

MATERIALS AND METHODS: A search of the available literature was performed using the PubMed database, using the search term "Lasegue's sign". The search yielded 109 results, which were filtered to only include original research papers. Following the filtering process, 3 original research papers were deemed suitable for inclusion in this review.

RESULTS: Overall, the sensitivity of LS when compared to MRI is defeatingly low – 18.1%, however, when compared to other clinical tests, LS had a decent sensitivity of 77-83%. The interrater reliability of LS was shown to be 0.33, with a positive agreement proportion of only 33%. Among the clinical signs compared to LS, the slump test was shown to have a significantly better sensitivity when compared to LS (85.7% vs 28.6%) and the bell test, hyperextension test and crossed Lasegue's sign were all shown to have slightly to moderately better interrater reliability.

CONCLUSION: While Lasegue's sign can be a valuable tool in screening for herniated discs in patients with low back pain, it is certainly not the only nor the best option available and more effort should be invested into teaching students and medical practitioners about the other available clinical signs.

LR05**SLP and the Pandemic: Speech-Language Pathologists' Role in Management and Rehabilitation of Patients with COVID-19**Paola Danjek^a^a *Clinical Hospital Dubrava; Faculty of Education and Rehabilitation Sciences, University of Zagreb*DOI: <https://doi.org/10.26800/LV-144-supl2-LR05> Paola Danjek 0000-0003-0640-5140**Keywords:** COVID-19, dysphagia, dysphonia, rehabilitation, speech-language pathology**INTRODUCTION/OBJECTIVES:** Since the declaration of the global pandemic of Coronavirus Disease 2019 (COVID-19) in March 2020 healthcare system has faced many challenges. Speech-language pathologists (SLPs) as healthcare professionals had to adapt to new work settings and also had to find a place within a multidisciplinary team that takes care of patients with COVID-19. This work aims to define and describe speech-language pathologists' role in the management and rehabilitation of patients with COVID-19.**MATERIALS AND METHODS:** This literature review is based on a Web of Science and PubMed database search completed in February 2022. The following keywords were used: (((COVID-19) AND (speech-language pathology)) NOT (telepractice)) NOT (telerehabilitation)).**RESULTS:** Patients with severe COVID-19 are at risk for developing communication, language, speech, voice and swallowing disorders as a result of intubation and due to respiratory and neurological complications. Frequent complications associated with COVID-19 are dysphagia and dysphonia. SLPs are engaged throughout the whole rehabilitation process, and they have different assignments depending on the stage of recovery. During the acute phase, in intensive care units, SLPs' tasks include dysphagia screening and communication support. In inpatient units, SLPs provide dysphagia treatment. Swallowing, voice, language and speech rehabilitation is implemented in outpatient medical facilities.**CONCLUSION:** Speech-language pathologists as healthcare professionals participate in the management and rehabilitation of patients with COVID-19 within a multidisciplinary team. Considering the clinical presentation of COVID-19 and its complications, it is clear that SLPs have a crucial role in regaining quality of life.**LR06****SPREADING THE WORD ABOUT ALPHA1-ANTITRYPSIN DEFICIENCY**Andra Diana Tanasa^a, Adrian Iulian Ababei^b^a *University of Medicine and Pharmacy "Gr. T. Popa" Iasi*^b *"Alexandru Ioan Cuza" University, Biology*DOI: <https://doi.org/10.26800/LV-144-supl2-LR06> Andra Diana Tanasa 0000-0002-3142-5250, Adrian Iulian Ababei 0000-0001-7711-7096**Keywords:** deficiency, liver, lung**INTRODUCTION/OBJECTIVES:** Alpha1-antitrypsin is synthesized mainly in the liver and to a lesser degree, by neutrophils and macrophages. Individuals with α 1AT deficiency are prone to early onset lung and liver disease. This condition is the most common genetic cause of liver disease in children and an underappreciated cause of liver disease in adults. My aim is to highlight the current knowledge of this condition in hopes of better understanding its role in these diseases and raise awareness regarding the early diagnosis of this deficiency, in order to avoid major deteriorations, misdiagnosis and to ensure an efficient treatment.**MATERIALS AND METHODS:** Various papers were analyzed, using the PubMed database, and studies which focused on proteinase inhibitors, alpha1-antitrypsin and causes of liver disease.**RESULTS:** α 1AT deficiency is characterized by pulmonary disease, especially emphysema and bronchiectasis, and hepatic disease. The Z allele variant, where mutant protein is accumulated within hepatocytes, results in cirrhosis and neonatal hepatitis. Currently, no cure is available for alpha1-antitrypsin deficiency. The main problem identified is that α 1AT deficiency is underdiagnosed, because the lung tissue damage is slow, which can lead to a remarkable delay in the onset of symptoms. Furthermore, the α 1AT deficiency symptoms are similar to other respiratory diseases', such as asthma and chronic obstructive pulmonary disease.**CONCLUSION:** Raising awareness about α 1AT deficiency is crucial in minimizing the risk of misdiagnosing. Early diagnosis helps patients with this disease to receive a specific therapeutic treatment, with better outcomes.


LR07**The smell of Parkinson**

Miruna Ioana Chirilă^a, Adrian Iulian Ababei^b, Răzvan Constantin Ursachi^a

^a *University of Medicine and Pharmacy "Grigore T. Popa"*

^b *"Alexandru Ioan Cuza" University, Biology, Iași, Romania*

DOI: <https://doi.org/10.26800/LV-144-supl2-LR07>

 Miruna Ioana Chirilă 0000-0003-1633-1691, Adrian Iulian Ababei 0000-0001-7711-7096, Răzvan Constantin Ursachi 0000-0003-4388-817X

Keywords: olfactometry, Parkinson, test

INTRODUCTION/OBJECTIVES: Olfactory malfunction is one of the first non-motor signs of Parkinson's disease (PD). This dysfunction occurs in about 90% of early-stage PD cases and can precede the onset of motor symptoms by years. The mechanisms responsible for olfactory dysfunction are presently unknown, but we can diagnose this condition prematurely through olfactometry. Our review's purpose is to highlight the importance of this test for the elderly patients, after 65 years old, or for patients with risk factors such as genetics or environmental factors, a decreased level of dopamine or the presence of Lewy bodies in the brain.

MATERIALS AND METHODS: Various papers were analyzed, using the PubMed database, and studies which focused on this particular test and Parkinson in general.

RESULTS: A quantitative assessment of olfactory function was conducted using the T and T olfactometer assays. This test includes five types of odors at different concentrations. Odor deficiency is a feature of PD. Recent evidence suggests that over 90% of PD patients are diagnosed with significant olfactory loss. Olfactory loss in DP has a bilateral and general character and all olfactory fields are concerned. Clinical tests are available to quickly characterize olfactory dysfunction, including odor testing. Olfactory tests may establish hyposmia by identifying odors, assessing, discriminating and the odor detection threshold. Considerable efforts are being made to develop preventative or disease-modifying therapies that slow or halt the progression of PD.


CONCLUSION: Since it is essential to diagnose PD as early as possible, we believe olfactory tests could be the key to detection, prognosis and diagnosis.

LR08**TRANSDERMAL FENTANYL PATCH: A SMOOTH CRIMINAL**

Andra Diana Tanasa^a, Miruna Ioana Chirila^a, Ioana Lipan^a

^a *University of Medicine and Pharmacy "Gr. T. Popa" Iasi*

DOI: <https://doi.org/10.26800/LV-144-supl2-LR08>

 Andra Diana Tanasa 0000-0002-3142-5250, Miruna Ioana Chirila 0000-0003-1633-1691, Ioana Lipan 0000-0002-2224-6867


Keywords: fentanyl, opioid, toxicity

INTRODUCTION/OBJECTIVES: Fentanyl is a synthetic opioid analgesic used in anesthesia and pain management. There is an ongoing opioid overdose pandemic and this illicit use of fentanyl is derived from either illegally manufactured fentanyl or manipulation of medicines which contain fentanyl, especially fentanyl transdermal patches. There have been reported numerous cases of abuse and incorrect use of these patches, leading to death. Our objective is to shine some light on this matter and present the lifethreatening consequences related to fentanyl overdose.

MATERIALS AND METHODS: A literature search was conducted, using the PubMed database. In addition to this, pharmacology and toxicology textbooks were consulted. The search terms included were "fentanyl", "patch", "overdose", "toxicity".

RESULTS: Due to its high potency, rapidity of action and narrow therapeutic index of fentanyl, misuse and abuse happen often. The fentanyl that has been extracted from the patch can be administered through inhalation, intravenously and insufflation, by oral and transmucosal application, or by rectal insertion. Unintentional misuse and therapeutic error may occur because, after usage of a patch, a depot is formed into the keratinaceous layer of the epidermidis, which is associated with a slow onset and prolonged effects after administration. Naloxone is used for fentanyl overdose rescuing, although, most patients can't be revived.

CONCLUSION: There needs to be a clearer guide for patients using these patches, in order to limit the risk of error. A more in-depth analysis of the fentanyl transdermal patch delivery system is needed and more suitable therapeutic alternatives need to be suggested.

LR09**Demodex- a silent "friend"**Adrian Iulian Ababei^a, Miruna Ioana Chirilă^b^a "Alexandru Ioan Cuza" University, Biology, Iași, Romania^b University of Medicine and Pharmacy "Gr. T. Popa", General Medicine Iași, RomaniaDOI: <https://doi.org/10.26800/LV-144-supl2-LR09> Adrian Iulian Ababei 0000-0001-7711-7096, Miruna Ioana Chirilă 0000-0003-1633-1691

Keywords: Blepharitis, Demodex, ectropion, glands

INTRODUCTION/OBJECTIVES: Demodex is commonly found in the human population, in skin sebaceous glands or follicles. The frequency of Demodex infection increases with age, as it is mainly diagnosed after the age of seventy. Demodex folliculorum and Demodex brevis (commonly referred to as Demodex) are the most common human osteoporosis. Demodex folliculorum occurs in the hair follicle (especially in genes), while Demodex brevis occurs in the sebaceous glands.

MATERIALS AND METHODS: We systematically reviewed multiple papers focused on the Demodex infections through the PubMed search engine.

RESULTS: Most people only carry Demodex and do not develop symptoms. Demodex mites are usually harmless, but they can cause problems for people with weakened immune systems. Demodex infection usually remains asymptomatic and may have a pathogenic role only when it occurs at high densities and due to an immune imbalance. If blepharitis is of bacterial origin, long-term effects include loss of eyelashes, ectropion (reversal of the edge of the eyelid, most commonly of the lower eyelid, exposing the conjunctiva), thickening of the edge of the eyelids, dilated and visible capillaries, trichosis and entropion). Changes in the genes can cause corneal erosions that can become infected and lead to severe vision damage.

CONCLUSION: Blepharitis treatment involves a daily regimen of warm compresses and eyelid scrub to remove the build-up of biofilm and bacterial overgrowth from the eyelid margins. This eyelid hygiene routine is very helpful to treat and control blepharitis, but only if performed properly and regularly.



ABSTRACTS

Other

O01

Comparison of clinical guidelines for the treatment of acute uncomplicated cystitis

Matej Lovrić^a, Petra Kovačević^a, Franciska Lovrić^a, Kamelija Horvatović^b

^a School of Medicine, University of Mostar, Bosnia and Herzegovina

^b Faculty of Science, University of Zagreb, Croatia

DOI: <https://doi.org/10.26800/LV-144-supl2-O01>

Matej Lovrić 0000-0001-9882-2632, Petra Kovačević 0000-0001-5449-3427, Franciska Lovrić 0000-0001-5008-8934, Kamelija Horvatović 0000-0002-3424-1326

Keywords: acute uncomplicated cystitis, antibiotics, guidelines, urinary infection

Acute uncomplicated cystitis (AUC) is one of the most common infections majority of women will experience. More than 60% are experiencing AUC at least once and 10% almost yearly. Urinary infection may be defined as AUC in non-pregnant women without developmental urinary tract anomalies or comorbidities. Corresponding to its incidence, around 15% of all out-of-clinic antibiotics prescribed for AUC in Europe and USA, raising the need for adequate and regular prescription evaluation. Following an extensive literature review, we compared Croatian National Guidelines of antimicrobial treatment and prophylaxis of urinary tract infections (ISKRA) 2009, National Institute for Health and Care Excellence England Guidelines (NICE) 2018, Korean Clinical Practice Guidelines for Antibiotic Treatment of Community-Acquired Urinary Tract Infections 2018, and European Association of Urology 2021 Guidelines on Urological Infections (EUA). All studied guidelines recommend Nitrofurantoin 100 mg per os twice a day as the drug of choice. However, treatment duration varies slightly. ISKRA recommends 7 days of Nitrofurantoin therapy, whereas other guidelines have set the duration to 3 and 5 days, respectively. EUA also advises the use of Fosfomycin trometamol and Pivmecillinam for AUC. Due to the high resistance of E.coli to trimethoprim/sulfamethoxazole in Korea, fluoroquinolones are preferred in empirical approach. With this study we aimed to analyze the discrepancies between different guidelines to evaluate the need for 13-year-old ISKRA guidelines to be reassessed and updated. Further studies on this matter, along with E. coli resistance estimation need to be conducted to assure optimal treatment options for this largely prevalent disease.

O02

Comparison of Drug Consumption in Croatia in Prepandemic 2019 and Pandemic 2020

Anton Malbašić^a, Antonia Bukovac^a, Gabrijele Buljan^a, Sandro Gašpar^b

^a School of Medicine, University of Zagreb, Croatia

^b Department of Radiology, Children's Hospital Zagreb, Croatia

DOI: <https://doi.org/10.26800/LV-144-supl2-O02>

Anton Malbašić 0000-0002-8699-8662, Antonia Bukovac 0000-0002-0412-433X, Gabrijele Buljan 0000-0003-4060-9497, Sandro Gašpar 0000-0001-8941-1831

Keywords: Economics, Health Expenditures, OTC Drugs, Prescription Drugs

INTRODUCTION/OBJECTIVES: Drug consumption (DC) has a continuous positive yearly trend in Croatia, and, as the lifestyle and health of the population has changed over the course of 2020 because of the COVID-19 pandemic, we wanted to compare DC before and during the pandemic.

MATERIALS AND METHODS: We analysed the data published by The Agency for medical products and medical devices of Republic of Croatia. We observed the overall DC and DC in different Anatomical Therapeutic Chemical System groups, in croatian kuna (HRK) and in DDD/1000/day units.

RESULTS: Overall DC increased by 9,03% (from 7.649.563.162,00 HRK in 2019 to 8.408.855.389,00 HRK in 2020). The increase is also applicable to DC in DDD/1000/day (+3,08%: from 1.280,50 in 2019 to 1.321,16 in 2020). The greatest increase is seen in Antineoplastic and immunomodulating agents consumption (L group, +27,94% in HRK, but only increased by 4,12% in DDD/1000/day), as well as consumption of Cardiovascular drugs (C group, +16,12% in DDD/1000/day) and GI and metabolism drugs (A group, +15,60% in DDD/1000/day). Data has shown a decrease in Antiparasitics, insecticides and repellents consumption (P group, -12,15% in HRK). Notable are decreases in use of Respiratory system drugs (R group, -5,28% in DDD/1000/day), and Systemic-use anti-infectives (J group, -13,91% in DDD/1000/day).

CONCLUSION: Further research is needed to determine causality between the pandemic emergence and decrease in R and J group DC, as well as consumption of L group, which can somehow be explained by higher drug prices. The P group DC might be decreased by patients taking less outside activities during the year 2020.

O03**Establishment of an ovarian tissue bank in Croatia**Katarina Bilić^a, Marija Vilaj^{b,d}, Davor Ježek^{b,c,d}^a School of Medicine University of Zagreb^b Department of Transfusion Medicine and Transplantation Biology, University Hospital Center Zagreb, Zagreb, Croatia^c Department of Histology and Embryology, Zagreb University School of Medicine, Zagreb, Croatia^d Scientific Center of Excellence for Reproductive and Regenerative Medicine, Zagreb University School of Medicine, Zagreb, CroatiaDOI: <https://doi.org/10.26800/LV-144-supl2-O03>

Katarina Bilić 0000-0003-0061-9156, Marija Vilaj 0000-0003-3877-467X, Davor Ježek 0000-0002-1528-5462

Keywords: cryopreservation, fertility, ovarian tissue bank

INTRODUCTION/OBJECTIVES: Recently, medicine has made significant progress in treating patients with malignant diseases. However, the growing number of cancer-free patients turns the spotlight on their posttherapy treatment and remediation of pharmacological side effects. A new method in overcoming the gonadotoxic effects of chemotherapy and preserving fertility for female patients is ovarian tissue cryopreservation.

MATERIALS AND METHODS: The ovarian tissue banking procedure consists of biopsy retrieval surgery, mostly performed laparoscopically, and tissue cryopreservation. Tissue preservation is the most delicate part of the entire process. It is done by using slow freezing protocols, or alternatively, vitrification. Once patients are done with their therapy and wish to conceive or renew their hormonal cycles, the ovarian tissue fragments are then thawed and reimplanted in orthotopic or heterotopic sites in the patient's body. In 2019, a workshop on ovarian tissue banking was held for the University Hospital Centre Zagreb employees. They were educated about the conditions necessary for establishing an ovarian tissue bank and also received practical training for proper processing and cryopreservation of the tissue.

RESULTS: The employees are adequately trained for the implementation of new techniques. Tissue transport containers were validated, and it was proved that they could retain proper temperature for 17 hours at room temperature conditions (20-25°C), while the optimal temperature for tissue processing was achieved when the cooling elements for the cold plate were cooled at -20°C for 48 hours.

CONCLUSION: Ovarian tissue bank offers a promising new method of preserving fertility in oncology patients and could greatly contribute to Croatian medical care in general.



ABSTRACTS

Workshop Invitations

'See for yourself' – what visual impairment looks like in reality

This interactive workshop is designed in order to raise awareness of how the visually impaired individuals function in everyday activities. How demanding are they really to someone who doesn't have a main sensoric sense which is used more than 85% of the time during the day? The aim of this workshop is to provide some answers about what functional vision is, what are the specific features of functioning of the visually impaired individuals and what visual impairment is all about in reality. Through a set of different activities, participants will be able to try out for themselves what it is like to read using glasses that simulate visual impairment, to write Braille and to orientate with white cane without using their eyesight.



Sveučilište u Zagrebu
Edukacijsko - rehabilitacijski
fakultet



ERF students

AUTHORS

Karolina Đenadija, Anita Jurić,
Valerija Kulić

Dominik Sikirić, MER

Applications of 3D printing in modern medicine

If you are interested in modern technologies you will love our 3D printing in modern medicine workshop as you will experience the world of 3D fabrication first hand and find out all about how can these machines help a living patient, what has been done so far and what could be done in near future. Participants will see a live demo of printing and scanning technologies.



*Student Society for
Medical Innovations*

AUTHORS

Lovro Jančić, Lazarela Cuparić,
Konrad Alexander Kiss, Luka
Zvekić

Prof. Vedran Katavić, MD, PhD

Unmask yourself

Ask yourself: what do you keep saying to yourself when there is no one around? Do you think it is important? Can you assume why it would matter? The answer is right in front of you. You are the only one who is listening every single time. Join us and find out more!



AUTHORS

Lucia Bekić, Mirella Graffel,
Daniel Milošević, Matilda Sabljak

Katarina Skopljak, MD

*CroMSIC – Pogled
u sebe*

ENT practical examination

Examination of the ears and oral cavity is one of the most performed examinations in the medical profession and almost certainly you will have to do it after you get the Diploma. Do you know how to perform it correctly? You can always join our workshop where an ENT specialist will show you what and where to look for. You will be doing otoscopy, rhinoscopy, oral cavity and pharynx exam and laryngoscopy. You will be shown what to look for and the difference between the normal and pathological finding. Be ready for your future job and join the ENT examination workshop!



*Student Society for
Otorhinolaryngology
and Head and Neck
Surgery*

AUTHORS

Jelena Bošnjak, Stela Marković,
Ana Ninčević, Marija Pierobon,
Lovro Tkalčec

Ika Gugić Radojković, MD

Foreign body management

You are on a child's birthday and your friend's child aspirates peanut. Parents are panicking, and everyone is looking at you, do you know what to do? Whatever your answer is, come to our workshop where we will deal with one of the most important and urgent conditions in otorhinolaryngology, i.e. medicine.



*Student Society for
Otorhinolaryngology
and Head and Neck
Surgery*

AUTHORS

Jelena Bošnjak, Stela Marković,
Ana Ninčević, Marija Pierobon,
Lovro Tkalčec,

Borna Miličić, MD

Primary wound care workshop

Dear colleagues!

Student surgical society kindly invites you to the primary wound care workshop. As young doctors we will often come across wounds. But do we really know, how to manage wounds? Do we know, how to make proper history, examination and access to the wound? On our workshop, you will learn which wounds need special surgical attention, which wounds should, and which should not be sutured. What kind of drugs do we use in wound care management and how often do we need to check the wound afterwards. Also, we are going to teach you how to suture and show you how to make some basic, most common used knots in surgery.

Hope to see you there!



*Student Society for
Surgery*

AUTHORS

I. Bobić, B. Vojvodić, A. Pudić,
M. Koporčić, D. Vicković,

Asst. Prof. Prim. Igor Rudež, MD,
PhD

Asst. Prof. Hrvoje Silovski, MD,
PhD

Asst. Prof. Ivan Dobrić, MD, PhD

Neurogames

Join us for our new Neurogames in which you will be able to experience performing lumbar puncture and catheterization of brain arteries by yourself on our models. Aside from practical skills we have also prepared for you some interesting cases and super fun quizzes. We are looking forward to meeting you all.



*Student Society for
Neuroscience*

AUTHORS

Gracia Grabarić, Anton Jakovčić,
Pavel Marković

Goran Sedmak, MD, PhD

ORTHObasics - lower extremities

We cordially invite you to our ORTHObasics - lower extremities workshop where you can learn how to perform the examination of the lower limbs with the guidance of our demonstrators.



*Student Society for
Orthopedics and
Traumatology*

AUTHORS

Afan Ališić, Dinko Ezgeta, Petra
Delimar, Tajana Đurasin, Toni
Demo

Damjan Dimnjaković, MD, PhD

eFAST - Ultrasound for trauma

We invite you to participate in our eFAST ultrasound examination workshop. With a hands-on approach you will learn to choose the right ultrasound probe and basic characteristics of ultrasound image. Then, step-by-step we will go through positioning of the patient and the probe acquiring the right image for each component of the eFAST examination. We will go through different pathological findings in each of the examination parts.



*Student Society for
Radiology*

AUTHORS

Vjekoslav Štambuk

Damir Martinović, MD

StEPP Emergency Medicine Workshop

Dear colleagues,

We invite you to join us at our Emergency Medicine Workshop. As our first workday slowly approaches us, a lot of us are thinking about what our first place of employment will be. A large part of us will start their careers by working in emergency medical services, and by doing so we'll often encounter trauma patients that require urgent treatment. On our workshop, we'll focus on the skills needed to properly assess and treat these patients. You'll be able to learn the algorithm which is used in the initial assessment of a trauma patient. We're also going to teach you how to properly manage a patient's airway, which is the first step in any form of resuscitation.

We look forward to seeing you!

AUTHORS

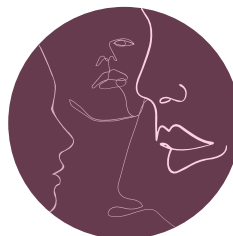Petra Potrebica, Lara Čičak



StEPP

Multidisciplinary approach to oral cancer

Oral cancer is one of the ten deadliest malignant diseases in the world. Due to the non-specificity of symptoms and signs, it is detected at a relatively late stage, when the five-year survival rate is less than 40%. Patients who survive this severe disease often have a very reduced quality of life. In this lecture, we will highlight the role of dentists in the early detection of oral cancer as well as the necessary need for multidisciplinary collaboration between dentists and physicians. Participants will also be able to learn about the crucial role of individual specialists such as general practitioners and psychiatrist in the prevention and treatment of oral cancer. The workshop consists of distinguishing physiologically normal variations of the oral mucosa from possible pathological lesions.



*Student Society for
Oral Medicine*


*School of Dental
Medicine, University
of Zagreb*

AUTHORS


Monika Burja, Bruno Špiljak,
Luka Šimunović

*School of Dental Medicine University
of Zagreb*

CROSS Partners



Donations



Author Index


Ababei A.I.: LR02, LR06, LR07, LR09
 Adamović A.: CR45
 Ajduk J.: CR68
 Alerić M.: CR62
 Ališić A.: CR08
 Bajan M.: CR24
 Bajlo N.: CR39
 Baković D.: CR34
 Bakula M.: CR76
 Balasubramani S.: BS01
 Balog S.: CR10
 Bandić Pavlović D.: CR78
 Banović M.: CR03
 Barišić A.: CR33
 Barišić I.: CR62
 Barišić Kutija M.: CR09
 Batičić L.: BS02
 Bedoić E.: BS02
 Bekić L.: CR18
 Belev B.: CR60
 Belina D.: CR16
 Belošević M.: CR03
 Benčić J.: CR34
 Bilić Ernest.: CR37
 Bilić Ervina.: CR42
 Bilić K.: O03
 Bilić M.: CR26
 Bišof V.: CR19
 Blažević A.: CR01, CR54
 Blažević M.: CR54
 Boban M.: CR47, CR63
 Bodakoš K.: CR10
 Bogdanić J.E.: CR64
 Bošnjak J.: CR67, CR68
 Bradarić-Šlujo B.: CR50
 Brečić P.: CR28
 Brkić L.: CR65, CR69, CR75
 Brnić S.: CR13
 Bruketa T.: CR69
 Bukovac A.: CR50, CR68. O02
 Bukovac L.: CR50
 Buljan G.: CR50, CR68, O02
 Bunjevac I.: CR25
 Bušić I.: CR56
 Cengiz E.: CM03
 Chirilă M.I.: LR01, LR07, LR08, LR09
 Cindrić T.: CM11, CR79
 Cvrtila D.: CR09, CR61
 Čolaković L.: CR30, CR70
 Čorić L.: BS03, BS04, BS05, BS08
 Čubela V.V.: CR23
 Čudina I.: CR06
 Danjek P.: LR05
 Deak A.: CR21
 Deghenghi R.: CR09
 Delalić Đ.: LR04
 Detel D.: BS02
 Dimnjaković D.: CR08
 Divković D.R.: CR72
 Dragaš D.: LR04
 Dretar V.: BS03, BS05, BS08
 Dujmović A.: CR24
 Dušek T.: CM11, CR61
 Đanić Hadžibegović A.: CR67
 Đurašin T.: BS08
 Đureković I.: CR15
 Đurić Vuković K.: CR55
 Edl M.: CR30, CR70
 Edl T.: CR70
 Ehrenfreund T.: CR75

Elveđi Gašparović V.: CR62
 Ersoy B.: CM03
 Ezgeta D.: CR08
 Fojtik Budanko M.: CR67
 Frkanec S.: CM09, CR44
 Frković M.: CR77
 Galjuf V.: CR17, CR59
 Gamulin M.: CR53
 Gangur M.: CR15
 Gašpar S.: O02
 Gatin L.: CR24
 Geber A.: CR17
 Gečević R.: CR15
 Glavaš Weinberger D.: CR15, CR40
 Glavčić M.: CR04, CR06, CR36
 Gomerčić Palčić M.: CM05, CM07
 Graffel M.: CR18
 Grgić M.: CR04, CR06, CR36
 Grgić M.V.: CR50
 Grzelja M.: CR40
 Gržan D.: CR59
 Harak K.: CR04, CR06, CR36
 Herceg D.: CR28
 Herceg S.: CR31
 Homolak J.: BS07
 Horvat A.: CM07
 Horvatić I.: CR45
 Horvatović K.: O01
 Jalšovec D.: CR25
 Jelić Matej: CR47
 Jelić Mislav: CM08, CM10
 Jerkić L.: CR25, CR26, CR32
 Ježek D.: O03
 Joja M.: BS07
 Josipović M.: CM08, CM10
 Jupek N.: CR25, CR26
 Jureković Ž.: CR74
 Juri Mandić J.: CR48
 Jurić Ilija: CM09
 Jurić Ivana.: CR41
 Jurin I.: CR56
 Kajan J.: LR04
 Kalajžić L.: CR49, CR58
 Kalauz M.: CM02, CR09
 Kalogjera L.: BS03, BS04, BS05
 Karakaš T.: CR49, CR58
 Kaštelan Ž.: CM09
 Kinda E.: CR65
 Klepač L.: BS03
 Knez N.: CR46, CR53
 Knežević J.: CM02
 Knežević S.: CR05, CR58
 Kokot A.: CR10
 Konjevoda S.: CR51
 Kopušar M.: CR05, CR49, CR58
 Kostić A.: CR24
 Kostić M.: CR24
 Košucu M.A.: CM03
 Košec A.: CM04, CR17, CR44, CR52
 Kovač Bilić L.: CR02, CR34
 Kovač L.: CR39
 Kovačević M.: CR77
 Kovačević P.: CR48, CR51, O01
 Kraljević J.: CR79
 Kruezi E.: CR01
 Krželj K.: CR16
 Kučina L.: CR05
 Kujundžić M.: CR77
 Kuliš T.: CM09
 Kuštra N.: CR57
 Kuzman K.: CR65
 Kuzman T.: CR09, CR71
 Kvolik A.: CR72
 Lažeta L.: CR18
 Ledenko R.: CR57
 Likić R.: CR13

Lipan I.: LR01, LR08
Lončarić K.: CR32
Lovrić Benčić M.: CR11
Lovrić F.: CR51, O01
Lovrić M.: CR48, CR51, O01
Lučev L.: CR02
Lukšić I.: CR15
Lukšić M.: CR48
Luscombe V.: BS06
Lužaić K.: CR69
Ljubičić Đ.: CR73
Malbašić A.: CR50, CR68, O02
Malić M.: CR38
Mandac Smoljanović I.: CR40
Marković S.: CM04, CR19, CR38
Masnec S.: CM02, CR09
Mataković Trivunčević M.: CM11
Matić S.: CR70
Matijašević L.: CR62, CR75
Matijević A.: CR12
Matijević V.: CR12
Matolić G.: CR12
Matošević P.: CR65
Međimurec G.: CR16
Mehta P.: BS01
Meštrović D.: CR23, CR42
Mihaljević L.: CR23, CR42
Mikulić D.: CR12
Mileta D.: LR04
Miličević O.: CR62, CR75
Mrvelj B.: CR71
Mrzljak A.: CR46, CR74
Muchová L.: BS01
Muršić I.: CR35
Negovetić P.: CR22
Nekić A.: CR02
Ninčević A.: CM02
Nizić D.: CM08
Novak N.: CR46, CR53, CR66
Oroz K.: BS03, BS04, BS05, BS08
Oryshchenko V.: CR27
Ostojić Kolonić S.: CR21
Padjen I.: CR57
Palac L.: BS04
Palčić L.: CR16
Pappo N.: CR03, CR16
Parać E.: CR22, CR28
Pastorčić M.: CR78
Pašić H.: CM11, CR79
Pečnik M.: BS04, BS05, BS08
Pećin I.: CR59
Pešorda L.: LR03
Petani A.: CR05
Petrinović M.: CR23, CR42
Pinotić K.: CR43
Pinotić S.: CR43
Pinotić Z.: CR43
Pleško E.: LR03
Polanco Armenta C.A.: CM01
Poldan Skorup K.: CR58
Pospišil M.: LR03
Pourmodjib K.: CR37
Pravica N.B.: CR29
Preložiček D.: CR23, CR42
Premužić Meštrović I.: CR07
Prepolec I.: CR64
Prkačin I.: CR66
Prnjak J.: CR52
Pudić M.: CR55
Pulanić D.: CR46
Pušeljić N.: CR35, CR41
Pušeljić S.: CR41
Putrić Posavec J.: CR64
Racetin A.: CR60
Rako N.: CM11, CR79
Rogga V.: BS06

Roglić G.: CR07
 Rosan T.: CR46, CR53, CR66
 Rudež I.: CM06
 Russell A.: BS06
 Sabalić S.: CR49
 Sabljak M.: CR33
 Şahintürk D.K.: CM03
 Saić H.: CM09
 Samardžić N.: CR48
 Samoilenko A.: CR27
 Santini M.: CR29
 Şenödeyici E.: CM03
 Serdar J.: CM08
 Severin M.: CR11
 Sirovica M.: CR11
 Skopljak K.: CR18
 Smajić M.: CR35, CR41
 Smajić P.: CR35
 Smiljanić Tomičević Lj.: CR22
 Smoday I.M.: BS03, BS04, BS05, BS08
 Sobočan N.: CR20
 Soldo D.: CR63
 Soyluoğlu F.S.: CM03
 Stevanović S.: CR17
 Stipetić T.: CM11
 Stojić V.: CR44
 Strelchenia O.: CR27
 Strelchenia T.: CR27
 Šalek Z.: CR37
 Šalković-Petrišić M.: BS07
 Šelović M.: CR76
 Šimunović M.: CM08
 Škegro I.: CR09
 Šklebar T.: CR22
 Škornjak H.: CR73
 Šprem Goldštajn M.: CR14
 Štrbac T.: CR44
 Tanasa A.D.: LR01, LR02, LR06, LR08
 Tarle M.: CR15
 Tarnovski L.: CM06
 Terzić P.: CR74
 Tiku A.: CR74
 Tkalec K.: CR74
 Tolić G.: CM11
 Trkulja I.: CR65
 Udovičić M.: CR29
 Ursachi R.C.: LR01, LR07
 Varljen J.: BS02
 Velagić V.: CR64
 Vidović L.: CR14
 Vilaj M.: O03
 Virović Jukić L.: CR31
 Vlachopoulou D.: BS01
 Vlaić J.: CM08, CM10
 Vrančić M.: CR25
 Vraneš H.: BS03, BS04, BS05, BS08
 Vučić D.: CR51
 Vukojević M.: CR01, CR54
 Vukojević N.: CR54
 Vuković A.: CR01
 Vusić L.: CM05
 Wang P.: BS06
 Yildirim G.: CM03
 Zekulić T.: CM09
 Zibar L.: CR30, CR35
 Žitinić I.: CR05
 Živko J.: CM04, CR19, CR38
 Živko M.: CR20

Notes





cross.mef.hr